

Open reduction and internal fixation of mandibular subcondylar fractures with quadrangular plate -A Case Report

P. Pravahitha* and M. R. Mutushekar

Department of Oral and Maxillofacial Surgery, Saveetha Dental College, Saveetha University, Chennai, India

QR Code



*Correspondence Info:

Dr. P. Pravahitha
Postgraduate Student
Department of Oral and Maxillofacial Surgery,
Saveetha Dental College, Saveetha University,
162, Ponamallee high road, Chennai 600077 Tamil nadu, India

*Article History:

Received: 08/03/2018

Revised: 06/04/2018

Accepted: 06/04/2018

DOI: <https://doi.org/10.7439/ijpr.v8i5.4685>

Abstract

Mandibular condylar fractures are the most commonly encountered mandibular fractures, being 17.5–52% of all mandibular fractures. The most common unilateral fracture is subcondylar, and the most common bilateral fracture is of the condylar heads, mostly caused by direct trauma, but may also be due to indirect forces. Treatment of condylar fractures depends on physical and imaging evidence of the fracture, extent of injury (whether unilateral or bilateral), the level of fracture, the degree of displacement and dislocation, the size and position of the fractured condylar segment, and the dental malocclusion.

Keywords: Sub condylar fracture, Quadrangular plating system, Open reduction and internal fixation, Mandibular fractures.

1. Introduction

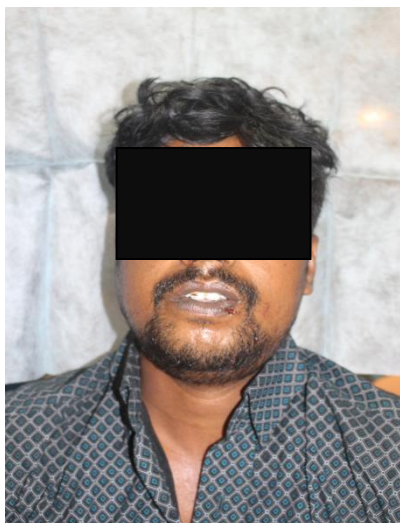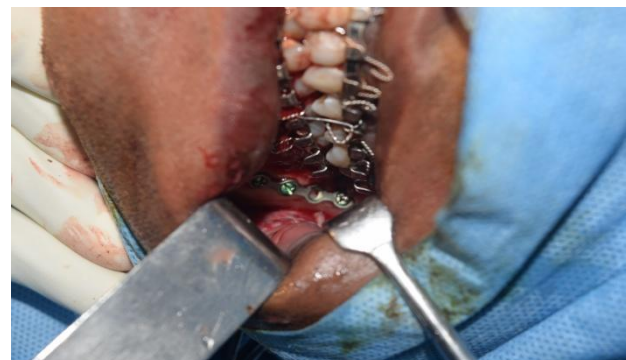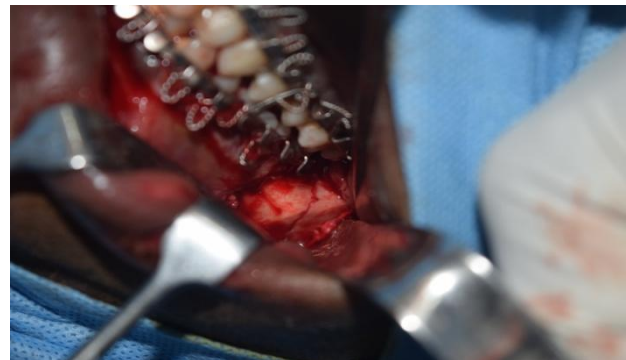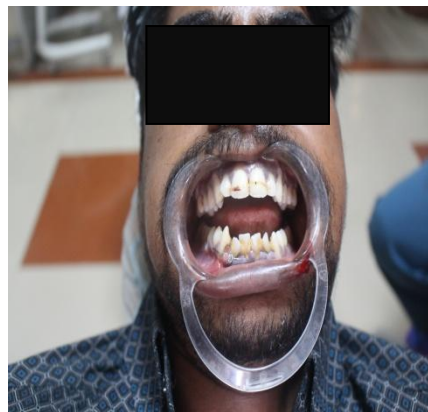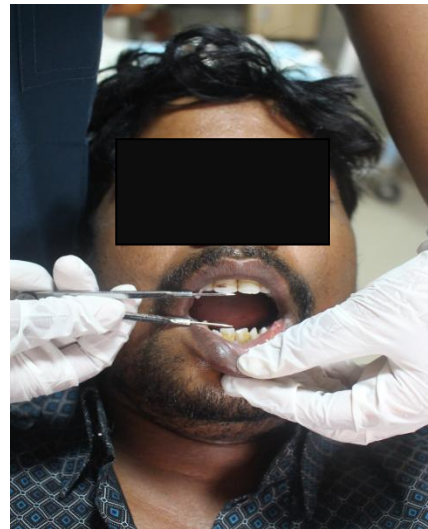In 1924, Perthes carried out the first surgical treatment of a condylar fracture. Surgical treatment has been advocated to reapproximate the fractured segments and to avoid complications like open bite, retrognathia, pain, reduced lateral or protrusive mobility, and deviation on opening.[6,7] Open reduction aims at anatomical repositioning and rigid fixation of the fragments, occlusal stability, rapid return to function, maintenance of vertical ramus dimension, no airway compromise, and less long-term temporomandibular joint dysfunction.[8,9]

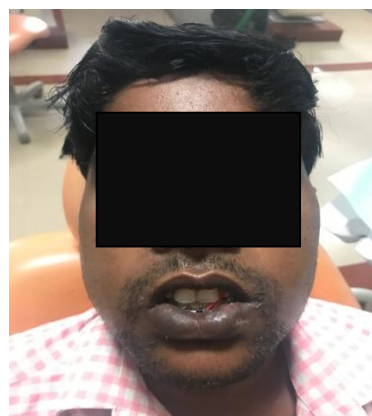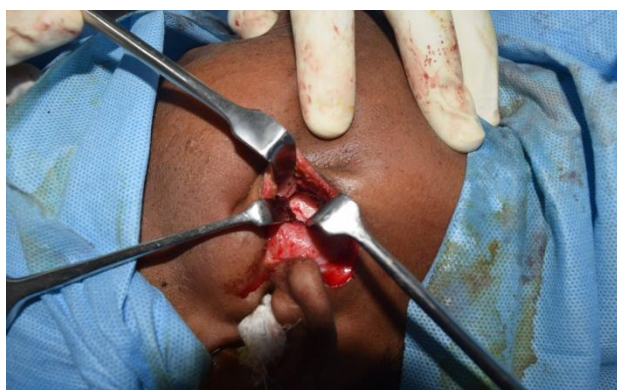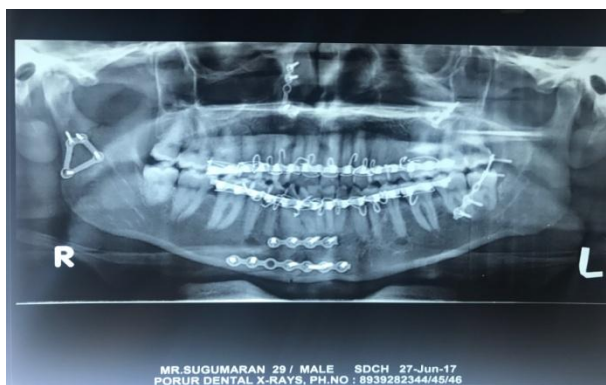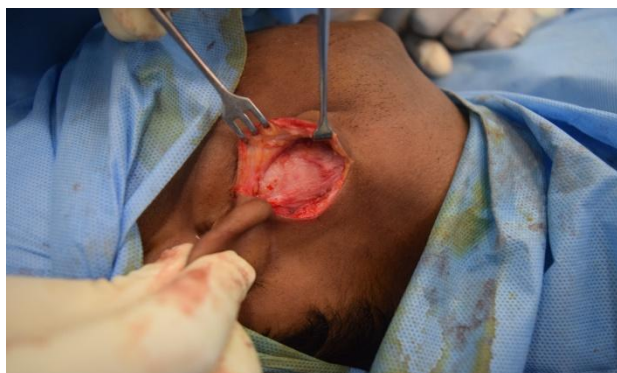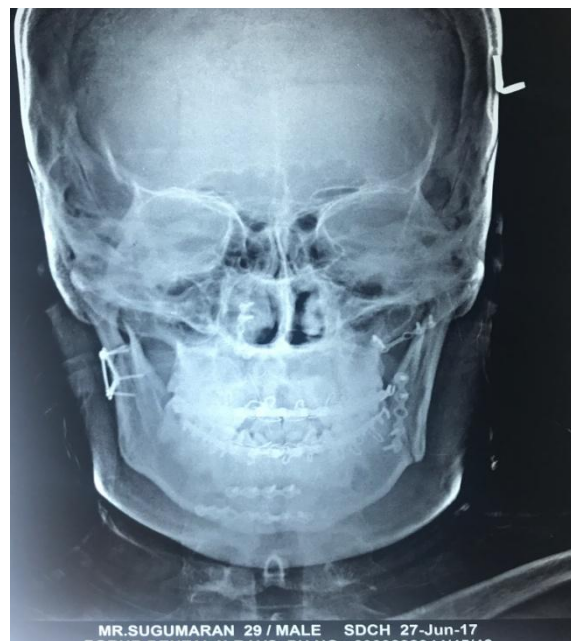
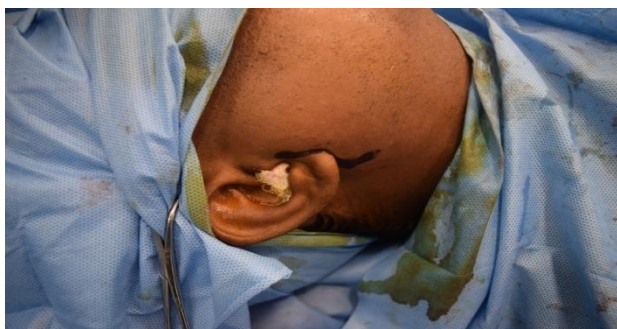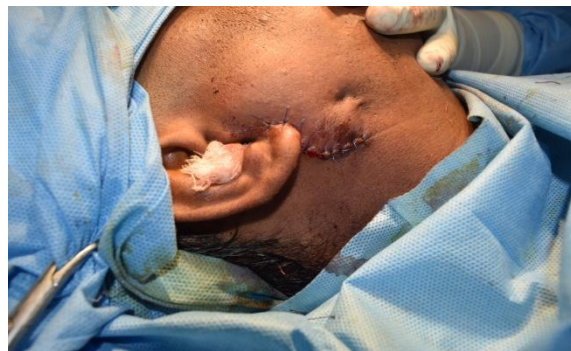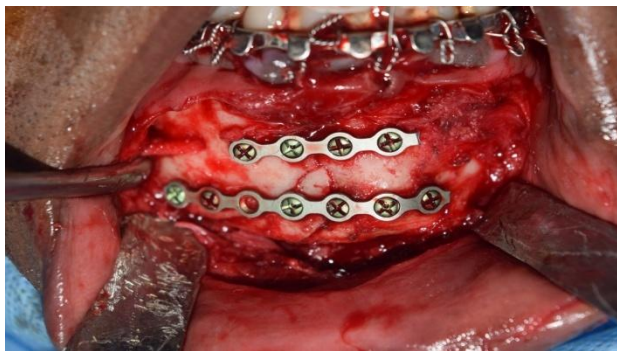
Bilateral condylar fractures cause most malocclusions.[10] It is believed that once condylar nonunion has occurred, conservative treatment is ineffective and joint is prone to arthritic sequelae. [11] Open reduction and internal fixation of condylar fractures is an acceptable method, as it prevents the complications associated with closed reduction like shortening of ramus, deviation of jaw on opening, occlusal discrepancies, formation of false joint, which functions for condylar movement in glenoid fossa, and late-term complications.

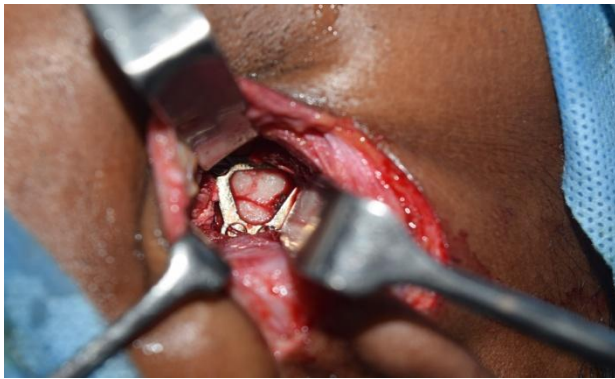Stable fixation is very important as the interfragmentary mobility can lead to nonunion, fibrous union, or temporomandibular disorders. Fixation with very rigid miniplates provides more stability than transosseous wiring.[12,13] Although single miniplates can be adequate if the fragments are aligned properly, functional forces actually exceed the rigidity of one miniplate, and therefore the use of two has been proposed.[14,15] However, in the condylar neck, the amount of bone is not always adequate to permit placement of 2–3 screws per fragment. To overcome this problem, various plate designs have been put forward. Quadrangular condylar plate is such a 3-D plate shaped for adaptation in the anatomically constricted region of condylar neck. quadrangular plate is placed with one arm parallel to the condylar axis and second arm parallel to the mandibular notch. Hence, this plate meets the criteria of 2 single miniplates with reduced hardware, leading to a less infection rate.[16] This case report evaluates the efficacy of single quadrangular 3-D miniplates in subcondylar fractures.

2. Case report

A 29 year old male reported to the department of oral and maxillofacial surgery with the chief complaint of pain in the right lower jaw region as he alleges a fall from the first floor. Extra oral examination reveals subconjunctival haemorrhage, depression over the left infra temporal region. Tenderness over right parasymphysis, right TMJ and left angle. Intra oral examination revealed a step deformity between 32-33 and left angle region. CT scan was taken. Diagnosis of pan facial trauma was made. There was fracture of right subcondylar, right parasymphysis, right nasomaxillary buttress, left angle, left zygomaticomaxillary buttress. Open reduction and Internal fixation was planned. Under general anaesthesia circumvestibular incision was placed from 32-43 region. Full thickness mucoperiosteal flap was reflected exposing the fracture site. Wards incision was placed on the left angle. Full thickness flap was reflected exposing the fracture site. Fracture reduction done. IMF done and left angle plated with 2mm 5 hole plate and secured with 2x8mm(4nos) titanium screws and parasymphysis was plated with 2mm 7 hole plate and 2mm 4 hole plate secured with 2x8mm(6nos) in the lower plate and 2x8mm(1nos) and 2x6mm(3nos) in the upper plate. Pre auricular incision placed blunt dissection done to expose fracture site. IMF released. Fracture reduction done and plated with 1.5mm quadrangular plate and secured with 1.5x8mm (4nos). Closure was achieved in layers with vicryl 3-0 and skin closure achieved with 5-0 ethilon. Circumvestibular incision paced in the upper vestibule from 16-26 region. Full thickness mucoperiosteal flap was raised to expose the fracture site. Fracture reduction done and plated with 1.5mm 5 hole plate on both the sides and secured with 1.5x6mm (4nos) on both the sides. Saline irrigation done and closure achieved intraorally with 3-0 vicryl. Extubation uneventful







3. Discussion

Closed reduction has been associated with shortening of ramus, deviation of jaw on opening, occlusal discrepancies, formation of false joint, and late complications, leading to internal derangement of the joint. Today, open reduction and internal fixation of condylar fractures is the acceptable method in the management of condylar fracture, especially in cases with gross displacement of condylar fragment, major reduction in posterior facial height, and deranged occlusion.

The principle behind open reduction and internal fixation using miniplate osteosynthesis is “functionally stable osteosynthesis”. [17,18] Champy determined the ideal line of osteosynthesis in the region of mandibular body, but no such line was proposed in the region of condyle because of limited data. Meyer [19] attempted to fill this void to determine the ideal line of osteosynthesis in the region of condyle. When biting forces are applied in the region of molars, strain lines were detected in the condylar region. Hence, adaptation of single 4-hole miniplate, as was initially proposed, did not provide dynamic osteosynthesis and resulted in fracture of the plate during function. Two manipulate fixation (a miniplate parallel to axis of condyle and second miniplate parallel to notch of the mandible) met with the fulfillment of dynamic osteosynthesis, but adaptation of 2 miniplates in the region of condylar axis is difficult due to the constriction of condylar neck. Hence, use of Quadrangular plate has been proposed in open reduction and internal fixation of the condylar fractures.

Quadrangular plate is shaped for adaptation in the anatomically constricted region of condylar neck. Quadrangular plate is placed with one arm parallel to the condylar axis and second arm parallel to the mandibular notch. Hence, this plate met the criteria of 2 single miniplates, but with a reduced hardware. This plate provides three-dimensional stability because of its design. Infection rate is less because of the reduced hardware and requires reduced exposure as compared to 2–4 hole straight miniplate.

Titanium 3-D plating system was developed by Farmand [20] to meet the requirements of semirigid fixation with lesser complications. The 3-D plate is a misnomer as the plates are not three-dimensional but hold the fracture fragments rigidly by resisting the forces in three dimensions namely shearing, bending, and torsional forces. The point of 3-D fixation [20] is that a quadrangular plate with bone screws creates three dimensional stability. The stability is gained over a defined surface area and is achieved by its configuration and not by thickness or length, and also the large free areas between the plate arms and minimal dissection permit blood supply to the bone.

The reason for hardware failure in the two mini plate system is the plate is located on the compression strain lines when placed conventionally along the condylar neck and goes completely against the principles of functionally stable osteosynthesis. Quadrangular plate is placed with one arm parallel to the condylar axis and second arm parallel to the mandibular notch, thus providing stable osteosynthesis and minimizing the rate of hardware failure.

4. Conclusion

Patients with gross displacement of condylar fragment, major reduction in posterior facial height, and deranged occlusion can be successfully managed by open reduction of condylar fracture and its fixation using 3-D plates.

Conflict of interest: The authors have no conflict of interest

Ethical approval

All procedures performed in studies involving human participants were in accordance with the ethical standards of the institutional and/or national research committee and with the 1964 Helsinki declaration and its later amendments or comparable ethical standards.

References

- [1]. Zachariades N., Papavassiliou D., Papademetriou J., Koundouris J. Fractures of the facial skeleton in Greece. *J Maxillofac Surg.* 1983; 11:142–144.
- [2]. Bochlogyros P.N. A retrospective study of 1,251 mandibular fractures. *J Oral Maxillofac Surg.* 1985; 43:597–599.
- [3]. Zachariades N., Papavassiliou D. The pattern and aetiology of maxillofacial injuries in Greece. *J Cranio-Maxillofac Surg.* 1990; 18:251–254.
- [4]. Silvennoinen U., Iizuka T., Lindqvist C., Oikarinen K. Different patterns of condylar fractures: an analysis of 382 patients in a 3-year period. *J Oral Maxillofac Surg.* 1992; 50:1032–1037.
- [5]. Killey H.C. Wright & Sons; Bristol: 1974. Fractures of the Mandible.

- [6]. Jeter T.S., Van Sickle J.E., Nishioka G.J. Intraoral open reduction with rigid internal fixation of mandibular subcondylar fractures. *J Oral Maxillofac Surg.* 1988; 46:1113–1116.
- [7]. Lachner J., Clanton J.T., Waite P.D. Open reduction and internal rigid fixation of subcondylar fractures via an intraoral approach. *Oral Surg.* 1991; 71:257–261.
- [8]. Zhang X., Obeid G. A comparative study of the treatment of unilateral fractured and dislocated mandibular condyle in the rabbit. *J Oral Maxillofac Surg.* 1991; 49:1181–1190.
- [9]. Ellis E., III, Simon P., Throckmorton G.S. Occlusal results after open and closed treatment of fracture of the mandibular condylar process. *J Oral Maxillofac Surg.* 2000; 58:260–268.
- [10]. Lindahl L. Condylar fractures of the mandible. *Int J Oral Surg.* 1977; 6:12–21.
- [11]. Pereira M.D., Marques A., Ishizuka M., Keira S.M., Brenda E., Wolosker A.B. Surgical treatment of the fractured and dislocated condylar process of the mandible. *J Craniomaxillofac Surg.* 1995; 23: 369–376.
- [12]. Iizuka T., Lindqvist C., Hallikainen D., Mikkonen P., Pauku P. Severe bone resorption and osteoarthritis after miniplate fixation of high condylar fractures. *Oral Surg.* 1991; 72:400–407.
- [13]. Zachariades N., Papademetriou J., Rallis G. Mandibular fractures treated by bone plating and intraosseous wiring. A comparative study. *Rev Stomatol Chir Maxillofac.* 1994; 95:386–390.
- [14]. Hammer B., Schier P., Prein J. Osteosynthesis for condylar neck fractures: a review of 30 patients. *Br J Oral Maxillofac Surg.* 1977; 35:288–291.
- [15]. Choi B.H., Yi C.K., Yoo J.H. Clinical evaluation of 3 types of plate osteosynthesis for fixation of condylar neck fractures. *J Oral Maxillofac Surg.* 2001; 59:734–737.
- [16]. Meyer C., Martin E., Kahn J.L., Zink S. Development and biomechanical testing of a new osteosynthesis plate (TCP®) designed to stabilize mandibular condylar fractures. *J Craniomaxillofac Surg.* 2007; 35:84–90.
- [17]. Champy M., Wilk A., Schnebelen J.M. Treatment of mandibular fractures by means of osteosynthesis without intermaxillary immobilization according to F.X. Michelet's technic. *Zahn Mund Kieferheilkd Zentralbl.* 1975; 63:339–341.
- [18]. Champy M., Lodde J.P. Syntheses mandibulaires: localisation des syntheses en fonction des contraintes mandibulaires. *Rev Stomatol.* 1976;77:971–976.
- [19]. Meyer C., Kahn J.L., Boutemi P., Wilk A. Photoelastic analysis of bone deformation in the region of the mandibular condyle during mastication. *J Craniomaxillofac Surg.* 2002; 30:160–169.
- [20]. Farmand M. Three dimensional plate fixation of fractures and osteotomies. *Fac Plast Surg Clin North Am.* 1995; 3(1): 39–56.