

## CRYOTHERAPY IN CERVICAL INTRAEPITHELIAL NEOPLASIA

Naina Kumar\*

Mahatma Gandhi Institute of Medical Sciences, Sevagram India

Corresponding author\*: [drnamitsingh@hotmail.com](mailto:drnamitsingh@hotmail.com)**Abstracts**

Cryotherapy is a time proven ablative method of treating lower grades of cervical dysplasia. It is done using compressed CO<sub>2</sub> or N<sub>2</sub>O refrigerant with the aim of creating an ice ball with a depth of freeze denoted by a peripheral margin of 4-5 mm of frost. It is performed using a double freeze or single freeze technique. Currently the double freeze technique of cryotherapy is an accepted treatment for mild and focal moderate dysplasia of the uterine cervix. The success of cryotherapy is determined by five factors: patient anatomy, pathology, equipment, and technique and physician skill. Here we have a brief review of cryotherapy as an effective modality in treatment of lower grades of cervical intraepithelial neoplasias.

**Keywords:** Cryotherapy, neoplasias, cervical

**1. Introduction**

Cervical intraepithelial neoplasia (CIN) refers to pre-invasive dysplasia of cervical epithelial cells, the precursor of malignant disease. CIN is categorized according to the depth of involvement and the atypicality of the cell. CIN1 is not considered a cervical cancer precursor and is usually caused by low risk HPV types. Unless persistent for more than two years, and diagnosed in women over age 21, treatment is not recommended. Rates of regression for low grade lesions are as high as 75 percent at five years for adults<sup>1</sup> and up to 91 percent at three years in adolescents<sup>2</sup>. The high grade dysplasia lesions, CIN2 and CIN3, are considered true precancers. Even so, up to 40 percent of CIN2 may regress spontaneously, especially in younger women<sup>3</sup>. The slow malignant transformation of these lesions leads to a long latency period for cervical cancer. The major cause of CIN is chronic infection of the cervix with the sexually transmitted human papillomavirus (HPV), especially the high-risk HPV types 16 or 18. CIN is usually discovered by a screening test, the Papanicolaou or "Pap" smear. An abnormal Pap smear result may lead to a recommendation for colposcopy of the cervix. A biopsy is taken of any abnormal appearing areas.

Depending on several factors such as the type of HPV and the location of the infection, CIN can start in any of the three stage, and can either progress, or regress<sup>4</sup>. CIN is classified in grades:

1. CIN I or LSIL: Dysplasia confined to the basal 1/3 of the epithelium. This corresponds

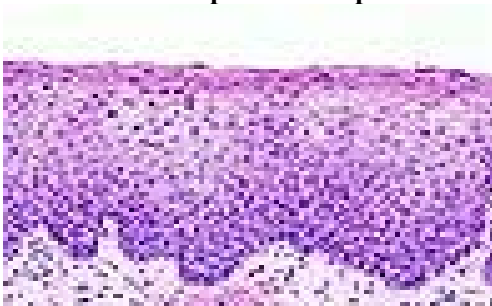
to infection with HPV, and typically will be cleared by immune response in a year or so, though can take several years to clear.

**Figure 1: Showing slide of Cervical intraepithelial neoplasia I.**



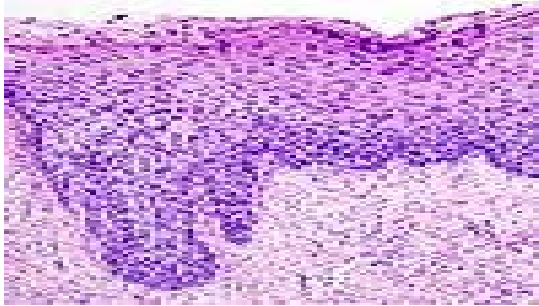
2. CIN II or HSIL: Moderate dysplasia confined to the basal 2/3 of the epithelium.

**Figure 2: Showing slide of Cervical intraepithelial neoplasia II.**



3. CIN III or HSIL: Severe dysplasia that spans more than 2/3 of the epithelium, and may involve the full thickness. This lesion may sometimes also be referred to as cervical carcinoma in situ.

**Figure 3: Showing slide with cervical intraepithelial neoplasia III**



**1.2 Incidence:** In India the incidence of CIN is very high, a large number of patients are missed because of inadequate screening facilities. Women can develop CIN at any age, however, women generally develop it between the ages of 25 to 35.<sup>4</sup> Glandular abnormalities are found in approximately 0.1 to 2.1 percent of cervical cytology samples<sup>5</sup>. Atypical glandular cells (AGC) are found most commonly in women age 40 or older. This was in contrast with abnormal squamous cytologic findings (atypical squamous cells or a squamous intraepithelial lesion), which were most common in women ages 15 to 29.

The distribution of histology and anatomic site was illustrated in two literature reviews that included approximately 4300 women with AGC or atypical glandular cells of undetermined significance [AGUS], evaluated using the pre-2001 Bethesda classification, findings were benign in 64 to 71% of women; abnormalities included<sup>6,7</sup>:

Squamous cervical intraepithelial neoplasia – 20 to 28%, comprised of:

- Low grade cervical intraepithelial neoplasia (CIN 1) – 9%
- High grade cervical intraepithelial neoplasia (CIN 2,3) – 11%
- Squamous cervical carcinoma – 1%
- Cervical adenocarcinoma in situ – 3 to 4%
- Cervical adenocarcinoma – 2%
- Endometrial hyperplasia – 1%
- Endometrial adenocarcinoma – 2 to 3%

**1.3 Risk factors:** Some risk factors that have been found to be important in developing CIN are:

- Infection by a "high risk" types of HPV, such as 16, 18, 31, or 45
- Multiple sexual partners
- Smoking
- Immunodeficiency
- Women who give birth before age 17

**1.4 Progression and regression:** It used to be thought that cases of CIN progressed through these stages toward cancer in a linear fashion<sup>8</sup>.

However most CIN spontaneously regress. Left untreated, about 70% of CIN-1 will regress within two years, and 90% within two years<sup>9</sup>. About 50% of CIN 2 will regress within 2 years without treatment. Progression to cancer typically takes 15 (3 to 40) years. Also, evidence suggests that cancer can occur without first detectably progressing through these stages and that a high grade intraepithelial neoplasia can occur without first existing as a lower grade<sup>4</sup>.

**1.5 Guidelines for 2006 consensus the management of women with CIN<sup>10</sup>:** The histological classification incorporated into these guidelines is a two – tiered system that applies the terms CIN 1 to low-grade lesions and CIN 2,3 to high- grade precursors.

## 2. Treatment methods

**2.1 General comments:** Both ablative treatment methods that destroy the affected cervical tissue in vivo and excisional modalities that remove the affected tissue are utilized for treating CIN Lesions. Ablative methods include cryotherapy, laser ablation, electrofulguration and cold coagulation. Excisional methods include cold-knife conization, Loop electrosurgical excision procedures (LEEP or LLETZ), laser conization and electrosurgical needle conization

**2.2 Recommended management of women with CIN 1:** The recommended management of women with a histological diagnosis of CIN 1 preceded by an ASC-US, ASC-H or LSIL cytology is follow up with either HPV DNA testing every 12 months or repeat cervical cytology every 6 to 12 months. If the HPV test is positive or if repeat cytology is reported as ASC-US/ greater, colposcopy is recommended. If the HPV test is negative or two consecutive repeat cytology tests are “negative for intra epithelial lesion/malignancy”, return to routine cytological screening is recommended.

If the CIN1 persists for at least 2 years, either continued follow-up or treatment is acceptable. If treatment is selected and the colposcopic examination is satisfactory, either ablation or excision is acceptable.

**2.3 Recommended management of women with CIN 2,3:** Both ablation and excision are acceptable treatment modalities for women with a histological diagnosis of CIN 2,3 and satisfactory colposcopy, except in special circumstances.

**2.4 Post treatment follow-up:** The treatment failure rate for CIN using either ablative or excisional methods has varied between 1% and

25%<sup>11</sup>. Most failures occur within two years after treatment.

A number of follow-up protocols have been recommended, these include cytology, colposcopy, combination of cytology and colposcopy, and HPV DNA testing.

### 3. Cryotherapy

Cryotherapy is a time proven ablative method of treating lower grades of cervical dysplasia. The word Cryo is derived from the Greek word "Kryos" which means icy cold. Cryotherapy is the therapeutic use of cold. Cold has been used for medical purposes since as early as 2500 B.C. when Egyptians first used cold compressors for infected wounds and fractures. Hippocrates has also reported its indication for control of haemorrhage and oedema. Anaesthetic properties of cold were recognised by the 11<sup>th</sup> century and Arnott first used cold in 1845 for the treatment of cancer. Since then, cryosurgery has been used with success in many fields of medicine ranging from cataract to prostatectomy and neurosurgery<sup>12</sup>. The era of Cryosurgery in Gynaecology started about 100 years back, when in 1883 Openchowski circulated cold saline water through the vagina of a woman with large pelvic tumor in whom the reduction in the size of the mass was noted. Since then it has been used for the treatment of various genital organ diseases, benign as well as malignant, with success.

From these minor beginnings, this spanned a period of 20 years; Gynaecology Cryosurgery attracted a sustained interest following the pioneering efforts of I.S Cooper, a neuro surgeon. In cooperation with industry, Cooper developed precise instrumentation, which made the use of cold a therapeutic reality. The first report on outpatient use of Cryosurgery was from D.E Townsend in 1968, which emphasized the safety, simplicity and cost saving aspects of the technique<sup>13</sup>. Since this time, the outpatient cryosurgery has been used to treat thousands of women with chronic or premalignant cervical diseases. So that now it is an accepted alternative in the management of many cases.

In Gynaecology it is employed increasingly for the benign lesions of the lower genital tract. Cryosurgery is also used for the condylomatous lesions of vulva, vagina and also the endometrial hyperplasia, but the principle use of cryotherapy is to the cervix itself. As chronic erosions and ectropion are amongst the commonest gynaecological lesions accounting for 80-90% of patients attending Gynae O.P.D. Cryosurgery is

relatively painfree and provides an ideal means of treating these common lesions in the conscious patient.

Cryotherapy is done using compressed CO<sub>2</sub> or N<sub>2</sub>O refrigerant with the aim of creating an ice ball with a depth of freeze denoted by a peripheral margin of 4-5 mm of frost. The hypothermia produced by the ice ball results in crystal formation within cervical tissue, leading to tissue destruction. If an excellent contact between the cryoprobe tip and the ectocervix is achieved, N<sub>2</sub>O-based cryotherapy will achieve -89 degree C and CO<sub>2</sub>-based system will achieve -68 degree C at the core of the ice ball and temperatures around -20 degree C at the edges. Cells reduced to -20 degree C for one or more minutes will undergo cryonecrosis.

Cryotherapy is performed using a double freeze or single freeze technique. The double freeze technique involves applying coolant continuously for a 3-min freeze, followed immediately by a 5-min thaw, followed by another 3-min freeze. The single technique consists of continuously freezing for 5-min. Currently the double freeze technique of cryotherapy is an accepted treatment for mild and focal moderate dysplasia of the uterine cervix<sup>14</sup>.

The success of cryotherapy is determined by five factors : patient anatomy, pathology, equipment, technique and physician skill. The location of the lesion, vascular supply and the potential crypt involvement include anatomical variability. The lesion size and severity of disease determine pathologic factors.

For cryotherapy to be effective – entire squamocolumnar junction must be visualized, women with unsatisfactory colposcopy should not be treated with cryotherapy. Also for better results with cryotherapy entire lesion should be visualized and should not go into canal more than 5mm. A minimal lateral spread of freeze of 7mm as 2mm recovery zone and 5mm lethal zone is clinically necessary for satisfactory treatment of CIN<sup>15</sup>. Various studies have demonstrated that endocervical crypt ( gland ) involvement of cervical intraepithelial neoplasia (CIN) may penetrate upto 3.8mm into the cervix. A freeze that causes cell death to 4mm should effectively eradicate 99.7% of lesions with gland involvement. Current recommendations are to produce an ice ball with a 5mm lateral spread to accomplish this go<sup>16</sup>.

The most favoured ablative technique for CIN is cryocoagulation. Small sized cervical intraepithelial neoplasias (<2.5 cm<sup>2</sup>) respond

favourably to cryocoagulation but larger lesions (>2.5 cm<sup>2</sup>) have a higher failure rate<sup>17</sup>.

The Alliance for Cervical Cancer Prevention (ACCP) conducted a systematic review of the literature on the use of cryotherapy as an out-patient treatment option for women with cervical intraepithelial neoplasia (CIN)—the precursor to cervical cancer and concluded that Cryotherapy produced an overall cure rate of 89.5 percent. The data suggested that, overall; cryotherapy is as effective as other out-patient treatment methods. Cryotherapy resulted in higher cure rates for less severe lesions (CIN 1 and CIN 2), more severe lesions (CIN 3), especially larger lesions extending into the endocervical canal, have lower cure rates<sup>18</sup>.

2001 Consensus Guidelines, support the use of cryotherapy as an acceptable method of treatment of CIN1 and CIN 2 / CIN 3 provided that an appropriate follow-up is conducted.

**3.1 Cryotherapy Equipment:** The cryotherapy unit consists of a compressed gas cylinder (20 lb tank) either of carbon dioxide or nitrous oxide, a yoke with a lightening knob and an inlet of gas to connect the gas cylinder to the cryotherapy gun through a flexible gas conveying tube, a pressure gauge, showing the cylinder gas pressure, an outlet silencer, a cryotherapy gun with handle grip, a gas trigger to allow the gas to be released to the cryotherapy probe at high pressure and the cryotherapy probe.

**3.2 Indications:** Only indicated for the treatment of biopsy-proven squamous dysplasia after an adequate colposcopic examination. Often reserved for CIN 1 and 2 level lesions. There may be a higher recurrence rate compared to LEEP for CIN 3 level lesions, possibly due to the greater depth of glandular involvement with CIN 3.

### 3.3 Contraindications:

- Lesions extending into the endocervical canal.
- Cervical cryotherapy should be avoided in pregnancy.
- Large lesions that cannot be covered with the cryoprobe.
- Active cervicitis
- CIS, or Invasive lesions.
- Adenocarcinoma-*in-situ*.

**3.4 Procedure:** Informed consent is obtained listing risks and benefits. The patient is placed in the dorsal lithotomy position and a self retaining speculum is inserted. A probe that adequately covers the entire lesion and the entire Transformation zone is selected and a water soluble lubricant is applied to the probe which

acts as a thermocouple with the irregular surface of the cervix. The probe is then firmly applied to the cervix making sure that it doesn't touches the side walls of the vagina. The freezing is started by pulling the trigger (green gun) or pressing the freeze button (black gun). Within a few seconds the probe will freeze to the cervix. When a rim of ice forms and grows to a width of at least 5mm in all quadrant, discontinue freezing. Wait until the probe visibly defrosts to disengage it. The cervix should be allowed to regain its pink colour (usually over about 5 minutes). Repeat the freeze sequences as above.

### 3.5 Advantages:

- Serious injuries or complications are rare.
- It is quick and easy to learn and to perform.
- It can be done easily in the outpatient setting with relatively simple and inexpensive equipment.
- No anesthesia required.
- It can be performed in a short time and does not interfere with daily activities.
- There is minimal chance of heavy bleeding during or after the procedure.
- It is the least expensive widely available form of treatment for CIN.
- There is apparently little or no effect on fertility or labor.

### 3.6 Disadvantages:

- Heavy discharge for several weeks after cryotherapy.
- Uterine cramps.
- Bleeding and infection are rare problems during the reparative period.
- Cervical stenosis.
- Unlike excision therapies, there can be no histologic examination of the entire lesion.
- Future Pap smears and colposcopy may be more difficult after cryotherapy. The squamocolumnar junction has a tendency to migrate deeper into the cervical os making it difficult to sample the endocervix.
- Failure of therapy.

**3.7 Aftercare and Follow-up:** Most patients experience a heavy and often odorous discharge for the first month after cryotherapy. This discharge results from the sloughing of dead tissue and exudate from the treatment site. The patient should refrain from sexual intercourse and tampon use for 3 weeks after cryotherapy to allow the cryotherapy bed to reepithelialize. The first follow-up Pap should be done in 3 to 6 months, as Pap smear is of no value during the sloughing or regenerative phases which takes at least 3 months to complete. If this and the following smears are normal, Pap smears should

be repeated every six months for two years from treatment. Most recurrences will occur within 2 years of treatment. Yearly smears may be recommended after that. If any of the follow-up tests are positive, restart the work-up as if there was a new, first-time dysplasia.

If a follow-up Pap smear is abnormal, a colposcopy with directed biopsy is usually performed. Other treatment methods (usually LEEP) are preferred if persistent disease is discovered.

### Conclusion:

Cryosurgery is an effective treatment of cervical lesions with negligible side effects or minor complications. It is sophisticated safe procedure with predictable uniform action. It has powerful hemostatic action and sealing effect on blood vessels. Healing is rapid and complete following cryotherapy as compared to other methods like electrocoagulation, diathermy cauterization etc

### References

- Holowaty P, Miller AB, Rohan T, To T. Natural history of dysplasia of the uterine cervix. *J Natl Cancer Inst* 1999; 91:252.
- Moscicki AB, Shiboski S, Hills NK, et al. Regression of low-grade squamous intraepithelial lesions in young women. *Lancet* 2004; 364:1678.
- Ostör AG. Natural history of cervical intraepithelial neoplasia: a critical review. *Int J Gynecol Pathol* 1993; 12:186.
- Kumar, Vinay; Abbas, Abul K.; Fausto, Nelson; & Mitchell, Richard N. (2007). *Robbins Basic Pathology* (8th ed.) pp. 718–721.
- Marques JP, Costa LB, Pinto AP, et al. Atypical glandular cells and cervical cancer: systematic review. *Rev Assoc Med Bras* 2011; 57:234.
- Geier CS, Wilson M, Creasman W. Clinical evaluation of atypical glandular cells of undetermined significance. *Am J Obstet Gynecol* 2001; 184:64
- Schnatz PF, Guile M, O'Sullivan DM, Sorosky JI. Clinical significance of atypical glandular cells on cervical cytology. *Obstet Gynecol* 2006; 107:701.
- Agorastos T, Miliaras D, Lambropoulos A, Chrisafi S, Kotsis A, Manthos A, Bontis J (2005). "Detection and typing of human papillomavirus DNA in uterine cervixes with coexistent grade I and grade III intraepithelial neoplasia: biologic progression or independent lesions?". *Eur J Obstet Gynecol Reprod Biol* 121 (1): 99–103.
- Bosch FX, Burchell AN, Schiffman M, Giuliano AR, de Sanjose S, Bruni L, Tortolero-Luna G, Kjaer SK, Muñoz N (August 2008). "Epidemiology and natural history of human papillomavirus infections and type-specific implications in cervical neoplasia". *Vaccine* 26 (Supplement 10): K1–16.
- 2006 Consensus Guidelines for the Management of women with Cervical Intraepithelial Neoplasia or Adenocarcinoma in situ. *American Journal of Obstetrics and Gynecology* 2007; 197(4):346-355.
- Martin-Hirsch PL, Paraskeva E, Kitchener H. Surgery for cervical intraepithelial neoplasia. *Cochrane Database Syst Rev* 2000: CD001318.
- Arnott JB. Treatment of cancer by regulated application of an anaesthetic temperature. *Year book of Gynae and Obstetrics* 1971:309.
- Townsend DE. Cryosurgery *Obst and Gynae Annuals* 1975; 4:331.
- Mayeaux EJ, Springer SD, German JA. Cryotherapy of the uterine cervix. *J. Fam Pract* 1998; 47:99-102.
- Benedet JL, Miller DM, Nickerson KG. Results of conservative management of cervical intraepithelial neoplasia *Obstet Gynecol* 1992; 79:105-110.
- Zacarian SA. Is lateral spread of freeze a valid guide to the depth of freeze? *J. Dermatol Surg Oncol* 1978; 4:561-563.
- Persad VL, Pierotic MA, Guijon FB. Management of cervical neoplasia: a 13 year experience with cryotherapy and laser. *J Low Genit Tract Dis Oct* 2001;5(4):199-203.
- Alliance for Cervical Cancer Prevention (ACCP). Effectiveness, safety, and acceptability of cryotherapy. *A Systematic Literature Review*. Seattle: ACCP; 2003. *Cervical Cancer Prevention Issues in Depth*, No. 1.