

## Wound healing activity of *Cynodon dactylon* (L.) Pers. in albino wistar rats

Anand Kumar<sup>\*1</sup> and Pranita Kashyap<sup>2</sup>

<sup>1</sup>Head, Department of Pharmacy, University Teaching Department, Sarguja University, Ambikapur – 497001, (C.G.), India.

<sup>2</sup>Principal, Shri Rawatpura Sarkar Institute of Pharmacy, Behind Holiday Resort, Kumhari – 490042, (C.G.), India.

### \*Correspondence Info:

Anand Kumar,

Head, Department of Pharmacy,

University Teaching Department, Sarguja University, Ambikapur – 497001, (C.G.), India.

E-mail: [anandpharm007@gmail.com](mailto:anandpharm007@gmail.com)

### Abstract

Plant *Cynodon dactylon* (L.) Pers. family Poaceae is extensively used in clinical practice but it has various pharmacological activities have been report with persistent findings till date. It is a very familiar plant of our surrounding and almost available in all corners of the world. In ethnomedicinal practices, the juice of the plant is used as astringent and is applied to fresh cuts and wounds. The wound healing activity was described earlier in an ayurvedic formulation (Durva-Ghrita) containing *C. dactylon*, but the significant data and the correct justification, was not clarified that, whether it is because of Ghrita (Indian cow ghee) or, why the *C. dactylon* was used in that ayurvedic formulation & how it interferes with the wound healing.

Wound healing property of Hydroalcoholic extract of *Cynodon dactylon* (L.) Pers. was evaluated by using excision wound model. The parameters included the rate of wound contraction & period of epithelization in excision wound model. Herbal ointment was prepared using different bases & concentrations i.e. 7.5%, 10% respectively In two concentrations herbal ointment was prepared 7.5%, 10%, respectively, compared with standard Cipladine (Povidone-iodine) as per OECD guidelines.

**Key Words:** *C. dactylon*, HAE, CPSCEA, OECD

### 1.Introduction

More than 80% of the world's population depends upon traditional medicines for various skin diseases<sup>1</sup>. Recently, the traditional use of plants for wound healing has received attention by the scientific community<sup>2</sup>. Approximately one-third of all traditional medicines in use are for the treatment of wounds and skin disorders, compared to only 1-3 % of modern drugs<sup>3</sup>.

The processes of wound healing involve a variety of biological responses, such as an acute inflammation, cellular proliferation and a contraction of the collagen lattice formed<sup>4-5</sup>. Wounds caused by environmental insults such as mechanical and chemical injuries, may extend from the epidermis deep into the muscles depending on the severity of damage. Wound thus caused can be healed by a spontaneous process in the organism through a cascade of events, which starts by switching on various chemical signals in the body; this facilitates the restoration of anatomical continuity and function. While partial thickness wound heals by mere epithelialization, the healing of full thickness wound which extends through the entire dermis involves more complex well-regulated biological events resulting in the formation of hypertrophic scars<sup>6-7</sup>. The healing process begins with the clotting of blood and is completed with re-modelling of the cellular layers of the skin. However, the wound healing process may be prevented by the presence of ROS (Reactive oxygen species) or microbial infection, since the type of cells to be first recruited to the site of injury is the neutrophil

which is produced in response to cutaneous injury<sup>8</sup> and which has a role in antimicrobial defense and may cause cellular damage by peroxidation of membrane lipids<sup>9-10</sup>. Appropriate method for healing of wounds is essential for the restoration of damaged tissue anatomical continuity and disturbed functional status of the skin<sup>11</sup>. Research on wound healing agents is one of the developing areas in modern biomedical sciences and many traditional practitioners across the world particularly in countries like India and China have valuable information of many plants for treating wounds and burns<sup>12</sup>.

For this reason traditional plant based remedies are back and find increasing application as source of direct therapeutic agents. Considerable scientific data have been generated worldwide in this direction and there are spurt of study on natural product study. Based on this rationale, the study has been compiled and provides data on potential medicinal properties, action and uses of plants in order to contribute material leading to the discovery of new drugs of natural origin<sup>13</sup>. Among numerous species of plants growing wild in India, doob ghas, or Durva or taxonomically the *Cynodon dactylon* (L.) Pers. family Poaceae occupies its unique place and key position in ethnomedicinal practices and traditional medical (Ayurvedic, Unani, Nepalese, and Chinese) knowledge systems. The herbal preparations of this grass are being based on folklore and traditional wisdom<sup>14</sup>.

According to *Ayurveda*, India's traditional pharmacopoeia, *Cynodon* plant is pungent, bitter, fragrant, heating, appetizer, vulnerary, anthelmintic, antipyretic, alexiteric. It destroys foulness of breath, useful in leucoderma, bronchitis, piles, asthma, tumors, and enlargement of the spleen. In Homoeopathic systems of medicine, it is used to treat all types of bleeding and skin troubles<sup>15</sup>.

It contains essential oil triticin 12.4%. The other chemical constituents are glycosides, saponins, tannins, flavonoids, & carbohydrates<sup>16</sup>. It also contains agropyrene, arunodin, furfural, furfural alcohol,  $\beta$ -ionine, 2-(4'-hydroxy phenyl) propionic acid, 2-(3'-methoxy-4'-hydroxy-phenyl) propionic acid, 3-methoxy-4-hydroxy benzoic acid, phytol,  $\beta$ -sitosterol-D-glucoside, stigmasterol acetate, phagostimulant phytone (6,10-14-trimethyl pentadecane-2-one)<sup>17</sup>. Cuticular wax contains triacontane, docosanol, tetracosanol, hexacosanol, octacosanol, eicosanic acid & docosanoic acid (spencer & chapmann)<sup>18</sup>.

## 2. Materials and Methods

### 2.1. Collection of plant material

The whole plant of *Cynodon dactylon* (L.) Pers. were collected from the Botanical garden of Shri Rawatpura Sarkar Institute of Pharmacy, Kumhari, Dist.- Durg, Chhattisgarh, India in September 2010, cleaned and dried at room temperature in shade and away from direct sunlight. The plant authenticated by Dr. Mrs. Ranjana Shrivastava, HOD, Dept. of Botany, Govt. V.Y.T. P.G. Autonomous College, Durg (C.G.), by comparing morphological features and a sample voucher of specimen of plant was deposited for future reference sample voucher specimen no. is GPG/SRIP/PH/10/21.

### 2.2. Preparation of extract

The whole plant of *Cynodon dactylon* (L.) Pers. were collected and dried in the shade and then pulverized in a grinder. The powdered drug was utilized for extraction. Material was passed through 120 meshes to remove fine powders and coarse powder was used for extraction. A method was used for extraction of powdered material<sup>18</sup>. Extraction was done by using Hydroalcoholic solvent (70:30% ratios). The yield of the extract was found to be 11.5%w/w.

### 2.3. Preliminary phytochemical screening

Phytochemical screening was carried out according to standard methods. Extracts shows the presence of carbohydrates, glycosides, flavonoids, saponins, alkaloids, phenolic compounds, tannins, fixed oil, & mucilage<sup>19</sup>. Inorganic constituents present in selected plant *C. dactylon* are calcium, magnesium, chloride, iron & sulphur<sup>20</sup>.

Thin layer chromatography of various extracts of *C. dactylon* has confirmed the presence of Secondary metabolites like: alkaloids, glycosides, saponins, tannins & flavonoids as the colour of spots & their Rf value of standard<sup>21</sup> matches to that of sample (Khandelwal 2005)<sup>22</sup>.

### 2.4. Experimental design

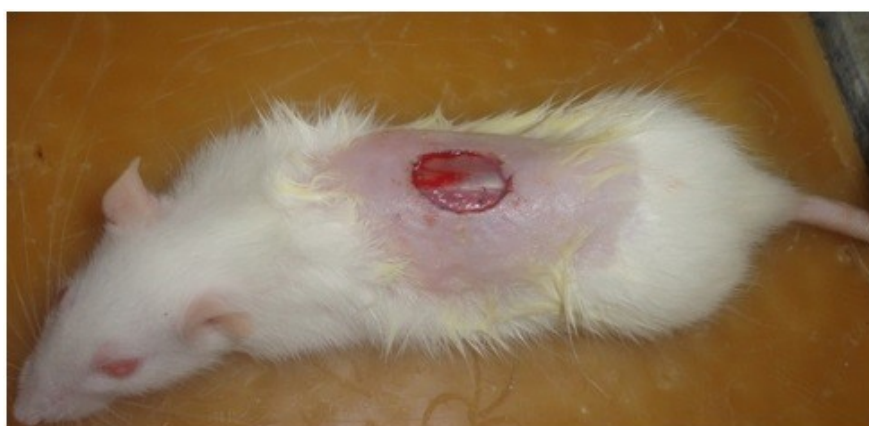Healthy male Albino Wistar rats (180-200 g) of 2-3 months of age were used, and the animal experiments were performed in accordance with legislation on welfare (CPCSEA). The animals were acclimatized to standard laboratory

conditions for a week prior to the initiation of the experiment. Environmental conditions of temperature ( $22 \pm 3^{\circ}\text{C}$ ), humidity ( $60 \pm 5\%$ ) and a 12-h light/dark cycle. The animals were fed with a standard laboratory diet (Godrej Agro Food Industries, Bangalore, India) and were provided with clean drinking water *ad libitum*. Twelve hours before the start of the experiment, rats were deprived of food, but given free access to water. Excisions of wounds were made as described by Morton and Malone<sup>23</sup>.

#### 2.4.1. Excised wound healing activity

Wound induction and evaluation extracts for properties wound healing before the beginning of the wound healing experiments. Animals were anesthetized with 1.5 mg/kg, *i.p.* of Ketamin and Xylazine and placed in operation table in its natural position the dorsal skin of the Wistar rats were cleaned by using a solution of hair remover. A full thickness of the excision wound (circular area about 150 mm<sup>2</sup> and 2 mm depth) was created along the markings using toothed forceps, a surgical blade and pointed scissors<sup>24</sup> was made on depilated ethanol-sterilized dorsal thoracic region of male Albino Wistar rats weighing 180-200g.

**Figure 1: Excision Wound Model.**



The animals were divided randomly into nine groups of six rats each. Group 1 was left untreated served as (Blank); group 2 was treated with Cipladine (Povidone-iodine) ointment and served as a reference (Allopathic Standard); groups 3 was treated with Durva Ghrita ointment served as (Ayurvedic Standard); group 4 was treated with the Ghrita Base served as (Control); group 5 was treated with Hydrophilic Base served also as (Control); group 6 was treated with FM- 1: 7.5%, group 7 was treated with FM- 2: 10%; group 8 was treated with Oleaginous Base also served as (Control); group 9 was treated with FM-3: 10%, all these group {6,7, & 9} were served as (Test), and treated topically with the respective ointments & ointment bases, till the epithelialization was complete. The percentage of wound closure and period of epithelialization were recorded.

During the wound healing period, the wound contraction was studied by tracing the raw wound area manually subsequently on day 1, 4, 8, 12, 16, 18 and 21 on graph paper. Scar residue, area and time for complete epithelialization were also measured and photographed. The wound area at days 7<sup>th</sup>, 14<sup>th</sup> and 21<sup>st</sup> the experiment was terminated and the wound area was removed from the surviving animals for histological examination<sup>25</sup>. The excision skin biopsies were fixed in 4% formaldehyde solution 48h during the experimentation period. The percentage of wound closure was calculated as follows using the initial and final area drawn on glass slides during the experiments<sup>26</sup>: % of wound closure = (wound area on day 0 - wound area on day n)/wound area on day 0  $\times$  100 where n is a number of days (7<sup>th</sup>, 14<sup>th</sup>, and 21<sup>st</sup>day).

#### 2.5. Statistical Analysis

All the data were expressed as Mean  $\pm$  S.D. Tukey-Kramer multiple comparison test and one way analyses of variance (ANOVA) were performed. A value of  $P < 0.05$  was considered significant.

### 3. Results

Many studies indicate that plant products are potential agents for wound healing and largely preferred because of the absence of unwanted side effects and their effectiveness. In this report, we show for the first time that the topical application of hydroalcoholic extracts of *C. dactylon* (*L.*) *Pers.* promoted wound healing activity in excision model in rats.

**Table 1: Effect of the treatments on the evolution of wounds in rats after 7, 14 and 21 days of topical application.**

Treatment	Inflammation cells			Collagen fibres			Organization of the collagen			Necrosis			Fibrins		
	Day 7	Day 14	Day 21	Day 7	Day 14	Day 21	Day 7	Day 14	Day 21	Day 7	Day 14	Day 21	Day 7	Day 14	Day 21
Blank	+++	++	+	-	-	+	-	-	+	+++	++	+	+++	++	+
Povidone-Iodine	++	+	-	+	++	+++	-	+	++	++	+	-	++	+	-
Durva Ghrita	++	+	-	+	++	+++	-	+	++	++	+	-	++	+	-
Ghrita Base	+++	++	+	+	+	++	-	+	+	+++	++	-	++	+	+
Hydrophilic Base	++	+	+	+	+	++	-	+	+	+++	++	-	++	+	+
FM-1: 7.5%	++	+	-	+	++	+++	+	+	++	++	+	-	++	+	-
FM-2: 10%	++	+	-	+	++	+++	+	+	++	++	+	-	++	+	-
Oleaginous Base	++	+	-	+	+	++	-	+	++	+++	++	-	++	+	+
FM-3: 10%	+	+	-	++	+++	+++	++	+++	+++	+	-	-	+	-	-

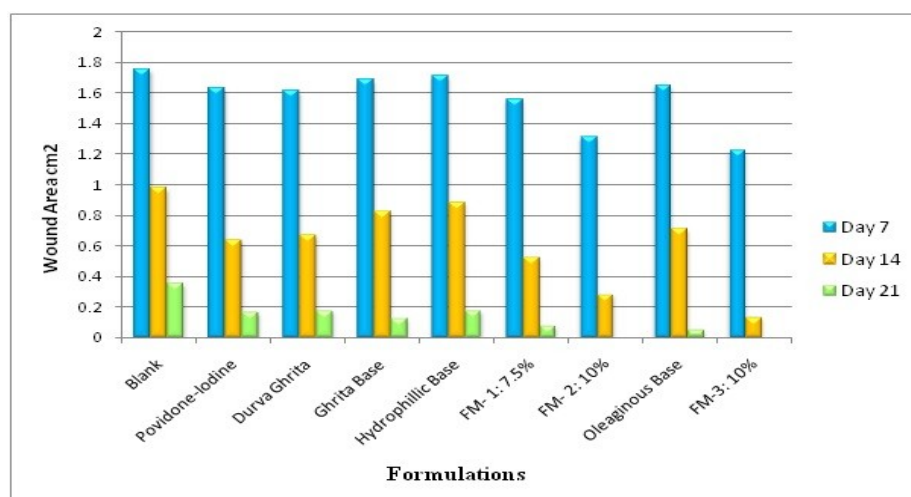
Note: + : Slight, ++ : Moderate, +++ : Extensive, - : Absent.

#### 4. Discussion

Wound healing is a process by which damaged tissue is restored as closely as possible to its normal state and wound contraction is the process of shrinkage of the area of the wound. It is mainly dependent upon the type and extent of damage, the general state of health and the ability of the tissue to repair. In this study the HAE of *C. dactylon (L.) Pers.* topical application of formulation-III which contains 10% HAE formulated in oleaginous base improved wound contraction and closure, and the effects were distinctly visible starting from 7<sup>th</sup> post-wounding day. Also formulation-II which contains 10% HAE formulated in hydrophilic base also significantly improved the rate wound contraction and significantly shortened the period of epithelization, and collagen turnover. Collagen, the major component which strengthens and supports extracellular tissue, is composed of the amino acid, hydroxyproline, which has been used as a biochemical marker for tissue collagen<sup>26</sup> which was more or less similar to the result of Cipladine (Povidone-iodine) treated group and it was less in control animals.

The preliminary phytochemical analysis of the flower extract of *C. dactylon (L.) Pers.* named Durva, doob showed the presence of polyphenol compounds such as tannins, flavonoids, & carbohydrates<sup>17</sup>. It also contains agropyrene, arunodin, furfural, furfural alcohol,  $\beta$ -ionine, 2-(4'hydroxy phenyl) propionic acid, 2-(3'methoxy-4'hydroxy-phenyl) propionic acid, 3-methoxy-4-hydroxy benzoic acid, phytol,  $\beta$ -sitosterol-D-glucoside, stigmaterol acetate, phagostimulant phytone (6,10-14-trimethyl pentadecane-2-one). Polyphenol compound may be responsible for antimicrobial activity. It may be either due to the individual or additive effect of the phytoconstituents that hasten the process of wound healing. The exact component of the extract that is responsible for this effect, however, was not investigated. Further phytochemical studies are needed to isolate the active compound(s) responsible for these pharmacological activities.

**Figure 2:** Comparison of means of the wound areas at different days of evolution by Tukey-Kramer test. The means with different letters are significantly different at 0.05 probability level according to Tukey-Kramer Multiple Range test.



## 5. Conclusion

The present study demonstrated that hydroalcoholic extract of *C. dactylon* (L.) Pers. was capable of promoting wound healing activity. Enhanced wound contraction and histological observations suggest that *C. dactylon* (L.) Pers. has potential in the management of wound healing and suggests further study.

## Acknowledgement

Author sincerely thanks to Dr. Mrs. Pranita Kashyap (Phd, MBA) for her professional expertise guidance, and also to Mr. H. A. Sawarkar & Mr. V. S. Deshmukh for their prompt suggestions and technical support.

## References

1. Annan K, Houghton PJ. Antibacterial, antioxidant and fibroblast growth stimulation of aqueous extracts of *Ficus asperifolia* Miq. and *Gossypium arboreum* L., wound-healing plants of Ghana. *J Ethnopharmacol.* 2008 Sep 2;119(1):141-4.
2. Houghton PJ, Hylands PJ, Mensah AY, Hensel A, Deters AM. *In vitro* tests and ethnopharmacological investigations: Wound healing as an example. *J Ethnopharmacol.* 2005;100:100-7.
3. Mantle D., Gok M.A., Lennard T.W.J et al.: Adverse Drug React. *Toxicol. Rev* 2001: 20: 89.
4. Bodeker G and Hughes MA, Wound Healing, traditional treatment & research policy. *Plants for food & medicine.* 1<sup>st</sup> ed. Royal Botanic gardens kew, London (1998) : 345-359.
5. SureshReddy J, Rao PR, et al. Wound healing effects of *Heliotropium indicum*, *Plumbago Zeylanicum* & *Acalypha indica* in rats, *J. Ethnopharmacol* 2002; 79: 249-251.
6. Clark Raf, *Biology of dermal wound repair in dermatologic clinics* (Nemeth AJ ed) Elsevier, Philadelphia (1993), PA, ETATS – UNIS. Wound healing 11: 647-666.
7. Sumitra M, Manikandana P, et al. Efficacy of *Butea monosperma* on dermal wound healing in rats. *Int. J. Biochem. Cell. Biol* 2005; 37: 566-573.
8. Gupta A, Singh RL, et al., Antioxidant status during cutaneous wound healing in immunocompromised rats. *Mol. Cell. Biochem* 2002; 241: 1-7.
9. Russo A, Long R, et al. Antioxidant activity of Propolis role of caffeic acid phenethyl ester & galangin. *Fitoterapia* 2002; 73: 21-29.
10. Choi BS, Song HS et al., Effect of coenzyme Q10 on cutaneous healing in skin incised in mice. *Arch. Pharm Res* 2009; 32: 907-913.
11. Meenakshi S, Raghvan G, et al. Antimicrobial, wound healing & antioxidant activity of *Plagioclasma appendiculatum*, *J. Ethnopharmacol* 2006; 107: 67-72.
12. Kumar B, Vijayakumar M, et al. Ethnopharmacological approaches to wound healing – Exploring medicinal plants of India. *J. Ethnopharmacol* 2007; 114: 103-113.
13. Khosoo TN, Dharm of ecology, *Current science* 1999;77 (9):1147-1153.
14. Mishra MP: Succession of fungi and their eco-microbial involvement in the decay of *Cynodon dactylon* Pers., Ph.D. Thesis: (2006), 14: 14-21.
15. Traditional medicinal knowledge about useful herb Doobi (*Cynodon dactylon*) in Chhattisgarh, India. [http://botanical.com/site/column\\_poudhia/111\\_doobi.html](http://botanical.com/site/column_poudhia/111_doobi.html), 12 sep 2010.
16. The wealth of India, Raw materials, 1<sup>st</sup> supplement series, CSIR, Vol. 2 page no.331-332.
17. Wallis T.E: Text book of Pharmacognosy, Plant profile for *Cynodon dactylon* (Bermudagrass) USDA Plants.html, 5<sup>th</sup> ed. Vol.-II, p. 243-244.
18. Mukherjee, Pulok K. Quality Control of Herbal Drugs 2002. *Business Horizon*, 5-34, 97, 98, 181-195, 248, 249, 562-567.
19. Kirtikar Basu. *Indian Medicinal Plants.* 2<sup>nd</sup> ed. Elsevier publications Vol. 3. p. 1042-43
20. Trease and Evans, *Textbook of Pharmacognosy*, Elsevier; 15<sup>th</sup> ed. p. 204-205, 479.
21. *The Ayurvedic Pharmacopoeia of India*, Government of India Ministry of Health & Family Welfare. 1<sup>st</sup> ed. Part-1, Vol.- II, p. 62.
22. The wealth of India, 2<sup>nd</sup> supplement series, Raw materials, CSIR, Vol. 1 page no.331-332.
23. Morton JJP, & Malone MH et al., Evaluation of vulnerary activity by an open wound procedure in rats. *Arch. Int. Pharm*, 1972, 196: 117-126.
24. Khalil E.A., Afif F.U., Al-Hussainin M. et al. Evaluation of the wound healing effect of some Jordanian traditional medicinal plants formulated in pluronic F127 using mice (*Mus musculus*). *J. Ethnopharmacol* 2006; 109-104.
25. Wall S.J., Bevan D., Thomas D.W., Harding K.G., Edwards D.R., Murphy G. et al.: *J. Invest. Dermatol* 2002; 119: 91.
26. Senthil-Kumar M., Kirubanandan S., Sripriya R., Kumar Sehgal P. et al. Triphala promotes healing of infected full-thickness dermal wound. *J Surgical Research* 2006, 144: 94-101.