International Journal of Biomedical Research

ISSN: 0976-9633 (Online)
Journal DOI:10.7439/ijbr
CODEN:IJBRFA

Case Report

A Rare Case of Metastatic Bilateral Ovarian Dysgerminoma with Elevated CA-125 Levels

Swati Francis[*1], Kadri Yogesh Bangera[1], Rajagopal Kaipangala[1] and Devdas Acharya[2]

[1]*Department of Obstetrics & Gynecology, Yenepoya University, Deralakatte, Karnataka, India.*
[2]*Department of Radiology, Yenepoya University, Deralakatte, Karnataka, India.*

***Correspondence Info:**
Dr. Swati Francis
Resident,
Department of Obstetrics & Gynecology,
Yenepoya University, Deralakatte, Karnataka, India.
E-mail: swati.francis@gmail.com

Abstract

Ovarian dysgerminomas although rare are the most common malignant germ cell tumors of the ovary and comprise 2% of all ovarian malignancies. These tumors are most commonly seen in young girls and young women. Once diagnosed accurately, chemotherapy following post-op has excellent prognosis. We present a rare case of bilateral ovarian dysgerminoma in a 25 year old female patient with metastases and elevated CA-125 levels, with transvaginal ultrasound and CT correlation.

Keywords: Dysgerminoma, CA-125, Ovarian mass

1. Introduction

Ovarian dysgerminoma has its origin from undifferentiated primordial germ cells. It is a rare malignant germ cell tumor with peak incidence between 14-17 years. Germ cell tumors are the commonest ovarian tumors in childhood and adolescence and are mostly unilateral. Less than 10% of patients show bilateral presentation. We present a rare case of bilateral ovarian dysgerminoma in a 25 year old female patient.[1,2]

2. Case Report

A 25 year old deaf and mute female patient presented with chief complaints of pain abdomen radiating to the back along with abdominal distention since one month. She gave history of on and off fever associated with chills. Per abdomen shifting dullness and fluid thrill were positively elicited. Ultrasound abdomen and pelvis revealed bilateral heteroechoic solid-cystic adnexal masses with non-visualization of ovaries, in addition to gross septated ascites (Fig.1). With these findings she underwent contrast enhanced CT of abdomen and pelvis for further evaluation which revealed bilateral heterogeneously enhancing adnexal masses with solid cystic areas measuring 12x7 cm on the right side and 13x8 cm on the left side (Fig.2a). There was also gross ascites with metastatic deposits posterior to the uterus (Fig.2b). Her Serum CA-125 levels were 8820 u/ml. Ascitic fluid aspirated for cytological examination revealed large cells with clear cytoplasm, well defined cell membrane, nuclei with nucleoli, large number of lymphocytes admixed with tumor cells suggestive of dysgerminoma (Fig.3). In view of the large bilateral ovarian massesalong with metastases, surgery was out of the option and the patient was advised for chemotherapy. Six months post chemotherapy (Inj. Carboplatin and Inj. Cyclophosphamide), the patient was evaluated, and showed decreased CA-125 levels (120 u/ml) and reduction in size of the adnexal masses.

Fig.1. Ultrasound of the pelvis (extended panoramic view) revealed bilateral adnexal predominantly solid echogenic lesions with cystic components measuring 12 x 7cm and 13 x 8cm on the right and left respectively with septated ascites.

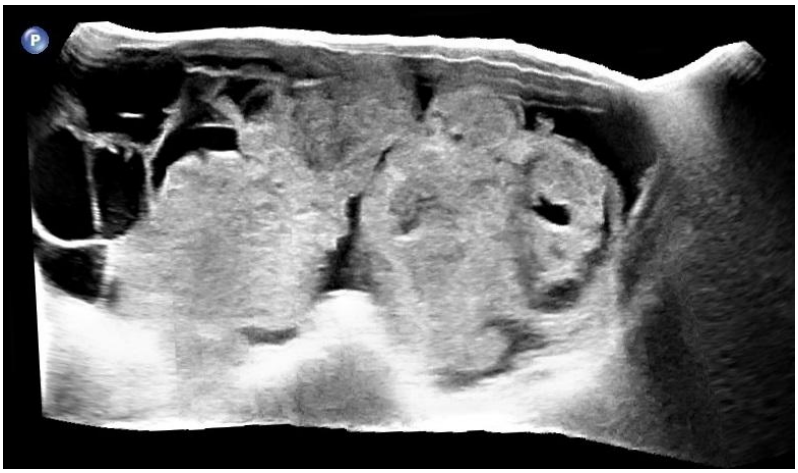

Fig.2a. Post Contrast CT of the abdomen and pelvis (coronal view) showed heterogeneously enhancing solid lesions (white arrows) arising from both the ovaries along with ascites.

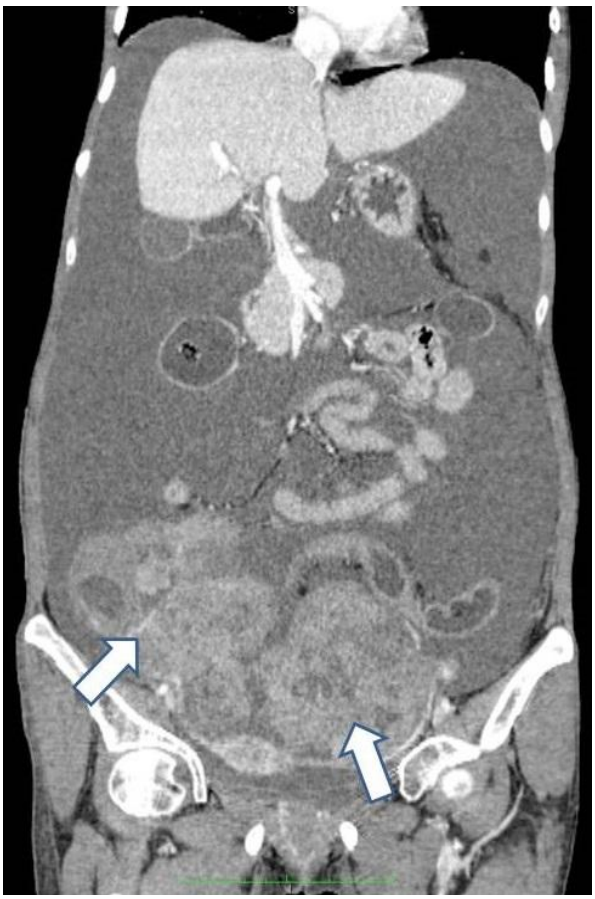

Fig.2b. Post Contrast CT of the abdomen and pelvis (sagittal view) showed metastatic deposit (white arrow) posterior to the uterus along with the ovarian mass (white arrow head).

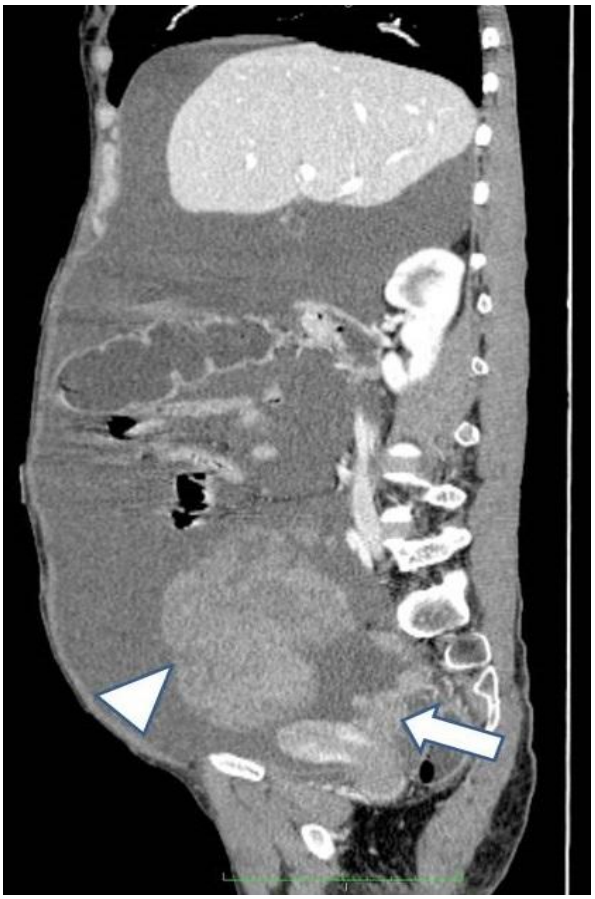

Fig.3. Ascitic fluid cytology revealed large cells with clear cytoplasm, well defined cell membrane, nuclei with nucleoli, large number of lymphocytes admixed with tumor cells suggestive of dysgerminoma

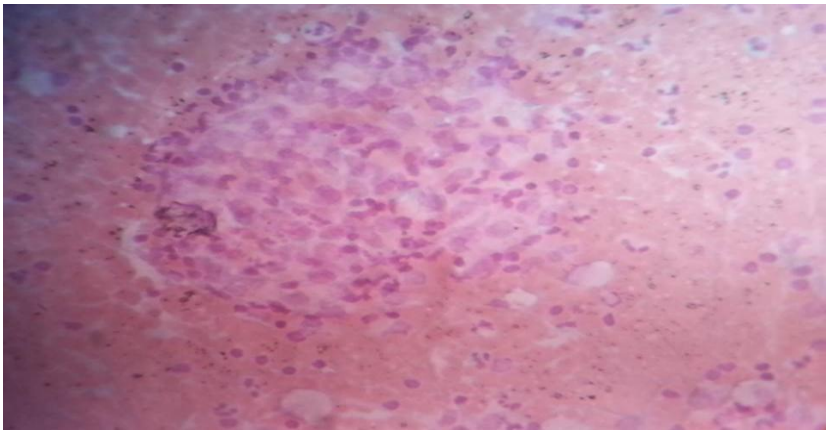

3. Discussion

Ovarian dysgerminoma is the most common malignant germ cell tumor affecting the ovary.They form 1% of all ovarian cancers. Dysgerminomas arise from primordial germ cells and 80% of all cases occur in the 2nd and 3rd decade while about 5% are seen under the age of 10 years. Patients present with abdominal pain and distention with reduced appetite, nausea and vomiting.[1,2] On clinical examination an abdominal mass maybe felt. Dysgerminomas represent the female counterpart of seminoma of the testis and is unique among all malignant germ cell tumors of the ovary due its tendency for being bilateral (in 20% of cases) and radiosensitive.[3,4] Useful tumor markers in dysgerminomas include mainly β-hCG, LDH and AFP. Although most commonly β-hCG is elevated in choriocarcinomas and embryonal carcinomas, dysgerminomas with synctiotrophoblasts can also produce elevated β-hCG levels. Other tumor markers that can also be elevated in dysgerminomas include CA-125, CA19.9, neuron specific enolase (NSE), angiotensin, macrophage colony stimulating factor (MCSF). These tumor markers are also useful in follow up and tracking of adjuvant therapy. However, the absence of elevated tumor markers does not rule out the possibility of dysgerminomas.[1,3,5,6] The initial approach to any pelvic mass is to determine its extent and nature. Among the

imaging modalities, transvaginal ultrasound is useful to determine if it's of ovarian origin. Advanced modalities such as CT & MRI are useful in determining its extent and character as well as the presence or absence of metastasis.[6] Diagnosing dysgerminomas accurately is of importance as these tumors have excellent prognosis. Although these tumors are rare, excellent outcomes can be achieved by surgery with post op chemotherapy. For many years radiotherapy was the main option for post-op treatment of metastatic dysgerminomas. Although it achieved excellent results it caused ovarian failure. As a result chemotherapy with bleomycin,etoposide, and cisplatin (BEP) has replaced radiotherapy in post op patients producing an equal efficacy of results while as well having the double bonus of preserving fertility in these young women.[2,4]

4. Conclusion

Ovarian dysgerminomas should be suspected as one of the possible differential diagnosis in a young female patient of the reproductive age group presenting with a palpable abdomino-pelvic mass along with elevated tumor markers. Initial imaging modalities include transvaginal ultrasound followed by CT. Diagnosing dysgerminomas accurately are important as post surgical excision followed by chemotherapy has high remission rates along with excellent survival rates. Post-op chemotherapy is preferred over radiotherapy as it helps preserve ovarian function. Serum levels of tumor markers such as β-hCG, LDH, AFP, and CA-125 are useful in assessing remissions and recurrences.[1,4,6]

References

1. Zganjer M, Cizmic A, Stepan J, Butkovic D, Zupancic B, Bartolek F. Ovarian dysgerminoma and acute abdomen. *BratislLekListy*. 2006; 107(6-7):253-5.
2. Hyseni N, Llullaku S, Jashari H, Zahiti K, Hyseni F, Kurshumliu F, Luci L, Muqolli F, and Hasani A. Advanced Ovarian Dysgerminoma Infiltrating Both Ovaries and Uterus in a 7-Year-Old Girl. *Case Reports in Oncological Medicine*. Volume 2014, Article ID 910852, 4 pages.
3. Lazebnik N, Balog A, Bennett S, Redline R, Liu J. Ovarian dysgerminoma: a challenging clinical and sonographic diagnosis. *J Ultrasound Med*. 2009 Oct; 28(10):1409-15.
4. Brewer M, Gershenson D.M, Herzog C.E, Mitchell M.F, Silva E.G and Wharton J.T. Outcome and Reproductive Function After Chemotherapy for Ovarian Dysgerminoma. *Journal of Clinical Oncology* 1999; 17(9): 2670-2675.
5. Coquard I.R. Ovarian germ-cell malignant tumors - Orphanet Encyclopedia 2004**.**
6. Hembah-Hilekaan S.K and Mbaave TP. A Rare Case Of Dysgerminoma In A 58-Year Old Postmenopausal Woman In Makurdi, North Central Nigeria. *The Internet Journal of Oncology*. 2012; 8(2).