

## Case Report

# Custom made ocular prosthesis- A case report

Gurleen Arora, Roma Goswami and Nishant Gaba\*

Department of Prosthodontics, Subharti Dental College, Meerut, India

### \*Correspondence Info:

Dr. Nishant Gaba  
Udham Singh Boys Hostel  
Subharti Dental College, Swami Vivekanand Subharti University,  
Subharti Puram, NH-58, Delhi Haridwar by Pass Road, Meerut- 250005  
Email: [nishant\\_gaba08@yahoo.com](mailto:nishant_gaba08@yahoo.com)

### Abstract

An eye is a vital organ and an important component of facial expression. Several ocular and orbital disorders require surgical intervention that may result not only in ocular defects but also have a crippling effect on the psychology on those affected.<sup>1</sup> Maxillofacial prostheses which restore and replace stomatognathic and associated facial structures with artificial substitutes, aim to improve the patient's aesthetics, restore and maintain health of the remaining structures and consequently provide physical and mental well-being.<sup>2</sup> Enucleation of the eye is therefore normally followed by fabrication of an ocular prosthesis to improve esthetics. The primary purpose of an ocular prosthesis is to maintain the volume of eye socket and create an illusion of a healthy eye and surrounding tissues. The present article describes the prosthetic management of patient with ocular defect with a custom made ocular prosthesis.

**Keywords:** maxillofacial prosthesis, custom-made ocular prosthesis, ocular defect, enucleation.

## 1. Introduction

"Eyes are the amulets of mind; one of the wonderful gifts, of nature is a glance of an Eye".<sup>3</sup> The loss of an eye due to congenital, trauma or tumor leads to disfigurement that can cause significant physical and emotional problem, either by Evisceration (where the contents of the globe are removed leaving the sclera intact). Enucleation (most common, where the entire eyeball is removed after severing the muscles and the optic nerve) or Exenteration (where the entire contents of the orbit including the eyelids and the surrounding tissues are removed) is performed primarily for eradication of malignant orbital tumor.<sup>1,2</sup>

An ocular prosthesis is an artificial replacement for the bulb of the eye (bulbous oculi, eyeball). The eyeball, or organ of sight, is contained in this cavity of the orbit, where it is protected from injury and is moved by the ocular muscles. When the entire contents of the orbit (including muscles of fascia, eyelids, conjunctiva and the lacrimal apparatus) are removed, the artificial replacement is referred to as an orbital prosthesis.<sup>4</sup>

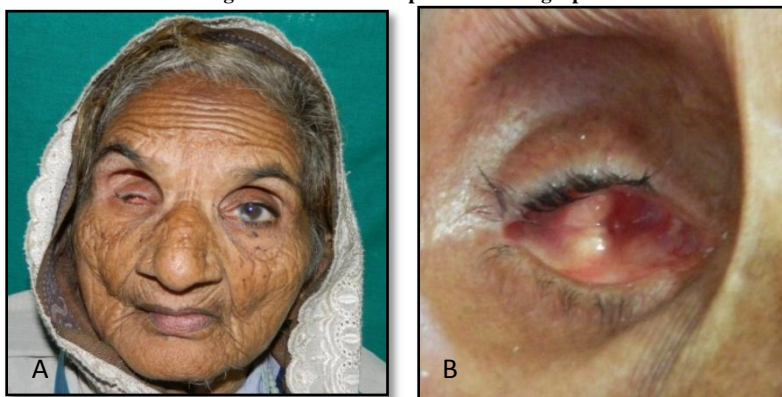Custom made ocular prosthesis shows the intimate contact with the tissue bed distributes the pressure more equally than stock prosthesis and decreases the incidence of conjunctival abrasion. The intimate tissue contact improves the tissue health by reducing fluid accumulation in tissue prosthesis interface. Fluid accumulation can cause tissue irritation and increased bacterial growth.<sup>5</sup>

This case report describes a simplified technique to fabricate an acrylic custom-made ocular prosthesis for an enucleated ocular socket.

## 2. Case Report

A 80-year old female patient reported to the department of prosthodontics, Subharti Dental College, Meerut, Uttar Pradesh (India) with the chief complaint of facial disfigurement due to shrunken eyelids of the right eye. (figs 1A and B).

**Figure 1A and B. Preoperative Photographs**



Patient had lost her right eye as a result of an injury from the sharp edge of the tree branch 2 years back following which she was diagnosed with a large hematoma and swelling of the right eye. Damaged ocular tissue and partial contents of the right eye were surgically removed by the surgeon in order to relieve pain due to hematoma.

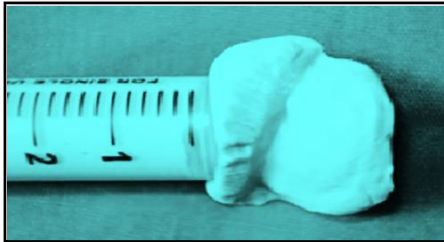Ocular examination revealed a healthy intraocular tissue bed and adequate depth between the upper and lower fornices. The conjunctiva covering the posterior wall of the ocular defect showed synchronous movements. A custom made acrylic resin ocular prosthesis was planned, and the treatment procedure explained to the patient. An informed consent was obtained from the patient prior to the procedure.

**2.1 Prosthesis fabrication technique**

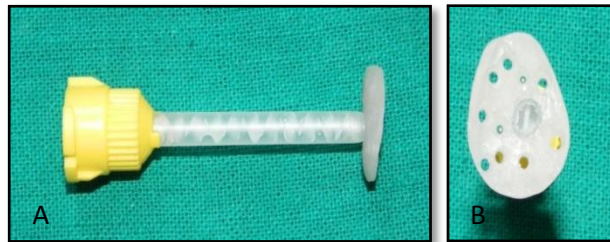1. A direct impression technique for making impression was chosen in which a preliminary impression of the defect area was made with an irreversible hydrocolloid material (Neocolloid, Zhermack.ltd Italy) with a 5 ml modified disposable syringe (Dispo van) according to the Miller technique. Before making the impression, a thin layer of petroleum jelly was applied on the eye lashes and the eye socket to prevent the impression material from sticking on the eyelashes. (Fig 2).

2. A Custom tray to conform the defect area was made with clear auto polymerizing resin (Fig.3A and 3B)

**Figure 2: Preliminary impression**

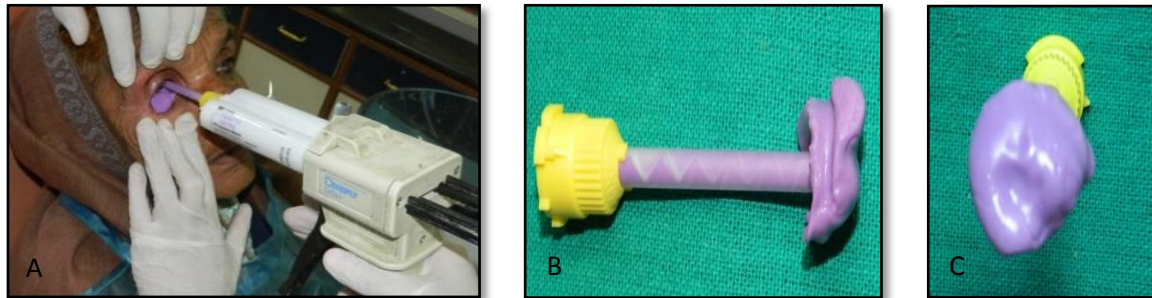


**Figure.3A and 3B: Custom made impression tray**



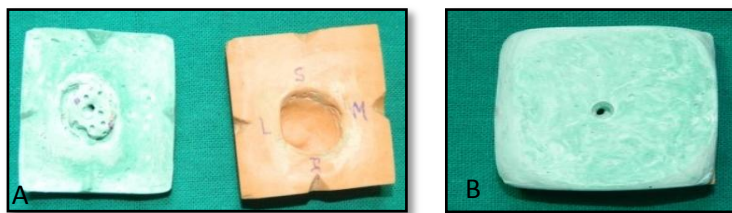
3. The final impression of the defect area was made with polyvinyl siloxane light body impression material (Aqausil, Dentsply). The patient was instructed to move her eye to the right then to the left, then up and down and finally in acircular motion, so that the functional impression of the defect could be obtained and to allow the material to flow into all areas of the enucleated socket, as well as onto the tray's outer surface to record lid movements. (Fig- 4A, 4B and 4C)

**Figure 4A, 4B and 4C: Final Ocular impression**



4. The impression was removed from the socket and initially poured till the height of contour with the type IV dental stone (Kalastone, Kalabhai Pvt Ltd, Mumbai, India). After the setting of the stone, keyholes were made and boxed. Then a second layer was poured with type III dental stone (Kalastone, Kalabhai Pvt Ltd, Mumbai, India) to obtain a two piece cast for the orientation of ocular prosthesis. The two halves of casts were separated and the final impression retrieved, mold space created after removal of impression to be filled with wax. Wax pattern is obtained through sprue channel created on the top of the cast. (Fig- 5A, 5B)

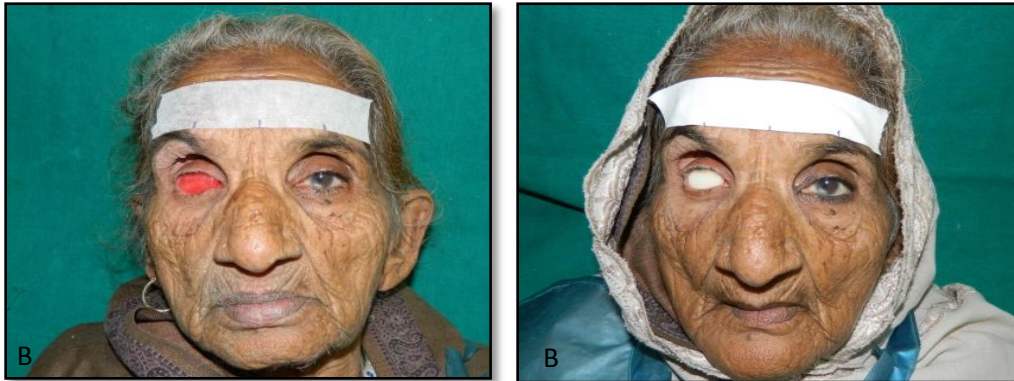**Figure- 5A, 5B: Split Cast**



5. The wax pattern was fabricated using modelling wax (Y-Dent, MDM Corporation New Delhi). The fit of the wax pattern was evaluated by observing the extension into the fornices. The height of convexity of the wax pattern should be centered over the pupil and palpebral opening should be same as that of natural eye.

6. Transfer Marking:-The distance was measured from the midline to the centre of the pupil of the natural eye and the same distance to the left side was marked and engraved into the wax pattern. Wax pattern was flaked and processed using heat polymerizing acrylic resin (DPI-Heat cure, Dental Products of India Ltd). The scleral blank was tried in, with the patient sitting erect and viewing an object kept at least 3 feet in front and at eye level of natural eye (Fig. 6A and 6B). The supraorbital folds, margins of the lower eyelids and iris plane were evaluated, all of which resembled the natural eye.

Figure 6 A and 6 B: Try-in of wax pattern and scleral blank



Patient's eye movements were checked for symmetry and function and it was checked that the wax tryin and scleral blank both moved and synchronised in harmony with the patient's natural eye movements.

7. The final painting was done with a variety of colours.

The choice of colours being:

- Titanium white
- Ivory black
- Yellow ochre
- Burnt umber
- Crimson Red

The normal eye was studied, under natural light (Fig 7) and painting is started from the periphery of the iris.

Zone 1: Colour within the limbus and is called the background.

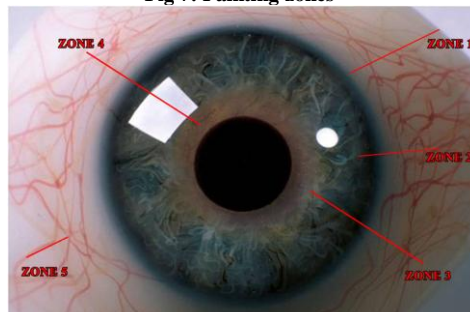
Zone 2: Zone around the pupil which is immediately next to zone 1

Zone 3: Radiating delicate structures of the iris-seen normal eye with torch.

Zone 4: Immediately surrounds the pupil looks like halo of the pupil.

Zone 5: Scleral painting

Fig 7: Painting zones



**2.2 Scleral painting**

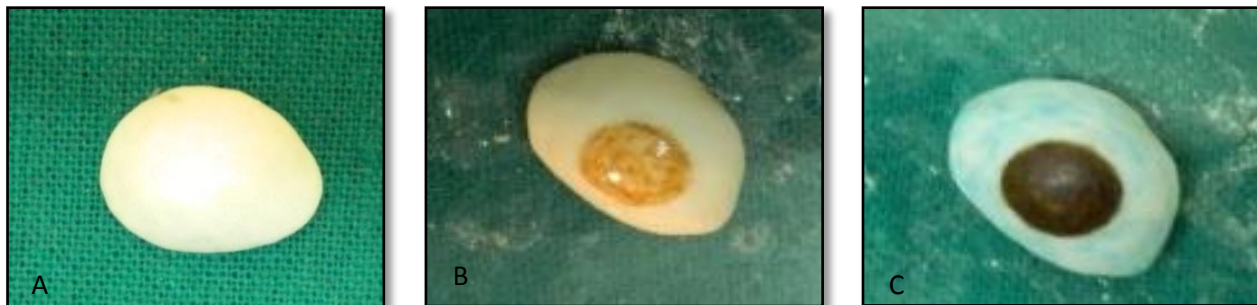Pupil was painted first, shading natural eye.

Base color and detail-Darkest Color observed in natural blue, brown, gray, or a combination. Applied in a heavy layer with a brush, developed in layers going from darker to lighter colors in thin radial strokes with Striations creating an illusion of depth.

Collarette -Little brighter than the base color.

Limbus -Painted on the iris side and shade that blends iris painting with the sclera.

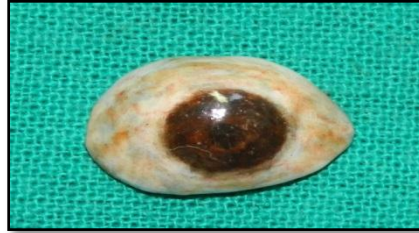Fig. 8A, 8B, 8C: Scleral Painting



And doing scleral painting it is coated with a 1, 2-Dichloroethane which acts as a solvent forming a thin layer thereby preventing the dissolution of the paint.

8. The prosthesis was finished and polished with the flour of pumice (Whip Mix Corporation, USA) (Fig. 9). The properly finished and polished prosthesis was inserted in the socket after being disinfected and lubricated with an ophthalmic lubricant (Eco tears, Intas pharmaceuticals Ltd, Ahmedabad, India) to maintain a tear film over the prosthesis and to improve eye movements. Minor adjustments were made at the time of delivery as per the patient's comfort and esthetics.

**Fig. 9: Finished prosthesis**



**Fig.10: Preoperative and postoperative facial view**



### 2. 3 Instructions to the patients:

The patient was instructed well regarding handling and care.

- During insertion, the patient has to stand in the front of the mirror, evert the lower eyelid and insert the lower part the prosthesis well in to the fornices.
- Holding the prosthesis, patient was instructed to lift the upper eyelid and complete the insertion of prosthesis. The patient is instructed to blink gently to ensure complete seating.
- The patient should be recalled for follow up after 1 day, 3 days and one week for follow up.
- There is no need for the patient to remove the prosthesis except for cleaning. Once a week with mild soap and rinsed well.
- The prosthesis should be inspected for scratches or deposits, if any are noted the patient should return to have the prosthesis repolished.
- The patient should be recalled after six month's interval to have the defect and the prosthesis evaluated and adjusted if necessary.

### 3. Discussion

Surgical enucleation is the process in which the entire eyeball is severed from the muscles and optic nerve and is mainly carried out in the cases of trauma, malignancy and infection leading to loss of a vision and poor esthetic appearance.<sup>6</sup> Rehabilitation of patients with ocular defects has always remained an enigma for the prosthodontist. Treatment options like prefabricated eye shells, custom made ocular prosthesis or bio-eye implant prosthesis are available for rehabilitation of such defects.<sup>5</sup>

The need for an ocular prosthesis can sometimes be fulfilled by stock prosthesis that comes in standard sizes, shapes, and colours. Stock ocular eye requires no special skills or materials for fabrication. They are relatively inexpensive and the entire process is also less time consuming. However, in majority of cases of enucleation custom ocular prosthesis is advantageous as there is improved adaptation to underlying tissues, increased mobility of the prosthesis, and acceptable esthetics due to better match of the size and color of the iris and sclera. Nevertheless, a custom prosthesis is more expensive than a stock prosthesis, and several steps are required for its fabrication.<sup>2</sup>

According to Beumer *et al.* intimate contact between the ocular prosthesis and the tissue bed is needed to distribute even pressure, so a prefabricated prosthesis should be avoided. Moreover, the voids in the prefabricated prosthesis collect mucus and debris, which can irritate mucosa and act as a potential source of infection, which are minimized in custom-made prosthesis.<sup>7</sup>

Allen and Webster (1969) recommended a perforated stock ocular tray for alginate impression. Cain (1982) suggested using an impression tray with a hollow stem in the shape of the ocular prosthesis. Skes *et al.* (1999) utilizes medium viscosity addition silicone, which can be easily removed from undercuts without distortion. Doshi and Aruna (2005) impression material was directly injected into the socket. No custom tray was fabricated.<sup>2</sup>

Custom –made ocular prosthesis has the following characteristics<sup>8</sup>:

1. Retains the shape of the defective socket.
2. Prevents collapse or loss of shape of lids.
3. Provides proper muscular function of the lids.
4. Prevents accumulation of fluids in the cavity.
5. Maintains palpebral opening similar to the natural eye.
6. Mimics the colouration and proportions of the natural eye.
7. Has a gaze similar to the natural eye.
8. Better movement of the prosthesis mimicking that of the natural eye.

#### 4. Conclusion

Prosthetic rehabilitation is advantageous in that it is relatively quick, reversible, medically uncomplicated and allows the surgical site to be closely monitored. A properly fabricated custom-made prosthesis enhances the patient's comfort and confidence by increased adaptiveness and natural appearance. Although the patient cannot see with this prosthesis, it has definitely restored her self-esteem and allowed her to confidently face the world.

#### References

1. Goel BS, Kumar D. Evaluation of ocular prosthesis. *J All India Ophthalmol Soc* 1969; 17:266-9.
2. K Somkuwar, R Mathai & P Jose. Ocular prosthesis: Patient rehabilitation - A Case Reprot, *People's Journal of Scientific Research* 2009; 2(2): 22-26.
3. Lubkin V, Sloan S. Enucleation and psychic trauma. *Adv Ophthalmic Plast Reconstr Surg* 1990; 8: 259-62.
4. Kumar and Sajjan. Prosthetic management of an ocular defect. *Contemporary clinical dentistry* july-sep 2010; 1(3):201-03.
5. Ashwin N. Aidasani et al, A new method to stabilize iris button during the fabrication of custom made ocular prosthesis – A case report. *National Journal of Medical and Dental Research*, 2013; 1(2):31-33.
6. Satyabodh S. Guttal, Narendra P. Patil, Naina Vernekar, Amit Porwal. A Simple Method of Positioning the Iris Disk on a Custom-Made Ocular Prosthesis. A Clinical Report. *J Prosthodont* 2008; 17: 223–227.
7. Beumer J, Zlotolow I. Restoration of facial defects. In: Beumer J, editor. maxillofacial rehabilitation - prosthodontic and surgical considerations 1st ed. St. Louis: C. V. Mosby publishers; 1996. p. 350-64.
8. Thomas D Taylor: Clinical Maxillofacial Prosthetics, Quintessence: Chicago, 2000; 265-7.
9. Mathew FM, Smith MR, Suttion JA et al. The ocular impression: a review of the literature and presentation of an alternate technique. *J Prosthodont* 2009:210–216.
10. Laney WR and Gardener A F. Maxillofacial prosthetics, 2<sup>nd</sup> edn. Littleton, PSG Publishing, 1979: 279–306.
11. Brown K E. Fabrication of an ocular prosthesis. *J.Prosthetdent*1970; 24:225-235.