

Case Report

Acute appendicitis in pregnancy

Prashant Joshi, Sai Sushma Tella*, Linge Gowda, Maitri and Shilpa M N

Department of Obstetrics & Gynaecology, Adichunchanagiri Institute of Medical Sciences, BG Nagara, Mandya District, Karnataka, India

***Correspondence Info:**

Dr. Sai Sushma Tella,
Department of Obstetrics & Gynaecology,
Adichunchanagiri Institute of Medical Sciences, BG Nagara, Mandya District, Karnataka, India
E-mail: saisushmasweety@gmail.com

Abstract

Acute appendicitis during pregnancy is an important complication that deserves careful consideration. It is perhaps the most common indication for performing a laparotomy for extrauterine lesions. Various anatomic and physiologic changes that occur during pregnancy contribute to the complexity of making the diagnosis of this disorder. The symptoms and signs of acute appendicitis during pregnancy may, however, mimic those commonly encountered in normal non-gravid women. Reports on acute appendicitis in pregnancy are rare. We reported a case of 28 week pregnancy with acute appendicitis that underwent open appendectomy after which she developed preterm labour for which she was put on progesterone supplements and managed successfully.

Key Messages: preterm labour, fetal loss, acute appendicitis with pregnancy

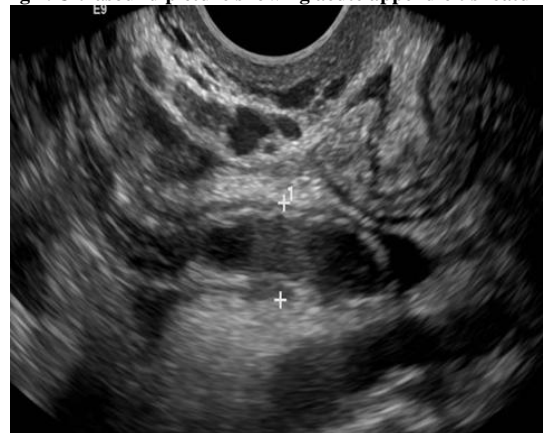
1. Introduction

Acute appendicitis is an infrequent yet the commonest surgical emergency encountered in pregnancy occurring in about 1:1500 pregnancies¹. Incidence was slightly higher in the second trimester than in the first and third trimesters or postpartum². The clinical diagnosis, though not unlike that in the non-pregnant woman, can be difficult particularly with advancing pregnancy. Delay in diagnosis may lead to perforation which carries high morbidity in pregnancy. Mortality in pregnancy ranges from 1-5% depending on the clinical state at the point of diagnosis with perforation and generalized peritonitis carrying the highest rate^{3,4,5}. The diagnosis is particularly challenging during pregnancy because of the relatively high prevalence of abdominal/gastrointestinal discomfort, anatomic changes related to the enlarged uterus, and the physiologic leukocytosis of pregnancy. Appendiceal rupture occurs more frequently in pregnant women, especially in the third trimester, possibly because these challenges and reluctance to operate on pregnant women delay diagnosis and treatment^{6,7}.

2. Case report

A 24 year old lady G2P1L1 with previous normal vaginal delivery 3 years back presented in our OPD with chief complaints of pain in right iliac fossa and bilious vomiting 2-3 times/day since 2 days along with 28 weeks of pregnancy. She had a ultrasound done from outside which showed features of acute appendicitis.

Fig 1. Ultrasound picture showing acute appendicitis features



On general examination patient was conscious and thin built with height 164 cm, weight 58 kg, pallor+, icterus not present, pedal edema present, pulse was 96bpm, blood pressure was 110/70 mm hg, examination of respiratory, cardiovascular system revealed no abnormality.

On per abdominal examination uterus is 28 weeks size, relaxed, deep tenderness above and lateral to MC BURNEY'S point present. On per speculum examination cervix and vagina healthy, minimal white discharge present.

Her clinical diagnosis of acute appendicitis was made, routine investigations including hemogram, urine routine, and serology was normal. No response to conservative treatment.

With diagnosis of G2P1L1 with 28 weeks period of gestation with acute appendicitis patient was taken for open appendectomy under spinal anaesthesia.

Operative findings:- Under spinal anaesthesia, laparotomy was done. Oblique incision centering the point of maximum tenderness. The caecum seen after gently pushing the uterus medially, which was delivered outside. Appendix inflamed, limsy adhesions released, vessels ligated. Appendix removed after ligation at base. The wound was closed in layers. postoperatively metrogl 5 doses and paracetamol 100ml iv sos given.

Fig 2. Removed appendix specimen

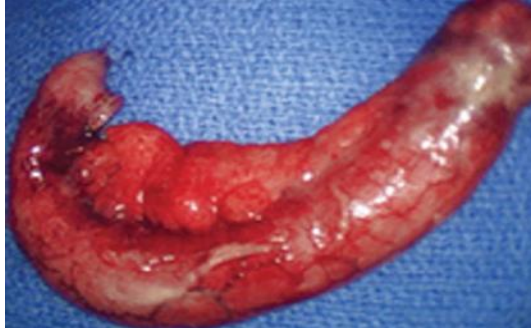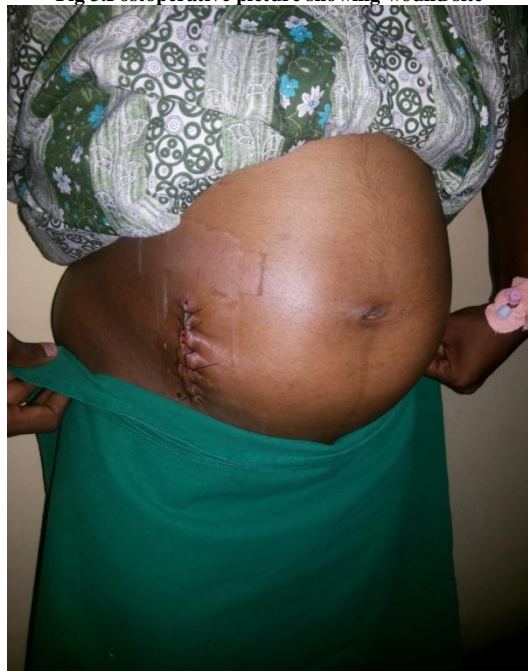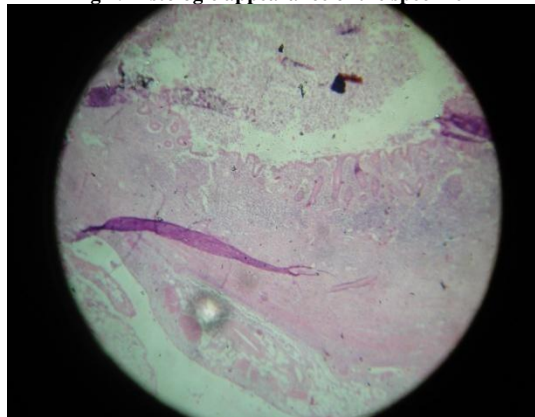


Fig 3. Postoperative picture showing wound site



Histopathology:-report shows mucosa lined by columnar epithelium. Dense infiltration of mucosa, sub mucosa and muscularis propria with acute inflammatory cells like neutrophils seen.

Fig 4. Histologic appearance of the specimen



Her open appendectomy was done. post operatively she had uterine contractions for which she was put on tab. nicardia 20 mg stat followed by 10mg tid and cap.susten bd for 7 days. Stitches were removed on 7th post operative day and she was discharged on 8th post operative day.

3. Discussion

In the "classic" presentation, the patient describes the onset of abdominal pain as the first symptom. The pain is periumbilical initially and then migrates to the right lower quadrant as the inflammatory process progresses⁸⁻¹⁰. Anorexia, nausea and vomiting, if present, follow the onset of pain. Fever up to 101.0°F (38.3°C) and leukocytosis develop later. Many patients have a nonclassical presentation, with symptoms such as heartburn, bowel irregularity, flatulence, malaise, or diarrhea. If the appendix is retrocecal, patients often complain of a dull ache in the right lower quadrant rather than localized tenderness. Rectal or vaginal examination in such patients is more likely to elicit pain than abdominal examination. A pelvic appendix can cause tenderness below McBurney's point. These patients often complain of urinary frequency and dysuria or rectal symptoms, such as tenesmus and diarrhea¹¹.

Pregnant women are less likely to have a classic presentation of appendicitis than nonpregnant women. The most common symptom of appendicitis, ie, right lower quadrant pain, occurs close to McBurney's point in the majority of pregnant women, regardless of the stage of pregnancy^{12,13}; however, the location of the appendix migrates a few centimeters cephalad with the enlarging uterus, so in the third trimester, pain may localize to the mid or even the upper right side of the abdomen^{14,15}. The diagnosis of appendicitis in nonpregnant patients can be difficult, with an accepted false-positive rate of ~15%. In pregnancy the diagnosis is made even more difficult by the growing uterus, which can cause inappropriate delay in making the correct diagnosis, leading to an unacceptable increase in maternal and fetal morbidity and mortality rates. As the pregnant uterus ascends into the abdomen, the appendix is displaced upwards and laterally so that the tip may be close to the right flank in late second trimester. This displacement further presents diagnostic difficulties. Acute pyelonephritis and even surgical causes of right hypochondrial pain will be included in the differential diagnosis. The upward and lateral displacement of the appendix effectively guard the inflamed appendix. Atypical presentation, rarely due to a pelvic appendix, displacement of the appendix by the growing uterus and the pathogenesis favoring ease of spread of infection into the peritoneum contribute to delay in diagnosis and contribute to increased morbidity and mortality to both mother and fetus. Clinical diagnosis remains the common mode. Imaging methods should not be awaited if delay in obtaining the service is anticipated as such delay in surgical intervention may not be wise in pregnancy in view of increased fetal and maternal morbidity and mortality. Fetal loss of 4-6 % and early delivery rates of 10-11% have been reported¹⁶.

Antiquity reliance on history and diagnostic difficulties in eliciting physical signs based on the anatomical displacement of the appendix with increasing gestational age is reiterated. Imaging studies and expertise in interpretation may not be forthcoming in centers with resource limitations and are not among the recommended routine especially when clinical assessment skews to a clear diagnosis of appendicitis. The increased risk of fetal loss and pre-term deliveries after surgery requires adequate counseling and obtaining informed consent for both imaging studies involving radiation and the type of surgical approach proposed for appendectomy. The team approach to management with involvement of obstetricians, pediatricians, surgeons and intensivists is vital. The use of dexamethazone for fetal lung maturity is relevant between 22-36 weeks gestation with facilities for caring of the pre-term baby should the need arise¹⁷.

The surgical incision made at open access surgery if laparotomy is elected for, is determined by the gestational age and ease of access to the appendix. Transverse, midline, McBurney's, and Lanz, etc incisions have been described. By convention, the incision should be such that appendectomy is facilitated together with ability to perform peritoneal toilet in indicated cases with minimal manipulation of the pregnant uterus. Adequate fluid replacement and optimization of electrolytes prior to surgery would reduce metabolic complications. A third generation cephalosporin with metronidazole or clindamycin (first trimester) would be appropriate. Long term antimicrobials are preferably continued till the patient remains afebrile for at least 48 hours after surgery completing about five days of treatment especially when there is a perforated appendix and peritonitis. Use of prophylactic tocolysis for advanced pregnancy is controversial. The general rule of thumb of initiating tocolysis is to ensure adequate time for dexamethazone to act for lung maturity in pre-term fetus and possible transfer for intensive care of the neonate is usually followed only if the clinical situation.

4. Conclusion

Appendicitis is a rare surgical complication and diagnosis can be difficult. Fetal morbidity and mortality are high in presence of perforation and generalized peritonitis. Diagnosis is difficult due to displacement of vermiform appendix along with advancing gestational age. open appendectomy is preferred than laparoscopic surgery especially if a diagnostic procedure was not the initial indication unless results of a large randomized trial favours laparoscopic method. Pain in the right lower quadrant of the abdomen is the most common presenting symptom of appendicitis in pregnancy regardless of gestational age. Fever and leukocytosis are not clear indicators of appendicitis in pregnancy and preterm labor is a problem after appendectomy, but preterm delivery is rare. perioperative antibiotics are given frequently to reduce surgical morbidity.

References

1. Mazze RI & Kallen B. Appendicitis in pregnancy: a Swedish Registry Study of 778 cases. *Obstet Gynecol* 1991; 77:835-840.
2. Andersson RE, Lambe M. Incidence of appendicitis during pregnancy. *Int J Epidemiol* 2001; 30:1281.
3. Liu CD & McFadden DW. Acute Abdomen and appendix In: Greenfield LJ, Mulholland MW, Oldham KT, editors; *Surgery: Scientific Principles and Practice*, 2nd edition Philadelphia: Lippincott, Williams & Wilkins; 1997; pp 1246-61.
4. Tamir IL, Bongard FS & Klien SR. Acute appendicitis in the pregnant patient *Am J Surg* 1990; 160:571-576.
5. Witlin AG & Sibai BM. When a pregnant patient develops appendicitis. *Contemp Obstet Gynecol* 1996; 41:15-30.
6. Bickell NA, Aufses AH Jr, Rojas M, Bodian C. How time affects the risk of rupture in appendicitis. *J Am Coll Surg* 2006; 202:401.
7. Weingold AB. Appendicitis in pregnancy. *Clin Obstet Gynecol* 1983; 26:801
8. Lee SL, Walsh AJ, Ho HS. Computed tomography and ultrasonography do not improve and may delay the diagnosis and treatment of acute appendicitis. *Arch Surg* 2001; 136:556.
9. Birnbaum BA, Wilson SR. Appendicitis at the millennium. *Radiology* 2000; 215:337.
10. Chung CH, Ng CP, Lai KK. Delays by patients, emergency physicians, and surgeons in the management of acute appendicitis: retrospective study. *Hong Kong Med J* 2000; 6:254.
11. Richards C, Daya S. Diagnosis of acute appendicitis in pregnancy. *Can J Surg* 1989; 32:358.
12. Hodjati H, Kazerooni T. Location of the appendix in the gravid patient: a re-evaluation of the established concept. *Int J Gynaecol Obstet* 2003; 81:245.
13. Popkin CA, Lopez PP, Cohn SM, et al. The incision of choice for pregnant women with appendicitis is through McBurney's point. *Am J Surg* 2002; 183: 20.
14. Oto A, Srinivasan PN, Ernst RD, et al. Revisiting MRI for appendix location during pregnancy. *AJR Am J Roentgenol* 2006; 186:883.
15. Pates JA, Avendanio TC, Zaretsky MV et al. The appendix in pregnancy: confirming historical observations with a contemporary modality. *Obstet Gynecol* 2009; 114:805.
16. Mc Gory ML, Zingmond DS, Tillou A et al. *J Am Coll Surg* 2007; 205(4):534-40
17. RCOG Guideline No. 7 Feb.2004 Antenatal Glucocorticoids to prevent Respiratory Distress Syndrome.