

Research Article

Musculocutaneous Nerve absence; a research study in sixty upper limb specimens

Raveendra Patil G T*, Vijaykumar Shinde, Mallikarjun M and Solomon Krupanidhi U.

Department of Anatomy, Vijayanagar Institute of Medical Sciences, Bellary, Karnataka, India.

***Correspondence Info:**

Dr. Raveendra Patil G T
Assistant Professor,
Department of Anatomy,
Vijayanagar Institute of Medical Sciences, Bellary, Karnataka, India.
E-mail: drravi2201@gmail.com

Abstract

Absence of musculocutaneous nerve was observed during study of 60 dissected upper limb specimens. The area of innervation was supplied by median nerve. Knowledge of this anatomical variation is of clinical significance to neurologists, traumatologists and surgeons as injury to median nerve in this case would lead to unexpected paralysis of flexor muscles of arm and hypoaesthesia of lateral surface of forearm.

Keywords: Musculocutaneous nerve, Median nerve

1. Introduction

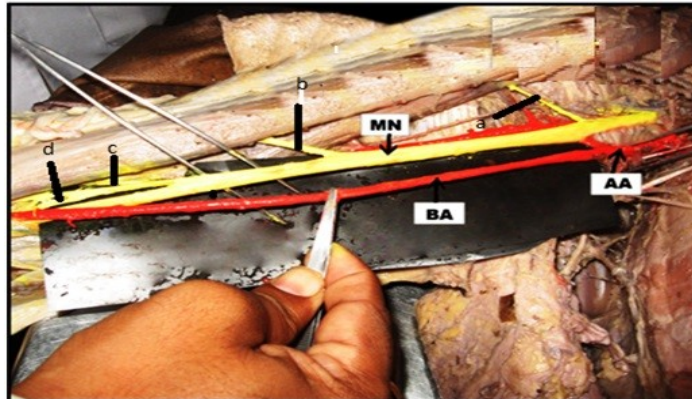
Musculocutaneous Nerve (MCN) is a branch from lateral cord of brachial plexus arising opposite lower border of teres minor. It pierces the coracobrachialis and descends laterally between biceps and brachialis to lateral side of arm. Just above the elbow, it pierces the deep fascia lateral to tendon of biceps, continuing as lateral cutaneous nerve of forearm. It supplies the coracobrachialis, both heads of biceps and brachialis¹.

Median Nerve (MN) has two roots from lateral and medial cords, which embrace the third part of axillary artery, uniting either anterior or lateral to it. MN enters the arm at first lateral to brachial artery, near insertion of coracobrachialis crosses the artery, descends medial to it in the cubital fossa. Here it lies deep to bicipital aponeurosis and anterior to brachialis. It usually enters the forearm between heads of pronator teres¹.

2. Materials and methods

The materials used for this study consisted of 60 upper limbs of 30 human cadavers of either sex and age group between 30-60 years. The study was done over a period of 2 years from August 2010 to July 2012 in the department of Anatomy at Vijayanagar Institute of Medical Sciences (VIMS), Bellary. The study was done by dissection method and observations were made.

Fig 1. Shows absence of musculocutaneous nerve in the right arm.



AA-Axillary artery, BA-Brachial artery, MN-Median nerve, a-branch to coracobrachialis, b-branch to biceps brachii, c-branch to brachialis, d-branch continuing as lateral cutaneous nerve of forearm.

3. Observation and Results

The study included the origin and course of MCN, MN and their relation with the surrounding structures.

A variation of brachial plexus, characterised by the absence of MCN on right arm, was found during the dissection of 55-60 year old male cadaver. MN supplied the muscles of front of arm from its lateral aspect. Branches each to coracobrachialis, biceps and brachialis were given 5.2cms, 14.7cms and 17.6cms from the outer border of first rib respectively. Lateral cutaneous nerve of forearm was given from lateral side of MN just above the elbow. The course and distribution of MN in the forearm did not show any variation. The course and distribution of MCN and MN in the left upper limb of same cadaver was normal.

4. Discussion

Anatomical variation of peripheral nerves constitute a potentially important clinical and surgical issue. There is little data in literature regarding absence of MCN.

In man, forelimb muscles develop from the mesenchyme of paraxial mesoderm during fifth week of intrauterine life². Axons of spinal nerves grow distally to reach the mesenchyme. Significant variations in the nerve patterns may be a result of altered signalling between mesenchymal cells and neuronal growth cones or circulatory factors at the time of fusion of brachial plexus³.

Rao and Chaudhary⁴ observed MCN was absent in two cases (8%) of 24 dissected upper limbs. MN took over the area of supply of MCN by giving both muscular and sensory branches. Hollinshed⁵ (1982) has stated that very occasionally the MCN is not found and its various branches arise from MN. The absence of MCN was also noted by Le Minor⁶ (1990), Nakatani *et al*⁷ (1997), Sud and Sharma⁸ (2000) and Gumusburn⁹ (2000). Beheiry¹⁰ (2004) observed absence of MCN in one limb (1.7%) out of 60 arms dissected in the age group between 30-67 years. The present study coincides with the study done by Beheiry.

Precise knowledge of variation of MCN and MN may be of great value in traumatology of arm, as well as in plastic and reconstructive surgeries.

References

1. Williams PL. Nervous system. In : Berry MM, Standring SM, Bannister SH, editors. Gray's anatomy. 38th ed. Edinburgh : Churchill Livingstone; 1996. p 1266 – 72.
2. Larsen WJ. Development of limbs. 2nd ed. Edinburgh : Churchill Livingstone; 1997. p 311 – 39.
3. Sannes HD, Relh TA, Harris WA. Development of Nervous System. New York : Academic press ; 2000. p 189 – 97.

4. Prasad Rao , Chaudhary SC. Absence of musculocutaneous nerves : two case reports. *Clin Anat* 2001 ; 14 : 31- 5.
5. Hollinshed WH. The back and limbs. Anatomy for surgeons. 3rd ed. Philadelphia : Harper and Row ; 1985. p 797.
6. Le Mnior JM. A rare variant of the median and musculocutaneous nerve in man. *Arch Anat Histol Embryol* 1990 ; 73 : 33 – 42.
7. Nakatani, Tanaka SH. Absence of musculocutaneous nerve with innervation of coracobrachialis, biceps and lateral border of forearm. *J Anat* 1997 ; 191 : 459.
8. Sud M, Sharma A. Absence of musculocutaneous nerve and innervation of coracobrachialis, biceps brachii and brachials from median nerve. *J Anat Soc India* 2000 ; 42 (2) : 176 – 7.
9. Gumusburn E, Adigauzel E. A variation of the brachial plexus characterized by the absence of musculocutaneous nerve – a case report. *Surg Radiol Anat* 2000 ; 22 : 63-5.
10. Beheiry EE. Anatomical variations of the median nerve distribution and communication in the arm. *Folia Morphol (Warsz)* 2004 ; 63 (3) : 313 – 8.