

Case Report

HIV Associated Foix-Chavany-Marie Syndrome

Shobha S Shetty^{*1}, Ivor D'Sa², John Jacob³, Adithi Bhandary³, Paul T Joyes³,
Riya Elizabeth Kuruvilla³ and Bibin P³

¹Associate Professor; Department of General Medicine; K. S. Hegde Medical Academy, Deralakatte, Mangalore

²Professor; Department of General Medicine; K. S. Hegde Medical Academy, Deralakatte, Mangalore

³Junior Resident; Department of General Medicine, K. S. Hegde Medical Academy, Deralakatte, Mangalore

***Correspondence Info:**

Dr. Shobha S Shetty
Associate Professor, Dept. of General Medicine,
K. S. Hegde Medical Academy, Deralakatte, Mangalore, Pin: 575018
E mail: shobhashetty22@gmail.com

Abstract

Foix Chavany Marie Syndrome also known as Opercular syndrome is characterised by loss of voluntary control of facial, pharyngeal, lingual & masticatory muscles with preserved reflexive and automatic emotional functions. It commonly presents as biopercular syndrome although unilateral cases are rarely reported. Its association with HIV is rare and we present a 34 year old HIV affected woman who presented with acute onset of dysarthria and dysphagia. MR Imaging of the brain revealed the characteristic high signal intensities in the left opercular area near the insula. Clinical improvement was documented following antiplatelet therapy.

Keywords: dysarthria, dysphagia, Foix Chavany Marie syndrome, HIV, Opercular syndrome

1. Introduction

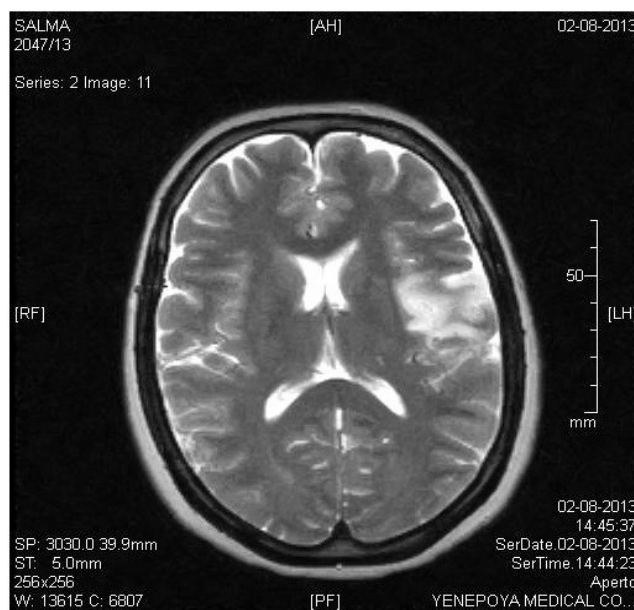
Foix-Chavany-Marie syndrome (FCMS) or the anterior opercular syndrome is characterized by anarthria/dysarthria and loss of voluntary control of facial, pharyngeal, lingual and masticatory muscles with preserved reflexive and automatic emotional functions.¹ It is a rare disorder usually due to bilateral lesions of the opercular cortex surrounding the insula. Magnus first described this syndrome in 1837 as Foix-Chavany-Marie syndrome (FCMS), facio-labio-glossopharyngolaryngo-brachial paralysis or cortical type of pseudobulbar paralysis. Unilateral anterior syndrome is also reported involving frontal operculum presenting with contralateral and upper limb paresis and inability to speak (Piere Marie's anarthria). It differs from bulbar palsy by preservation of jaw jerk, pharyngeal reflex and by the absence of fasciculation, atrophy and phenomenon of denervation and unlike pseudobulbar palsy, emotional lability is not seen.² The syndrome can occur with unilateral lesions resembling multiple cranial nerve palsies.³ We present a case report of a HIV seropositive woman who presented with unilateral anterior Opercular syndrome and contralateral 7th, 9th, 10th & 12th cranial nerve palsies.

2. Case Report

A 34 year old woman presented with history of sudden onset non progressive dysarthria and dysphagia for both for solids and liquids. She was conscious and well oriented cooperative and comprehended all commands but had poor word output. There was no history of fever, headache, loss of consciousness, blurring of vision, diplopia, seizures or weakness of limbs. Her bowel and bladder were normal. She was diagnosed to be HIV affected 5 years prior to the present admission and was on antiretroviral treatment since then. She had no prior history of opportunistic infections but was a hypertensive on medication for 2 years. On examination she was afebrile, normotensive and no respiratory distress. Her higher mental functions were normal, UMN type of right 7th, 9th, 10th and 12th cranial nerve involvement. She was following all

commands, spontaneously smile, yawn, and blink her eyes but was completely mute and aphonic. She had normal muscle power, cranial nerves (except 7, 9, 10 and 12), deep tendon reflexes, sensory examination and gait, flexor plantar response bilaterally & preserved reflexes except gag reflex. The attached figure shows the 7th cranial nerve involvement, other cranial nerves had recovered within 48hrs of treatment. On investigating, her complete blood counts, renal function tests and liver function tests were normal. There was no evidence of dyslipidemia. Her ECG, and echocardiography were normal. MRI Brain showed increased signals in both T1 and T2 weighted images in the opercular area of the left frontal lobe near the insula suggestive of mid MCA territory infarct. She was started on antiplatelet therapy (aspirin 150 mg per day per oral) which was followed by rapid clinical improvements. She was able to swallow liquids, reversal of cranial nerve palsies and return of gag reflex within 72 hours of initiation of therapy. Patient was reviewed after a month on out patient basis and she had near normal speech.

Figure: T2 weighted MRI brain showing an infarct in the left opercular area near the insula signifying the mid MCA territory



3. Discussion

The Foix Chavany Marie syndrome is also known as the opercular syndrome due to its anatomical location. The "operculum of the insula of Reil," is formed by cortical convolutions of frontal, parietal, and temporal lobes. The frontal part of this operculum is preferentially affected in this syndrome. Even a unilateral lesion in one lobe can present with bilateral findings due to the bilateral projections originating from the precentral gyrus to the nuclei of the 5th, 7th, 9th, 10th, and 12th cranial nerves.¹ Sometimes in unilateral opercular lesions, brain SPECT may reveal disturbances on the contralateral side due to diaschisis.²

The clinical features of Foix Chavany Marie Syndrome include anarthria or severe dysarthria, masticatory problems, facial weakness, drooling, dysphagia, a tendency for the mouth to be held half open, weakness of the tongue, absent movement of the palate and decreased or absent gag reflex. They have difficulty in closing the eyes, opening the mouth, protruding the tongue and swallowing. However they may blink, laugh or yawn. There are no features of emotional lability which differentiates this condition from bulbar palsy where there is absence of jaw jerk along with absent gag reflex and subcortical pseudobulbar palsy where there is dysarthria and dysphagia but exaggerated gag reflex. Emotional lability and sphincter disturbances are also a feature of pseudobulbar palsy which is not seen in this syndrome.¹ Seizures are another atypical presentation of this condition but mostly seen in children most of them who are resistant to medical therapy and respond to hemispherectomy.² Nisipaneau *et al*³ described a congenital form of this condition in an elderly gentleman who had worsening dysphagia, dysarthria & facial palsy all his life and MRI showed bilateral opercular lesions. Developmental delay, poor palatal function, hypotonia, arthrogyposis, hemiparesis, apnea, paraparesis, micrognathia, and hearing loss are also other manifestations of this syndrome especially in children.

This etiology in this syndrome is mostly vascular like thrombosis or embolism.⁴ Ischemia is the most common etiology when it occurs bilaterally in the opercular area, but it has been also described in patients with bilateral subcortical lesions.⁵ Cases have also been reported where a glioma has presented with this manifestation & there was complete reversal of symptoms after the removal of the glioma. Other causes are infections of the nervous system like Moyamoya disease, herpes simplex encephalitis or cortical dysplasias, and degenerative diseases.³ Nitta *et al* also demonstrated this syndrome in their patient who had a unilateral anterior opercular contusion.⁶ There has also been a case reported by Grassi *et al* where they showed the reversibility of this syndrome in an AIDS patient with cerebral toxoplasmosis. This was the first case to have been reported of this syndrome in AIDS. The patient completely recovered after treatment for toxoplasmosis and antiedema measures. However the syndrome is likely to recur in AIDS sufferers in whom multifocal cerebral lesions are common.⁷

In the case of a developmental lesion, the pathology has been described as polymicrogyria and perivascular grey-matter heterotropias or disorders of migration. Redondo *et al*⁸ recently published a case report of this syndrome in a 41 year old female who presented with progressive automatic- voluntary motor dissociation of face and lower cranial nerves with later involvement of limbs. She was immunosuppressed as a result of HIV. MRI showed bilateral lesions in opercular areas and ventrolateral thalamic nucleus, likely as a result of retrograde neuronal degeneration. The opercular syndrome is thus a very rare presentation in HIV seropositive patients and should be considered as one of the neurological presentations of the disease. Though it has an acute presentation, early diagnosis and prompt management reduces the recovery time for this condition.

References

1. Yildiz OK, Oztoprak SCI, Bolayir E, Topaktas S. Foix-Chavany-Marie Syndrome due to a unilateral opercular infarction. *Cumhuriyet Med J* 2010;32:251-56.
2. Lekhjung T, Raju P, Rana PVS. Opercular Syndrome: Case reports and review of literature. *Neurology Asia* 2010;15(2):145-52.
3. Gordon N. The opercular syndrome, or the Foix-Chavany-Marie Syndrome. *J R Coll Physicians* 2007;37:103-106.
4. Santos S, Casadevall T, Rios C, Lopez-Garcia E, Tejero C, Garces-Redondo M *et al*. Opercular syndrome of vascular aetiology. *Rev Neurol* 2002;34(12):1129-32.
5. Giraldo-Chica MM, Ramirez JD, Uribe C, Lopera F. Biopercular syndrome caused by unilateral ischemia. Report of one case. *Rev Med Chil* 2010;138(3):341-45.
6. Nitta N, Shiino A, Sakaue Y, Nozaki K. Foix-Chavany-Marie Syndrome after unilateral anterior opercular contusion: A case report. *Clin Neurol Neurosurg* 2013;115(8):1539-41.
7. Grassi MP, Borella M, Clerici F, Perin C, Bini MT, Mangoni A. Reversible bilateral Opercular Syndrome secondary to AIDS- associated cerebral toxoplasmosis. *Ital J Neurol Sci* 1994;15(2):115-7.
8. Redondo L, Mir J, Perez de Leon JA, Duran E, Viguera J, Galvez J *et al*. HIV related Foix-Chavany-Marie Syndrome. *Neurologia* 2003;18(10):741-45.