

Research Article

Percutaneous vertebroplasty, results and technical problems with the use of a Cost effective Technique

Janardhana Aithala P*

Associate Professor, Department of Orthopedics, Kasturba Medical College, Manipal University, Manipal, India.

***Correspondence Info:**

Dr. Janardhana Aithala P,
Associate Professor,
Department of Orthopedics,
KMC Hospital, Attavar, Mangalore, 575001, India
Email id: janardanaaithala@yahoo.com

Abstract

Osteoporotic vertebral compression fractures are a common problem in elderly. Although most of them heal by conservative management, some may lead to severe pain and disability. Percutaneous vertebroplasty has been effective in relieving pain in these patients with very few complications. However, the present vertebroplasty kits marketed are expensive and are a burden to our society. Hence we devised a new technique with the help of Jamshedi needle, regular bone cement (Depuy) used in routine arthroplasty and barium sulfate. Our aim of the study was to understand the technical problems associated with the use of this technique and to know whether we can safely inject sufficient amount of cement into vertebral body so as patient gets good immediate pain relief. The main concern with this technique were early setting of cement, thus reducing the available working time and poor visibility. We treated 32 patients with 47 level vertebroplasties. Mean VAS was reduced from 8.65 to 3.23, 30 patients were mobilized on the same or next day and remain pain free at the end of one year. There were 6 cases of cement leak into adjacent disc space, or anteriorly or into canal, but none had any significant impact on outcome. Regarding technical problems, one patient developed transient deficit, in one patient we had to waste one packet of cement, and in one patient visibility was poor. We conclude that our procedure is a safe procedure, and highly cost effective, while with some technical adjustments, one can work within the available time and inject significant cement into vertebral body.

Keywords: Osteoporosis, vertebral body fractures, vertebroplasty, bone cement

1. Introduction

Osteoporotic vertebral compression fractures are a common and significant public health problem^{1,2}. Vertebroplasty is a popular procedure and is very much useful in pain relief in osteoporotic fractures with pseudoarthrosis, multiple myeloma with fractures and in certain tumors². Although there are concerns regarding its long term safety and also regarding adjacent vertebral fractures in long run, it remains unclear whether subsequent fractures are related to natural progression of osteoporosis^{3,4}. The procedure helps to relieve the pain in elderly patients immediately and improves mobility of the person^{3,4} which is very much essential in elderly people. However in Indian patients, main problem with procedure is affordability. Vertebroplasty procedure along with standard vertebroplasty kit costs 30 to 40,000 rupees. So majority of people who belong to poor and middle class may not afford this. Further, an elderly person can sustain another fracture due to osteoporosis⁵ and may require subsequent repetition of procedures to maintain pain free and disability free status. So in Indian context it was essential to find a low cost vertebroplasty technique which will be cheaper, equally

effective without any additional complications.

We thought that the major cost of treatment is spent on vertebroplasty kit itself. This kit includes a specialized needle set and low viscosity cement mixed with barium sulfate. We thought that only way to reduce the cost was to find out whether we can bring down this cost. The regular standard bone cement is available at a lesser price while, we thought we can use simple Jamshedi needles which are available at a lesser price, we also did not use any special device to inject the cement, but used multiple 2 cc syringes filled with cement to inject into the needle and then to vertebral body. This method was economical and many people could undergo the procedure. The use of regular bone cement is not new and vertebroplasty was initially evolved using regular bone cement (Depuy), but later to have a longer working time and better visibility newer vertebroplasty specific cements were developed⁴. Although these cements became more surgeon friendly, they came with extra cost. Whether the technical advantages of these specialized kits with specific cements over regular cement merit the extra cost is not answered by any study. Our aim of the study was to know, whether we can perform vertebroplasty with our economical technique using regular bone cement in an effective way by evolving some of technical adjustments to overcome shortcomings related to early setting and whether we can inject sufficient amount of bone cement with our simple device safely so that strength and stiffness of vertebral body is restored and patient gets good immediate pain relief.

2. Materials and Methods

We included patients with osteoporotic fractures with pain over several days and also patients with pathological vertebral fractures due to multiple myeloma or secondaries. Patients who developed other major fractures other than spine and patients with lumbar canal stenosis with significant disability were excluded from final analysis. In osteoporotic fractures either an MRI or standing and sitting radiographs were used to confirm the pseudoarthrosis, all patients with more than one level vertebral body fractures underwent MRI and subsequently biopsy unless diagnosis was already established as in the case of multiple myeloma or secondaries.. MRI evidence of cleft formation, edema were taken as features of pseudoarthrosis, while those with healed lesions were not included. All patients underwent procedure under sedation and local anesthesia. Patients were positioned prone, and image intensifier was used to confirm the levels before proceeding. For thoracic spine fractures transpedicular approach² (bilateral) was used, while for lumbar spine lateral (unilateral extrapedicular⁶ from left side) was used. An 11 number 4 and half inch long Jamshedi needle was inserted into vertebral body as per standard techniques^{6,7} and needle placement was confirmed with image intensifier.

In lumbar spine, with extrapedicular approach, needle was advanced till the opposite side of vertebral body (right side) in AP plane and anterior half of vertebral body in lateral projection, preoperative assessment of pseudoarthrosis and edema seen in MRI will give accurate guide for needle placement. We believe this is an advantage with extrapedicular approach as one gets a better leverage to advance the needle tip to the desired part of vertebral body unlike in transpedicular approach. In majority of osteoporotic fractures a biopsy was also taken before injecting the cement. Next, regular standard bone cement was taken (Depuy CMW gentamycin 1, 20 gm) and cement contents were poured into a bowl. A drop of barium sulfate was added to cement. Cement was mixed with solution and mixed for a period of 2-3 minutes and then quickly loaded into 2 cc syringes with the help of nursing assistant. For one pack of cement one can fill 4-5 2 cc syringes. Next, needle was stabilized by an assistant and cement was injected from 2 cc syringes. As the cement goes into vertebral body cement placement was confirmed with image intensifier for venous filling⁷. Usually after injecting about 1 ml, both AP and lateral views checked and then image intensifier was kept in the lateral position. If there was venous filling, needle tract was slightly changed and then after minute cement was reinjected. Depending on the progress about 3 to 4 ml of cement of injected and as cement is being injected needle was slightly withdrawn but not behind the junction of anterior and posterior half of vertebral body. The Needle was withdrawn only after cement is well set. Patient was mobilized in the same day.

Preoperative patient assessment included, preoperative patient characteristics, preoperative visual analogue score (VAS), Mobility status, Level of vertebral fractures. During the procedure, we recorded number of levels to which cement was injected, approach, amount of cement injected (using number of 2 cc syringes used), technical difficulties during cement injection. Post operatively patient was subsequently assessed for pain relief using VAS. Radiographic assessment was done for placement of cement and any extrusion of cement. The technical difficulties and complications of the procedure were analyzed to know whether there were any difficulties or complications due to use of regular bone cement instead of low viscosity cement. Also all patients were evaluated at the end of one year for pain relief with VAS, mobility status and complications.

3. Results

A total of 32 patients with 47 level vertebroplasties (34 sittings as two patients underwent procedure twice for different fractures) were done from 2006 to 2010. 27 patients had osteoporotic fractures (Biopsy report was available in 21 patients, remaining 6 patients had single level and combination of conventional radiograph and MRI was used for diagnosis), while 4 patients had multiple myeloma (confirmed by bone marrow study) and one patient had multiple skeletal secondaries (with already established GT tract malignancy). 18 patients had single level while 14 patients had 2 or more level vertebroplasties (one patient had single level each time twice, and another patient single level once and two level second time). The age of patients was ranging from 45 years to 82 years with mean age of 70.29. 19 patients were females. D12 was the commonest, with 20 patients having D12 level. Table No. 1 gives distribution of levels of fractures.

Table No. 1: showing distribution of levels of fractures

Level	Number of patients
D9	1
D10	3
D11	2
D12	20
L1	8
L2	5
L3	4
L4	3
S1	1
Total	47 levels (1 patient 4 level, 2 patient 3 level, 11 patients 2 level)

The mean time duration from the date of pain onset to the procedure was 37.4 days. MRI was taken in 25 patients with osteoporotic fractures which clearly showed features like edema, fluid collection or pseudoarthrosis (cleft formation) while in 2 patients who had single level fractures, clinical criteria supported by standing and supine x-ray demonstrating pseudoarthrosis was used. Patients who were diagnosed as Multiple myeloma by bone marrow studies did not have MRI.

All patients had severe pain with Preprocedure mean VAS score of 8.82.

3.1 Approach

Out of 47level vertebroplasties 35 levels were done with left lateral (extrapedicular) approach. These levels were from D12 downwards. In 12 levels which were D12 or above bilateral transpedicular approach was used. Total amount of cement injected varied from 1 ml to 5 ml. All patients were made to walk in the same day except three patients; one had transient L2, L3 weakness, and other patient had multiple myeloma and was able to walk after 4weeks following multiple myeloma treatment, third patient was terminally ill due to skeletal secondaries and procedure was done only for pain relief. Thus out of these 3 patients 2 patients subsequently walked and are doing fine. The average VAS score at the end of one week was 3.23.

At the end of one year, except 3 patients all patients are walking without support. One patient had developed fracture of neck of femur and after surgery is able to walk with walker, other patient has lumbar canal stenosis with deficits, and needs a support to walk and the third patient had frank deficits due to secondaries, procedure was done only for pain relief, patient was lost for follow up after 2 months. These three patients were excluded from pain assessment. In the subsequent follow up, 6 patients could not attend follow up at hospital and hence could not get an x ray, but walking ability and VAS was assessed telephonically. Mean VAS at the end of one year were 2.36. Two patients developed fresh onset of backache in subsequent visits, both due to new fractures, one was treated with vertebroplasty and other patient conservatively and both showed good pain relief. One patient with multiple myeloma has severe pain which was later subsided by chemotherapy although she still has some pain. Check x ray was available for 25 patients at the end of one year

and this does not show any additional collapse, while there were two patients with additional fractures.

3.2 Complications

There was cement extrusion into disc space and paraspinal area in 6 patients but patient has no symptoms related to the same. One patient had transient weakness recovered in 6 weeks, one patient had burning pain along L4 subsided in 2 hrs. In the long term at the end of 1 year, there was no additional cement extrusion, there were 2 fresh osteoporotic fractures in the adjacent areas, and one patient was treated with vertebroplasty of additional level, while other patient was treated conservatively and showed good pain relief. The check x-ray at one year (available in 25 patients) does not show further loss of height compared to immediate vertebroplasty films.

Amount of cement injected and Complications specific to our technique: While we did not measure the exact amount of cement injected (which we believe is not essential also), we made a rough estimate of cement injected based on the number of filled 2 cc syringes. In case of thoracic spine, about 2- 3ml of cement was injected through each pedicle one after another. In lumbar spine wherever possible up to 5 ml of cement was injected. In most cases, if it is a single level there was sufficient time to inject three 2cc syringes while in two levels, we could inject two syringes through each needle. After that it will be difficult as cement hardens faster. So when there are more than 2 needles inserted into vertebral body, we split bone cement into two parts and then mixed separately. In patients with three or more levels we used two packets of cement. In One patient there was one packet cement loss due to loss of time and due to quick setting of ordinary cement. Visibility was poor in one patient due to probably less barium sulfate. In one patient needle was bent due to hard healed bone around the cavity of pseudoarthrosis, and one more needle was used. There were no cardiopulmonary complications. At the end of one year also, cement remains in place with no additional collapse.

4. Discussion

Vertebroplasty is a standard procedure nowadays for pain relief in elderly patients for osteoporotic fractures with persistent pain, multiple myeloma with fractures and a small group of people with skeletal secondaries involving vertebral bodies^{2,3,4,7}. It has been proved that vertebroplasty relieves pain in patients who fail to respond to conservative treatment, while it can give immediate pain relief with improved function even in acute fractures when compared to conservative treatment⁸. In our country, cost is the major factor limiting its use in common man. Our procedure along with cement and needle will cost 25% of standard vertebroplasty kit. While we never had any problem regarding the use of regular jamshedi needle as it was used since many years for bone biopsy there were concerns regarding the type of cement we have used.

The standard vertebroplasty kit available contains specialized high viscosity cement with additives to improve the visibility. Main advantage of this cement is better visibility due to addition of barium sulfate by manufacturer as well as high viscosity which gives long setting time and thereby giving extra working time. This long working time is mainly because of higher monomer to polymer ratio. However one should understand that this long working time comes with a price as well as reduced strength of the cement. Belkoff et al⁹, found that altered bone cements did not augment vertebral body strength to the level achieved by the regular bone cement, but good enough to bring the vertebral body strengths to initial levels. While the standard formulations contain 10% barium sulfate, altered combinations have 30%, and higher monomer to powder ratio making it more viscous. These cements are used routinely because they give extra working time and easy to introduce. However there are no major studies regarding the advantages or disadvantages of using such altered cements. Belkoff et al⁹ did an *ex vivo* study and opined that vertebral body strengths is restored in all types of cement, but not stiffness and advice further clinical evaluation. Hence we believe, although these altered cements provide the luxury of good working time to surgeon, it also comes with a price, that is both financial as they are expensive and also reduced strength and stiffness although it may not be clinically significant.

Barr et al² in their technique used regular PMMA cement and mixed with 5.0 gm barium sulfate and 2.0gm tungsten powder for improve visibility. We had excellent visibility with addition of just 1 to 2 drops of barium sulfate readily available in radiology department which does not cost extra. Regarding working time, we can achieve increased working time by two simple methods. One, we can keep the cement in refrigerator which will increase the working time by a few minutes, other since we do not need entire packet of cement, one can leave out some amount of cement while taking complete liquid which will achieve higher monomer-polymer ratio. By this way we can achieve higher working time even with regular arthroplasty cement used (Depuy) while reducing the cost to a great extent. Our working time was between 5-6 minutes after which it is difficult to inject the cement from syringe. If we consider 2 minutes of preparation time we had 3-4 minutes to load in 2 cc syringes and then inject the cement. In single level this time was sufficient for us except one patient.

In one patient (during the initial periods) we had to discard one packet of cement and use another kit but, despite this, expenses were cheaper. In two levels, we used to divide the cement into two and then mix one part with half of liquid and then finish one level and then only go to other level. In one patient we used 2 separate cement packets for 2 levels. With this technique, we could easily inject up to 5ml cement in single levels, while 2-4 ml in two levels. We have done 4 levels with just two packets (Figure 1). The other concern with our procedure is the amount of cement injected. As mentioned earlier, we have succeeded in injecting 3 syringes for single needle technique, while 4 syringes of 2 ml each when it was more than one level, with this, we can safely inject 4ml each for 2 levels with a single cement mixing which is more than sufficient. We believe even a 2-3cc cement is sufficient. Michael AK et al¹⁰ opine that small amount of bone cement is needed to restore stiffness to predamage levels and greater and eccentric filling can lead to single sided load transfer and thus toggle and hence biomechanically not good configurations. Marc et al¹¹ calculated the amount of cement required for each level based on gender and amount of fracture and opine that 24% of vertebral body volume before surgery could be ideal. In most of our cases amount of cement injected depended on the size of pseudoarthrotic cavity and volume available within cavity and nothing to do with type of cement. Figure 2 shows a case of vertebroplasty of 2 levels showing good amount of cement in both the levels.

Figure 1. Needle placement for 4 level vertebroplasty

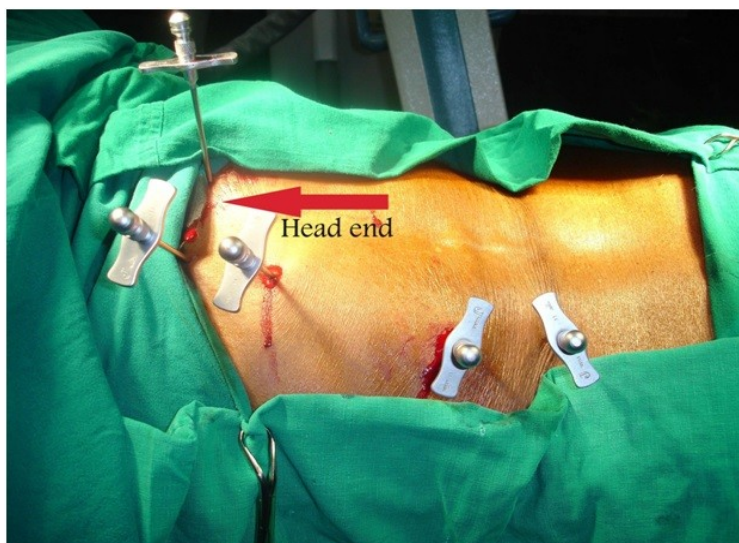
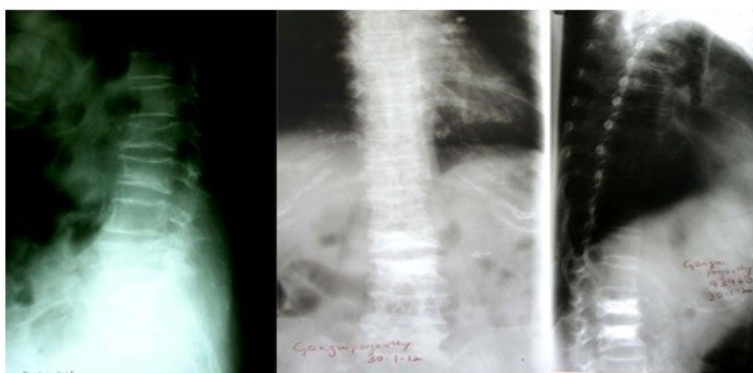


Figure 2. Shows preoperative and Post-operative images of 2 level vertebroplasty



So the only problem with this technique is working time. It is possible to work within available time with experience and in the beginning one may have to waste one or two packets of cement extra. In other words, we could inject four syringes (2cc) with a single setting, sometimes, after injecting through each needle stilllet is used to push the cement into vertebral body thereby pushing some extra cement into body. A well trained assistant or scrub nurse will help in saving lot of time, by helping to load cement into syringes, and also help in putting the stilllet quickly and take out and introduce

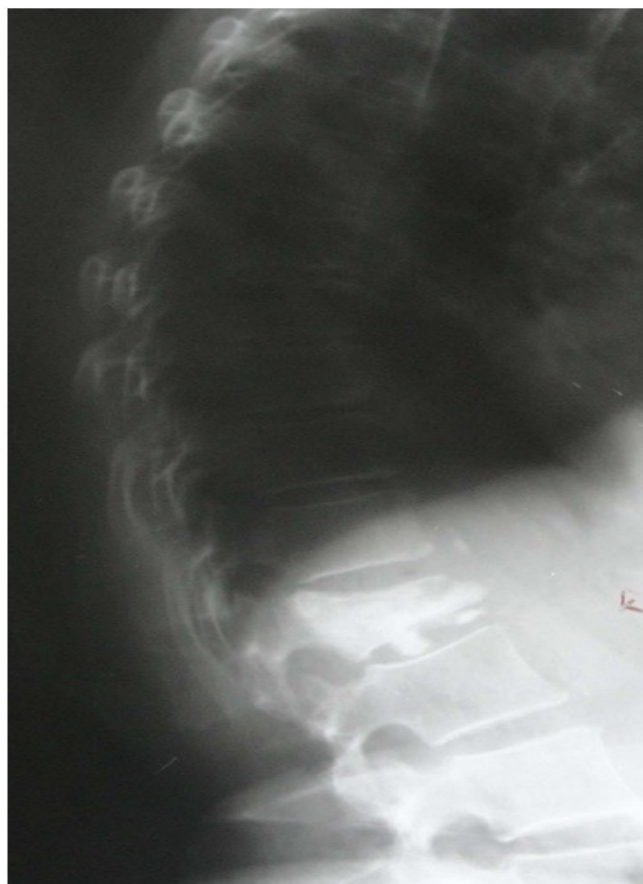
cement with one more syringe.

Our complications were very few and most of them have been described with the use of regular vertebroplasty specific kit also. We had transient neurological weakness in one patient which may be due to wrong direction of needle and not due to the type of cement we have used. There were cement extrusions in 6 patients. In literature, there were reports of extravasation of vertebroplasty cement to the extent of 65%³. Neil³ in their instructional course lecture opines that such leaks are insignificant in most of studies. Ryu et al¹² reported 26.5% leakage into epidural space, they found a correlation between amounts of cement injected and leak rates. It has been suggested that pressurized systems used for cement injection also are responsible for cement leak¹³.

We believe use of 2cc syringes does not create that much pressure that regular pressurizer systems create and also low viscosity cement we use has the distinct advantage in reducing the leaks.¹⁴ These leaks were seen in patients who underwent vertebroplasty slightly early in their course and may be probably due to breaks in the vertebral endplate and body. As per Yeom et al¹⁵ classification, most of our leaks are cortical type, except one patient which showed venous filling. In two cases, cement leaks were probably due to biopsy needle tract, as when second time needle was inserted in, the needle went slightly in a different direction. It is also important to note that in multiple myeloma patients where biopsy was not done we did not have single leaks. However, we routinely do biopsy unless diagnosis is already established (as in the case of multiple myeloma), as biopsy is safe and can pick up unsuspected malignancy¹⁶.

Theoretically, our extrapedicular approach also helps to prevent the leakage into epidural space. However, even when we adopted transpedicular approach there were no leaks into epidural space.

Figure 3. Cement leak into disc space



In terms of achieving our objective of pain relief, all patients had good pain relief compared to preoperative VAS

score. All patients were mobilized same day except 3 patients. At the end of one year also there is no further collapse. There are additional fractures in 2 patients and these findings are noticed in other studies also and there is still doubt whether they are due to vertebroplasty or due to natural pathological progression of osteoporosis.

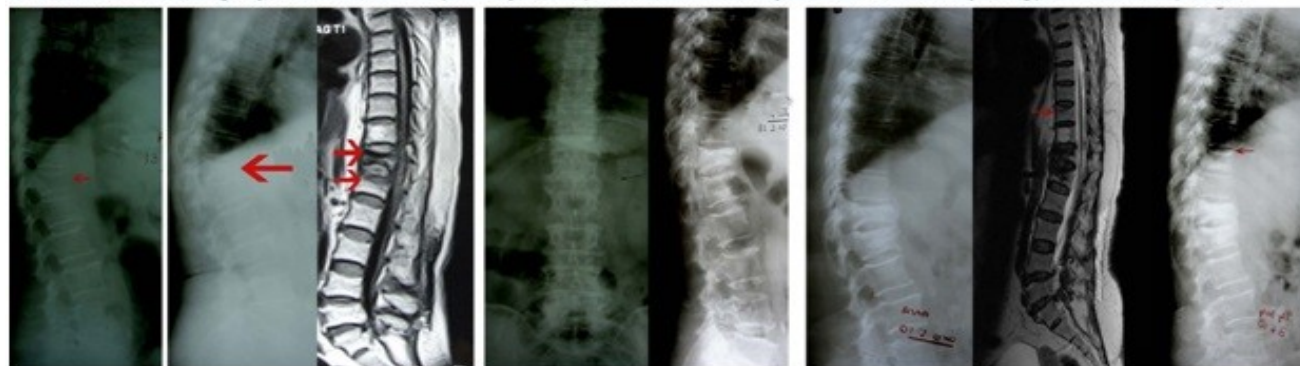While advantages and disadvantages of percutaneous vertebroplasty are already described in literature we would like to discuss mainly on the type of cement we have used. While the special low viscosity cement specifically made for vertebroplasty are being used in many centres, these types of cements do not have still FDA approval and are expensive. One of the main advantages of vertebroplasty cement is long working time due to low viscosity, but this could be at the cost of stability of cement polymer. Stephen M Belkoff et al⁹ opine that alterations to regular bone cement are done to increase the working time as well as to make it radio opaque. Consequently some amount of strength and stiffness is lost due to reduced viscosity, although this may not be clinically significant.

Restoration of height: it is a known fact that vertebroplasty is insufficient to restore height, but we observed two factors. When there was a loss of height in standing x-ray, some amount of height was restored during prone position, and same height was maintained after vertebroplasty. We also noticed that some patients who were treated conservatively lost significant height leading to kyphosis following treatment although fractures were healed. On the contrary patients who underwent vertebroplasty although did not regain complete height, some vertebral body height was preserved (Fig.4). Since we have not exactly measured the loss of height in conservative group versus operative group we need further studies to verify these observations. Recently there is interest in performing occult vertebral fractures¹⁷, early vertebroplasty in such fractures may prevent further loss of height.

Selection of patients and planning is also important for vertebroplasty as majority of patients heal without conservative treatment. Clinical evidence of severe pain not subsiding for 6 weeks is the most important factor⁷. Although there are various investigations described to identify the patients who are likely to benefit from this procedure, it is still controversial. MRI evidence of edema, Bone scans and CT scan are all recommended. However MRI seems to be the most important investigation which will rule out suspicion of malignancies, provide clue to presence of intra osseous cleft formation leading to pseudoarthrosis and pain. Presence of fluid in MRI is very good finding and it indicates pseudoarthrosis with cavity and resultant instability. A lot has been described about intraosseous cleft formation being the reason for instability and pain¹⁸. Presence of Oedema in MRI indicates good prognosis following vertebroplasty¹⁹. In some cases impending fractures will reveal a thin line of altered signal intensity and these fractures are not seen in x-ray and may lead to further collapse (Figure 4). A typical patient is the one with clinical presentation of osteoporotic fracture with severe pain but x ray shows no fracture. In one of our cases we found later that such fracture will progressively collapse (Figure 5). Thao Pham et al¹⁷, have described these as occult osteoporotic vertebral fractures. Vertebroplasty has also been described in acute and subacute vertebral fractures by Rikke Rousing et al⁸. So now we do early MRI and proceed with Vertebroplasty to relieve pain and maintain height in such patients. In our few earlier cases with single level fractures, we have also used standing and supine x-rays to identify pseudoarthrosis. (Figure 6).

Figure 4. Showing series of images in a patient who underwent vertebroplasty twice.

Series of images showing 2 level vertebroplasty done initially, developed another fracture 6 months later and treated with repeat vertebroplasty. One can see two features here. a) Some amount of height can be restored from the standing x ray, this can be assessed with prone x-ray on table. b) Occult fractures without x-ray deformation of vertebral body causing pain can benefit from procedure.



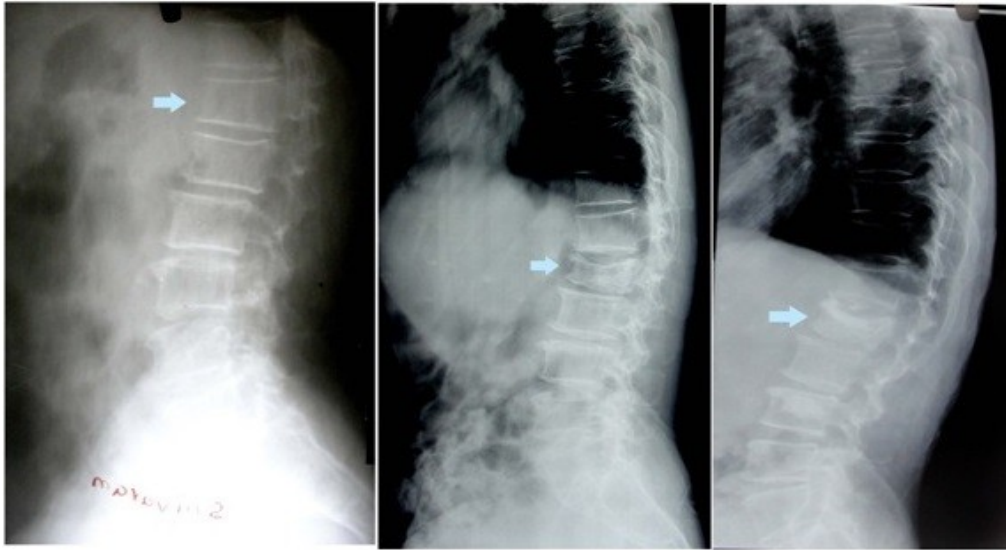
Initial Radiograph shows mild wedging D12

2 months later, pain worsens and standing x-ray shows gross collapse of D12, MR shows additional signal changes in L1

D12 and L1 vertebroplasty done, showing AP and lateral views, note some amount of D12 height is regained.

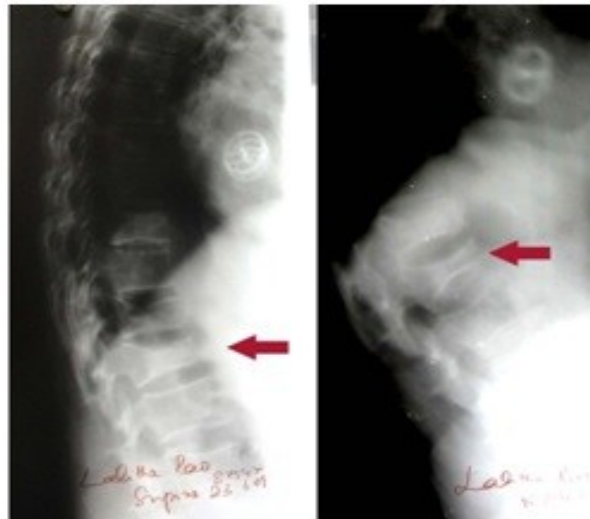Pain recurs after 6 months, although x-ray does not show vertebral body deformation, MR reveals signal changes in D10, vertebroplasty done and patient gets good relief.

Figure 5. Showing how there will be progressive collapse at a later date



70 year old male with sudden onset of backache, shows mild minimal anterior wedging, but shows collapse after 3 weeks, vertebroplasty done to fill the cleft, relieving pain, but height is not restored.

Figure 6. Supine and standing x-rays showing pseudoarthrosis.



5. Conclusions

While vertebroplasty offers good pain relief it is possible to do this procedure using regular bone biopsy needle and regular bone cement there by reducing cost while there are no significant technical difficulties or complications due to this procedure and produces very good pain relief.

References

1. Cohen LD. Fractures of the osteoporotic spine. *Orthop Clin North Am* 1990;21:143–50.
2. John D Barr, Michelle S. Barr, Thomas J Lemley, and Richard M McCann Percutaneous vertebroplasty for Pain Relief and spinal stabilization. *Spine* 2000; 25 (8): 923-28.
3. Neil A Manson and Frank M. Philips, Minimally invasive techniques for the treatment of osteoporotic vertebral

- fractures. *JBJS (Am)* 2006; 88:1862-1872,.
4. Alvarez L, Alcaraz M, Pérez-Higueras A, Granizo JJ, de Miguel I, Rossi RE, Quiñones D. percutaneous vertebroplasty: functional improvement in patients with osteoporotic compression fractures. *Spine (Phila Pa 1976)*. 2006; 1;31(10):1113-8.
 5. Carolyn M. Klotzbuecher, Philip D. Ross, Pamela B. Landsman, Thomas A. Abbott III, and Marc Berger Patients with Prior Fractures Have an Increased Risk of Future Fractures: A Summary of the Literature and Statistical Synthesis. *Journal of Bone and Mineral Research* 2000; 15 (4): 721-39.
 6. Ann K. Kim, BS Mary E. Jensen, Jacques E. Dion, Patricia A. Schweickert, Timothy J. Kaufmann, David F. Kallmes, Unilateral Transpedicular Percutaneous vertebroplasty. *Radiology* 2002; 222 (3): 737-741.
 7. Kallmes DF, Jensen ME. Percutaneous vertebroplasty. *Radiology*. 2003;229(1):27-36.
 8. Rikke Rousing, Karina L. Hansen, Mikkel O. Andersen, Stig M. Jespersen, Karsten Thomsen, and Jens M. Lauritsen, Twelve-Months Follow-up in Forty-Nine Patients With Acute/Semiacute Osteoporotic Vertebral Fractures Treated Conservatively or With Percutaneous Vertebroplasty A Clinical Randomized Study. *Spine* 2010; 35 (5); 478–482.
 9. Stephen M Belkoff, John Mathis, Lois E Jasper BS, and Herve Deramond. An *ex vivo* Biomechanical Evaluation of a hydroxyapatite cement for use with vertebroplasty. *2001 Spine*,; 26, (14), 1542-1546.
 10. Michael AK Liebschner, William S Rosenberg, and Tony M Keaveny. Effects of Bone cement Volume and Distribution on Vertebral stiffness after vertebroplasty. *Spine* 2001; 26 (14); 1547-53.
 11. Marc J. Nieuwenhuijse, Laurens Bollen, Arian R. Van Erkel and P. D. S. Dijkstra, Optimal Intravertebral Cement Volume in Percutaneous Vertebroplasty for Painful Osteoporotic Vertebral Compression Fractures. *Spine* 37 (20): 1747–1755.
 12. Ryu KS, Park Ck, Kim Mc, Kang JK, Dose dependent epidural leakage of polymethylmethacrylate after percutaneous vertebroplasty in patients with osteoporotic vertebral compression fractures. *J Neurosurg*. 2002; 96 (1 suppl) 56-61.
 13. AebliN, Krebs J, Davis G, Walton M, Williams MJ, Theis JC. Fat embolism and acute hypotension during vertebroplasty. An experimental study in sheep, *Spine* 2002; 27: 2173-79.
 14. Groen RJ, Du Toit DF Philips FM, Hoogland PV, Kuizenga K, Coppes MH, Muller CJ, Grobbelaar M, Mattysen J, Anatomical and pathological considerations in percutaneous vertebroplasty and kyphoplasty: a reappraisal of the vertebral venous system. *Spine* 2004: 29-1,1465-71.
 15. Yeom JS, Kim WJ, Choy WS, et al. Leakage of cement in percutaneous transpedicular vertebroplasty for painful osteoporotic compression fractures. *J Bone Joint Surg Br* 2003; 85: 83 – 9.
 16. Sander Paul Jan Muijs, Paul A. Akkermans, Arian R. Van Erkel and Sander D. Dijkstra, The value of routinely performing a bone biopsy during percutaneous vertebroplasty in treatment of osteoporotic vertebral compression fractures. *Spine* 2009; 34 (22): 2395–2399.
 17. Thao Pham, Johanna Azulay-Parrado, Pierre Champsaur, Christophe Chagnaud, Virginie Legre, and Pierre Lafforgue. Occult osteoporotic vertebral fractures, vertebral body fractures without radiologic collapse. *Spine* 2005; 30 (21): 2430-2435.
 18. Wei-Che Lin, Hsiu-Ling Chen, Cheng-Hsien Lu, Hung-Chen Wang, Re-Wen Wu, Yu-Fan Cheng and Chun-Chung Lui, MD. Dynamic Contrast-Enhanced Magnetic Resonance Imaging for evaluating Intraosseous cleft formation in patients with osteoporotic vertebral compression fractures before vertebroplasty. *Spine* 2011; 36 (15) 1244-1250.
 19. Noboru Tanigawa, Atsushi Komemushi, Shuji Kariya, Hiroyuki Kojima, Yuzo Shomura, Koshi Ikeda, Naoto Omura, Takamichi Murakami, Satoshi Sawada, Percutaneous Vertebroplasty: Relationship between Vertebral Body Bone Marrow Edema Pattern on MR Images and Initial Clinical Response; *Radiology*: Volume 2006; 239:(1): 195-200