

## Case Report

### **A rare case of retroperitoneal leiomyosarcoma with gastrointestinal stromal tumour of rectum**

**Shashirekha C.A\*., Nagaraj K.N., Vijay P Agrawal, Harendrakumar N**

*Dept. of General Surgery, Sri Devaraj Urs Medical College, Tamaka, Kolar-563101, Karnataka, India*

#### **\*Correspondence Info:**

Dr. Shashirekha C.A  
Assistant Professor,  
Dept. of General Surgery,  
Sri Devaraj Urs Medical College, Tamaka, Kolar-563101, Karnataka, India  
E-mail- [drca\\_shashirekha@yahoo.co.in](mailto:drca_shashirekha@yahoo.co.in)

#### **Abstract**

Leiomyosarcoma is a rare malignancy of smooth muscle. Leiomyosarcoma may arise from the retroperitoneum and present with nonspecific signs and symptoms. The most common presentation is abdominal pain. In the past gastrointestinal stromal tumour (GIST) were misdiagnosed as leiomyosarcoma. GISTs however have been shown to lack features of smooth muscle tumors on histopathology. They are often CD34 and CD 117 immunoreactive in contrast to leiomyosarcoma. We present a rare case of retroperitoneal leiomyosarcoma with gastrointestinal stromal tumour of rectum in the same patient.

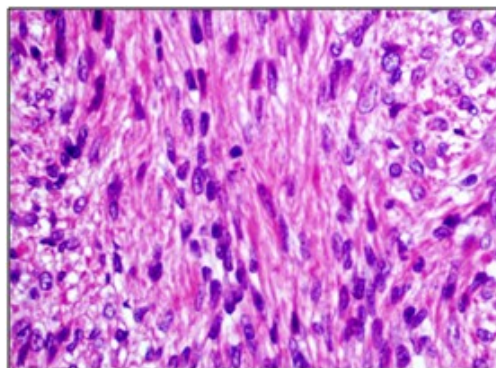
**Keywords:** Leiomyosarcoma, retroperitoneum, gastrointestinal stromal tumour

#### **1. Case study**

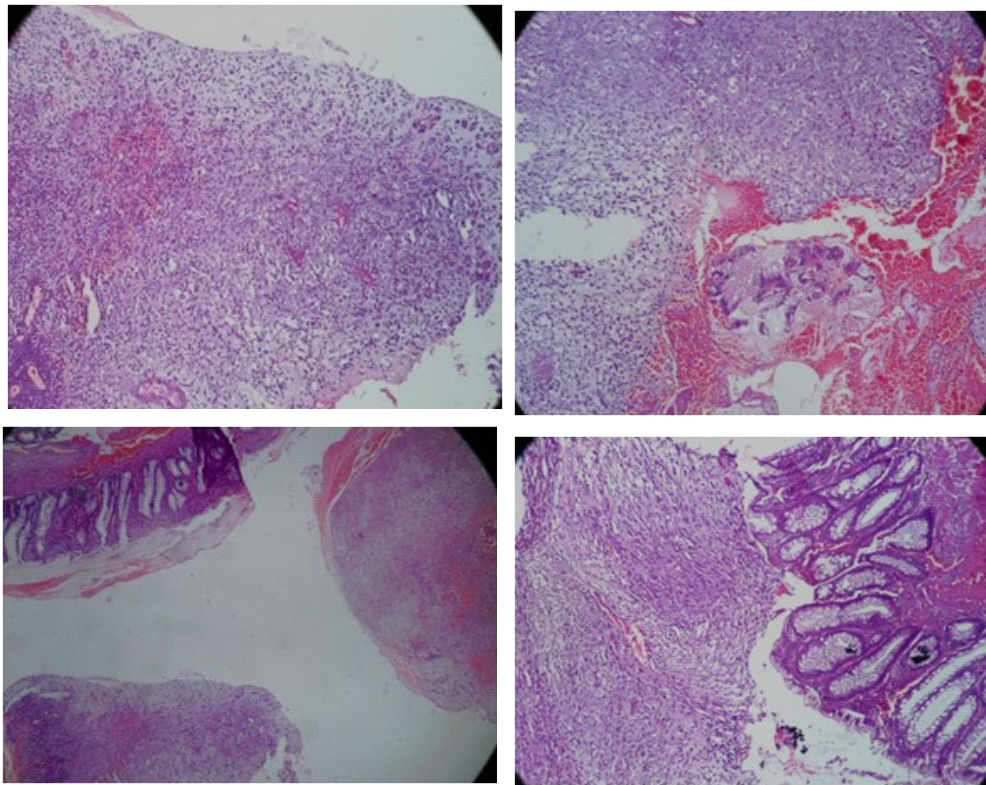
A 45 year man presented to Surgery opd with chief complaints of rectal bleeding and constipation for 1 month. There was no history of pain and mass per rectum. There was a history of histopathological and immunohistochemistry proven retroperitoneal leiomyosarcoma (Figure 1) for which he was operated in tertiary center 8 months back. Colostomy was done and was closed after 3 months. He received 2 cycles of gemcitabine and docetaxel based chemotherapy.

His physical exam was unremarkable other than a digital rectal exam which revealed a firm mass in the posterior rectal wall. Biopsy from the mass was taken. Histopathology revealed differential diagnosis for leiomyosarcoma and gastrointestinal stromal tumour (GIST). (Figure 2)

**Figure 1 - leiomyosarcoma with high cellularity, spindle-shaped stromal cells, and mitoses (H&E '200)**



**Figure 2- Microscopic appearance of rectal stromal tumor composed of spindle cells.**



Immunostain was positive for both CD34 and CD117 confirming the diagnosis of Gastrointestinal stromal tumour.

Ultrasound abdomen showed a heterogenous ill defined mass lesion in the retroperitoneum region with left side hydronephrosis with mesenteric lymphadenopathy.

CT abdomen was planned and revealed an ill defined lobulated soft tissue lesion of size 10'12'8 cm seen within pelvis encasing sigmoid colon, left ureter causing hydronephrosis. The features suggestive of recurrent leiomyosarcoma with left side hydronephrosis.

He is presently on imatinib based chemotherapy and doing well with no complication.

## 2. Discussion

Soft-tissue sarcomas form approximately 1% of adult malignancies. Extremities are most commonly involved followed by retroperitoneal/visceral and trunk involvement.<sup>1</sup> Retroperitoneal soft-tissue sarcomas form 13% of all adult soft-tissue sarcomas. They are locally invasive, large tumors that remain occult for long periods of time due to the abdominal cavity's ability to accommodate these slowly expanding masses with a paucity of symptoms.<sup>2</sup> They most commonly present with abdominal discomfort and abdominal mass.<sup>3</sup> The overall 5-year survival rate of retroperitoneal sarcomas 36%–58% and is dependent on tumor histology and extent of tumor invasion.<sup>3</sup>

Surgery is the mainstay of treatment. Despite of modern imaging, medicine and surgical technique, up to 90 % result in local recurrence and result in death.<sup>4</sup> Adjuvant and neoadjuvant chemoradiotherapy are being used but further investigation is necessary.<sup>5</sup>

A gastrointestinal stromal tumor (GIST) is one of the most common mesenchymal tumors of the gastrointestinal tract (1-3% of all gastrointestinal malignancies). They may or may not stain positively for Kit.<sup>6</sup>

Rectal GISTs make up 0.1% of all tumours originating in the rectum.<sup>7</sup> CD117 also serves as the target for drug

therapy with imatinib, a selective tyrosine-kinase receptor inhibitor that is at present the only promising chemotherapeutic drug for the treatment of patients with advanced GIST, although complete surgical resection remains the most effective treatment for such a tumour.<sup>8,9</sup>

The signs, symptoms and workup of rectal GIST are similar to that of other rectal tumours. GIST typically expresses CD117, often CD34 and sometimes SMA and S-100, but its expressions vary depending on different sites. The reason for these variations has not yet been explained.

### 3. Conclusion

In conclusion, with our knowledge this is the first case of retroperitoneal leiomyosarcoma with rectal GIST and is not reported earlier. Early recognition and aggressive surgery are the keys to long-term survival of patients with retroperitoneal sarcomas and rectal GIST, but the mainstay of treating advanced disease is yet to be determined and needs further research as the overall prognosis of advanced disease is relatively poor.

### References:

1. Hoos, J. J. Lewis, and M. F. Brennan, "Soft-tissue sarcomas—prognostic factors and multimodal therapy," *Chirurg*, vol. 71, no. 7, pp. 787–794, 2000.
2. Lawrence Jr., W. L. Donegan, N. Natarajan, et al., "Adult soft tissue sarcomas : a pattern of care survey of the American College of Surgeons," *Annals of Surgery*, vol. 205, no. 4, pp. 349–359, 1987.
3. G. A. Porter, N. N. Baxter, and P. W. Pisters, "Retroperitoneal sarcoma: a population-based analysis of epidemiology, surgery, and radiotherapy," *Cancer*, vol. 106, no. 7, pp. 1610–1616, 2006.
4. F. K. Storm and D. M. Mahvi, "Diagnosis and management of retroperitoneal soft-tissue sarcoma," *Annals of Surgery*, vol. 214, no. 1, pp. 2–10, 1991.
5. D. M. Thomas, B. O'Sullivan, and A. Gronchi, "Current concepts and future perspectives in retroperitoneal soft-tissue sarcoma management," *Expert Review of Anticancer Therapy*, vol. 9, no. 8, pp. 1145–1157, 2009.
6. Miettinen M, Lasota J (October 2006). "Gastrointestinal stromal tumors: review on morphology, molecular pathology, prognosis, and differential diagnosis". *Arch. Pathol. Lab. Med.* **130** (10): 1466–78.
7. Suzuki T, Sadahiro S, Tanaka A, Okada K, Okamura H, Machida T, Kumaki N. Gastrointestinal stromal tumor of the rectum: report of three cases. *Tokai J Exp Clin Med.* 2011; 36(3):58-62.
8. DeMatteo RP, Lewis JJ, Leung D, Mudan SS, Woodruff JM, Brennan MF. Two hundred gastrointestinal stromal tumors: recurrence patterns and prognostic factors for survival. *Ann Surg*2000; 231: 51-58.
9. Venkat Krishna B R, Shashirekha C A, Suresh T N, Jothinder Singh. A rare case of perforated gist of transverse mesocolon with synchronous rectal carcinoma. *International Journal of Biomedical Reseach*, vol 3, no.5, 262-264, 2012.