

Case Report

Post abdominal hysterectomy vesico-vaginal fistula repair by O'connor technique

Surekha Tayade^{1*}, Bhupendra Mehra², Amardeep Tembhare³

¹Professor, Dept of Obstetrics and Gynecology, Mahatma Gandhi Institute of Medical Sciences, Sewagram, Wardha, Maharashtra, India

²Professor, Dept of Surgery, Mahatma Gandhi Institute of Medical Sciences, Sewagram, Wardha, Maharashtra, India

³Assistant Professor, Dept of Obstetrics and Gynecology, Mahatma Gandhi Institute of Medical Sciences, Sewagram, Wardha, Maharashtra, India

*Correspondence Info:

Dr. Surekha Tayade

Professor, Dept of Obstetrics and Gynecology,

Mahatma Gandhi Institute of Medical Sciences, Sewagram,

Wardha, Maharashtra, India

Email: surekhatayademgims@yahoo.co.in

Abstract

Despite a long clinical history and extensive surgical experience, VVF continues to challenge even the most experienced gynecologic surgeon. The key is prevention with good surgical technique and identification and repair of the bladder injury at the time of index surgery. Patients with characteristics symptoms following an antecedent event should be treated with high clinical suspicion. Physical exam, laboratory evaluation, and ancillary testing should make the correct diagnosis in virtually all patients. If small and treated immediately after the antecedent event, conservative therapy with prolonged bladder drainage may be effective. However, most patients will require surgery, which can usually be performed successfully through a vaginal route. Abdominal procedures are reserved for more complicated cases. Adherence to strict surgical principles for fistula repair will result in optimal cure rates with minimal complications. Using these guidelines, both the clinician and patient should feel comfortable with the successful management of VVF. The incidence of genital fistulas can be reduced by vigilant care and meticulous surgery. Here we are discussing a case of post hysterectomy VVF in a 32 year old female who persisted to have urinary incontinence even after repeated attempts of repair by vaginal route

Keywords: Abdominal Hysterectomy; Vesicovaginal Fistula; Cystography; Intravenous Pyelography

1. Introduction

Vesicovaginal fistula has been one of the most unfortunate accompaniments of the virtue of procreation bestowed upon womanhood. First reported by Derry in 1935 upon examination of the mummified remains of Egyptian Queen Henhenit (in royal family of Egypt 11th Dynasty, 2050 BC), the VVF continues to remain a challenging condition for the gynaecologic surgeon^{1,2}. Not very long ago, Princess Charlotte, daughter of George IV of England succumbed to the consequences of obstructed labour in the year 1817.³

Vesico-vaginal fistula is among the most distressing complication of gynaecologic and obstetric procedures⁴. VVF after abdominal hysterectomy is not a new calamity for women particularly in the rural area and in inexperienced surgical hands. Women with VVF continue to suffer year after year as they become socially outcast due to continuous smell of urine from their clothes. Urinary fistulas cause immense physical and psychosocial problem in women's life⁵. They may not be a life-threatening problem, but surely the women faces demoralization, social boycott and even divorce and separation⁶. But the entity is not incurable and with appropriate treatment, the long suffering woman could lead a stress free life.

The most frequent cause of VVF in developed countries is hysterectomy, while in the third world it is usually related to labour and its complications. Also there are other risk factors like tobacco use, large uterine size and increased operative blood loss.⁷

VVF in developing countries is associated with benign gynaecologic surgery, especially hysterectomy⁸ and is caused by extensive dissection between the bladder and the uterus, unrecognized bladder lacerations, inappropriate placement of haemostatic suture and/or devascularisation injury to the tissue. Concurrent ureteric involvement has been reported to be as high 10-15% of VVF cases. Other risk factors predisposing to development of VVF include prior pelvic surgery, history of PID, pelvic malignancy, endometriosis, infection, diabetes and anatomic distortion⁷. The presence of these risk factors should be considered pre-operatively and patients counselled accordingly.

Fortunately, the diagnosis and surgical management of VVF is associated with high cure rates if performed by trained gynaecologic surgeons.

2. Case Details

A 32 year old parous woman, presented to the gynaecological outpatient unit of a rural medical institute of central India with the complaints of urinary incontinence since 1 year with increase in flow on coughing and sneezing. She had undergone abdominal hysterectomy for dysfunctional uterine bleeding 1 year back at a private hospital in Kagaznagar district of Andhra Pradesh. Though the surgery was uneventful and patient's condition was apparently well on discharge, she started having dribbling of urine through the vagina after 5 months which increased in flow subsequently. She consulted her treating gynaecological surgeon and was diagnosed to have vesicovaginal fistula for which repair was done through vaginal route. The operation failed to cure her of her symptoms and a second repair surgery was performed, again vaginally after 3 months. After a brief symptom free interval the woman again started having urinary incontinence. She suffered the distressing complaint in silence for 8 months and reported to the present institute in a highly demoralised state.

On vaginal speculum examination we found that the urine was leaking from the vaginal vault but the exact site could not be located and incontinence increased on vulsalva manoeuvre. There was cicatrisation and the vault was pulled up. A small fistula was located high up on the vault on 3 swab test where methylene blue dye was instilled perurethrally via a catheter. On cystoscopy (Figure 1 and 2) we found that the ureteric orifices were normal and there was presence of a diverticuli on the posterior wall between the two ureteric orifices, 1.5 cm in size probably formed due to previous repair procedure. A small fistulous opening was noted 3 mm in size, just by the side of the diverticuli in between the two uretric openings supratrigonally. To rule out the possibility of multiple small fistulae cystography was done which confirmed the presence of diverticuli on posterior wall of the bladder and a thin stream of urine seen passing by the side of the diverticuli confirming single small fistula. Intravenous pyelography (Figure 3) could not pinpoint the fistula. Due to the supratrigonal position of the fistula and a history of vaginal repair for fistula done twice we planned to do the repair abdominally via a transvesical approach. Perurethral foley's catheter was introduced and 30 ml of normal saline was instilled in its bulb. The retropubic space dissected to delineate the bladder and a 3 cm cystotomy was done. Ureteric stents were placed and the diverticuli was located. The fistula was less than 3mm in size in the midline and it was decided to repair it by the O'Connor's procedure where after appropriate mobilization on the anterior---superior and posterior planes, the bladder was "bisected" with a vertical incision until the end of the fistula. The bladder walls surrounding the fistula were released from the vagina and debrided in all directions until the healthy tissue was reached and was separated from the vaginal vault. The repair was done in two layers using delayed absorbable sutures and a omental flap was interposed between bladder and vagina. Suprapubic catheter was inserted and intraperitoneal and retropubic drains were kept. Continuous drainage of the bladder was ensured for an arbitrary period of 3 weeks. The postoperative period was uneventful and the patient was discharged after ensuring urinary continence. After six months of follow up the woman is continent and is satisfied with the repair surgery.

3. Discussion

Vesicovaginal fistulas are among the most distressing complications of obstetric and gynecologic procedures. The condition is a socially debilitating with grave medicolegal implications. Though obstetrical fistulas are not uncommon in the third world countries, there is an increasing trend of post surgical fistulas in recent years. With the development of medical science there has been a shift in the etiology of VVF from obstetric to gynaecological causes. If surgical causes are taken into consideration the incidence of urinary fistula after abdominal total hysterectomy varies from 10-60 %⁹ and after vaginal hysterectomy the risk is 8%¹⁰. Biswas reported that abdominal hysterectomy (44.44%) topped the list of the

gynaecological causes of VVFs and that the success rate after the first attempt of repair of VVF was 82.75% and overall failure was 10.34%⁴.

VVF due to gynaecological operative procedure generally appears 1-6 weeks after surgery and recurrent fistulae appear within 3 months of their repair. The pathogenesis of VVF formation remains unclear¹¹.

Once a VVF is suspected, a thorough vaginal examination should be performed to identify its size and location, especially in relation to the trigone and eliminate an ureterovaginal fistula which can be associated in up to 10% of cases¹². Investigations mandatory for the diagnostic evaluation are vaginoscopy, cystoscopy and excretory urography. The methylene blue test could be done for confirmation but it does not show directly the fistulous tract and its specific location¹³.

Surgery is the mainstay of treatment of such fistulas. A minimum of a 4-6 week's wait from the onset of the fistula to the repair is recommended. Various methods of fistula repair have been described, Latzko procedure, open transabdominal, transvaginal, laparoscopic, transurethral endoscopic and urinary diversion depending on the characteristics of the fistula. The vaginal repair techniques can be categorized as to those that are modifications of the Latzko procedure or a layered closure with or without a Martius flap. The most frequently used abdominal approaches are the bivalve technique or the fistula excision. Radiated fistulas usually require a more individualized management and complex surgical procedures. The rate of successful fistula repair reported in the literature varies between 70 and 100% in non-radiated patients, with similar results when a vaginal or abdominal approach is performed, the mean success rates being 91 and 97%, respectively. Vaginal approach of VVF repair should be the preferred one. Transvaginal repairs achieve comparable success rates, while minimizing operative complications, hospital stay, blood loss, and post surgical pain¹⁴. This approach should be considered the gold standard¹⁵. It is acceptable to repeat the repair through a vaginal approach even after a first vaginal approach failure. In the more individualized management of fistulas associated with radiation, the vaginal approach should still be considered^{10,16}.

The most frequently used abdominal approach nowadays is the O'Connors bivalve technique. The success rate has varied between 75–95% with these various techniques¹⁶. The abdominal approach is the preferred approach when concomitant ureteral reimplantation is required and where the fistula is not approachable from vaginal route⁶. When the fistula is complex vaginal exposure of the fistula is suboptimal which may compromise the repair or endanger the ureters. In these circumstances, a transabdominal approach should be considered. In the present case report the O'Connor's bivalve technique was used. The procedure can be performed extraperitoneally; however, in complex cases, the transperitoneal approach is preferred because it allows for the addition of interposition grafts. Advocates of this technique cite the advantages of high success rate, optimum surgical access to the fistula and ureters, and the ability to add an interposition graft with this procedure. Using an infraumbilical incision, laparotomy is performed and the peritoneal cavity is entered. The posterior wall of the bladder is dissected free as much as possible. The bladder then is bivalved at the dome. This incision is extended posteriorly to the level of the fistula. Stay sutures are placed sequentially along the incisional margins every few centimeters to permit traction and elevation of the bladder wall in order to aid in exposure and dissection.

Ureteral orifices and the location of fistula(s) are identified, and ureteral catheters are placed if necessary. The fistula tract and scarred and necrotic tissue are resected. Dissection of the posterior wall of the bladder from the underlying endopelvic fascia and vagina is completed. The bladder and vagina are closed in separate layers. The bladder is closed with a 2-0 chromic suture in continuous running fashion beginning at the apex and extending through the full muscle layers and imbricated with a second layer with interrupted 1-0 chromic sutures. Commonly, peritoneal or interposition grafts are added. A suprapubic catheter is brought out laterally to the sagittal closure. A transurethral catheter may be placed and discontinued on postoperative day 4 or 5; the suprapubic catheter is removed on postoperative day 14.¹⁷

Postoperative care is similar for both vaginal and abdominal VVF repair. Adequate uninterrupted bladder drainage is the most critical aspect of postoperative management. A voiding cystourethrogram may be performed at 10th postoperative days to confirm closure of the fistula.⁶

Even though the results of VVF repair in the hands of an experienced operator are reasonable, they still need to be better. One should explore the possibility of utilizing newer technological advancements like Laparoscopic and Robotic surgery in order to reduce the operative morbidity while keeping the success rates high. Also technological advancement in tissue handling and healing must be applied to reduce the waiting period between the occurrence of fistula and its repair. However unless these are made available to the masses they defeat the very purpose of their evolution.

Urinary fistula is a preventable entity and to achieve this, it is suggested that patients with severe abdominal pain, distension, paralytic ileus, hematuria or symptoms of severe irritability of the bladder after abdominal hysterectomy be investigated early for a possible bladder injury¹⁸.

References:

1. Derry DE, Note on five pelves of women in the eleventh dynasty in Egypt. *J Obstet Gynecol Br Emp* 1935; 42:490.
2. Holland E. The Princess Charlotte of Wales: A triple obstetric tragedy. *J Obstet Gynecol Br Emp.* 1951; 58:905-919.
3. Lee RA, Symmonds RE, Williams TJ. Current status of genitourinary fistula. *Obstet Gynecol.* 1988 Sep; 72(3 Pt 1):313-9.
4. Mathur R, Joshi N, Aggarwal G, Raikwar R, Shrivastava V, Mathur P et al. Urogenital fistulae: A prospective study of 50 cases at a tertiary care hospital. *Urol Ann.* 2010 May-Aug; 2(2): 67–70.
5. Duong TH, Gellasch TL, Adam RA. Risk factors for the development of vesicovaginal fistula after incidental cystotomy at the time of a benign hysterectomy. *Am J Obstet Gynecol.* 2009 Nov; 201(5):512.e1-4. Epub 2009 Aug 15.
6. Alonso y Gregorio S, Alvarez Maestro M, Cabrera Castillo PM, Hidalgo Togoeres L, de la Peña Barthel JJ. Laparoscopic repair of the vesicovaginal fistula (laparoscopic O'Connor repair). *Actas Urol Esp.* 2009 Nov; 33(10):1133-7.
7. Roberto Martinez P, Rodriguez Colorado SE, Escobar del Barco L, Ramirez Isarraraz C. Vesicovaginal Fistula. Experience at the Instituto Nacional de Perinatologia Ginecol Obstet Mex. 2007 Jan; 75(1):31-4.
8. Eilber KS, Kavalier E, Rodríguez LV, Rosenblum N, Raz S. Ten-year experience with transvaginal vesicovaginal fistula repair using tissue interposition. *J Urol.* 2003 Mar; 169(3):1033-6.
9. Flynn MK, Amundsen CL. Delayed presentation and successful repair of a recurrent vesicovaginal fistula after hysterectomy and primary abdominal repair. *Int Urogynecol J Pelvic Floor Dysfunct.* 2004 Jan-Feb; 15(1):53-5. Epub 2003 Sep 20.
10. Cortesse A, Colau A. Vesicovaginal fistula. *Ann Urol (Paris).* 2004 Apr; 38(2):52-66.
11. Tayade SA, Naina Kumar. Eighteen years old vesico-vaginal fistula caused by forceps delivery: A saga of suffering. *Int. J Biomed Res,* 2012;3 (5) :265-267.
12. Angioli R, Penalver M, Muzii L, Mendez L, Mirhashemi R, Bellati F, et al. Guidelines of how to manage vesicovaginal fistula. *Crit Rev Oncol Hematol.* 2003 Dec; 48(3):295-304.
13. Tancer ML. Observations on prevention and management of vesicovaginal fistula after total hysterectomy. *Surg Gynecol Obstet.* 1992 Dec; 175(6):501-6.
14. Kursh ED, Morse RM, Resnick MI, Persky L. Prevention of the development of a vesicovaginal fistula. *Surg Gynecol Obstet.* 1988 May; 166(5):409-12.
15. Kapoor R, Ansari MS, Singh P, Gupta P, Khurana N, Mandhani A et al. Management of vesicovaginal fistula: An experience of 52 cases with a rationalized algorithm for choosing the transvaginal or transabdominal approach *Indian J Urol.* 2007 Oct-Dec; 23(4): 372–376
16. O'Connor VJ Jr, Sokol JK, Bulkley GJ, Nanninga JB. Suprapubic closure of vesicovaginal fistula. *J Urol.* 1973 Jan; 109(1):51-4.
17. Lentz SS. Transvaginal repair of the posthysterectomy vesicovaginal fistula using a peritoneal flap: the gold standard. *J Reprod Med.* 2005 Jan; 50(1):41-4

Figure 1 Cystography showing diverticuli marked by cross and thin stream of dye by the side of diverticuli indicating the fistula.

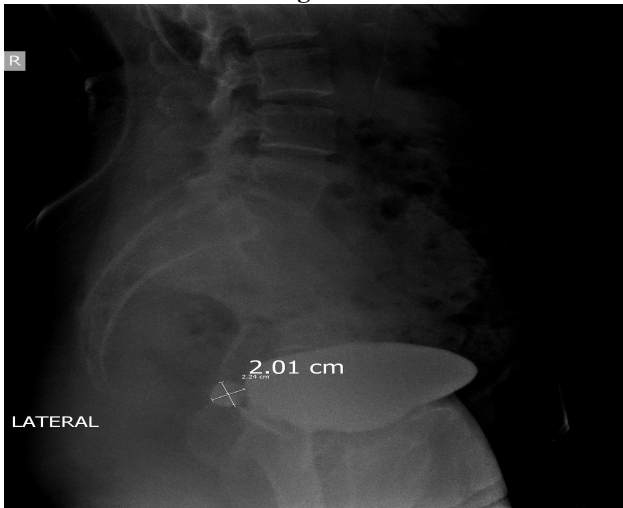


Figure 2 Cystography showing the thin stream of dye indicating fistula in left anterior oblique view

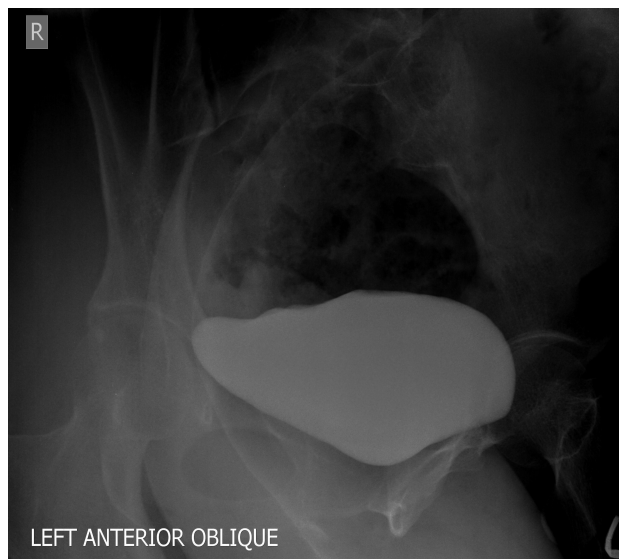

Figure 3 Intravenous pyelography reveals full bladder suggesting that fistula is small and discreet++

