

Case Report

Interesting case of unilateral lung hypoplasia in an asymptomatic young adult

Ram S Kaulgud*, Sumanth K. J, Rajeev R Joshi, Vijayalakshmi P B

Department of Internal Medicine, Karnataka Institute of Medical Sciences, Hubli , India

*Correspondence Info:

Dr. Ram S Kaulgud
Assistant Professor,
Department of Internal Medicine,
Karnataka Institute of Medical Sciences, Hubli, India
Email: ramk72@yahoo.com

Abstract

Lung hypoplasia is one of the rare developmental anomalies, usually presenting with complications in childhood. Patients remaining asymptomatic till adulthood is still rarer. We report one such case.

Keywords: Lung hypoplasia, young adult, bronchiectasis, over-inflated lung

1. Introduction

Lung hypoplasia is a rare developmental anomaly characterised by under development of the lower respiratory tract resulting in fibrotic and non functioning lung. The presentation in an adult for the first time is rare and very few cases have been reported.^{1,2} Here, we report one such case.

2. Case report

A 17 years male was admitted in Department of General Medicine at our institute with chief complaints of off and on fever, breathlessness increasing on exertion since childhood. There was history of dull aching pain over left side of chest for four years and loss of appetite for two months. There was no history of similar respiratory problem in any of the family members and his peri natal history was uneventful. General physical examination was normal. Examination of respiratory system revealed smaller left hemi-thorax. Trachea and heart were shifted to left side. Movements were diminished and percussion note was dull over the left hemi-thorax. On auscultation, air entry was very poor on left side with diffuse coarse crepitations. Rest of systems were within normal limits. Routine haematological investigations (Blood counts, Liver function tests, renal function tests) were within normal limits. Sputum smear for Acid Fast Bacilli was negative on direct smear examination and later on culture. Chest roentgenogram showed a left sided massive homogeneous opacity, shifting of the mediastinum to same side and chest retraction (image 1). The intercostal spaces on left side were narrowed. Right lung was over inflated. The lesions were non progressive on serial chest X-rays.

2.1 CT Scan

Thorax revealed marked asymmetry in thorax. The right lung showed herniation through anterior recess with evidence of oligoemia suggesting compensatory over inflation. The left sided lung showed severe decrease in volume with only minimal residual lung tissue (image 2). Bronchiectatic changes were seen in this lung tissue (image 3). The mediastinum was seen to be shifted to right side.

Patient is under regular follow up and with us. Patient develops recurrent chest infections which respond to broad spectrum antibiotics and symptomatic treatment.

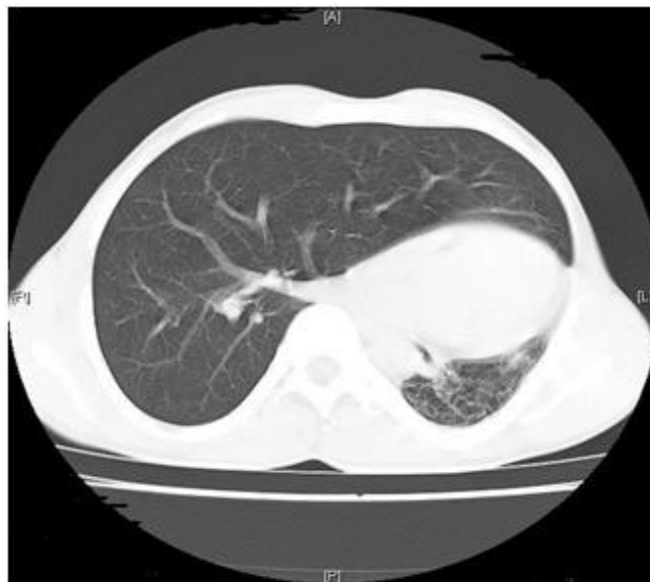
Image 1

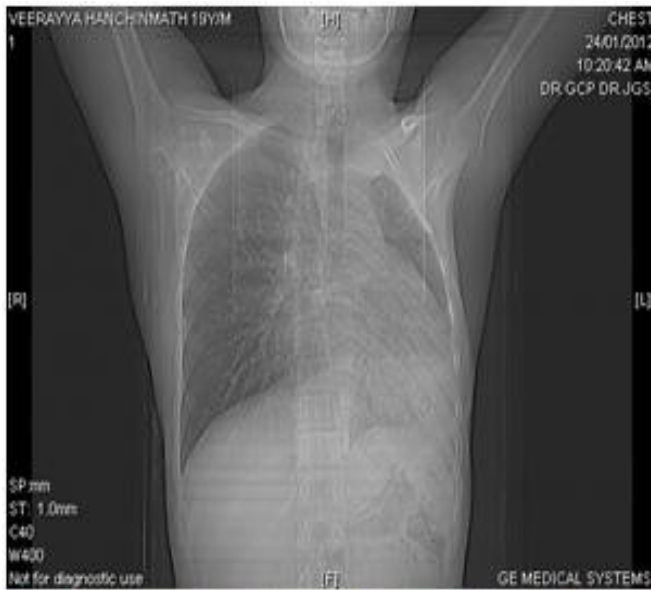

Image 2

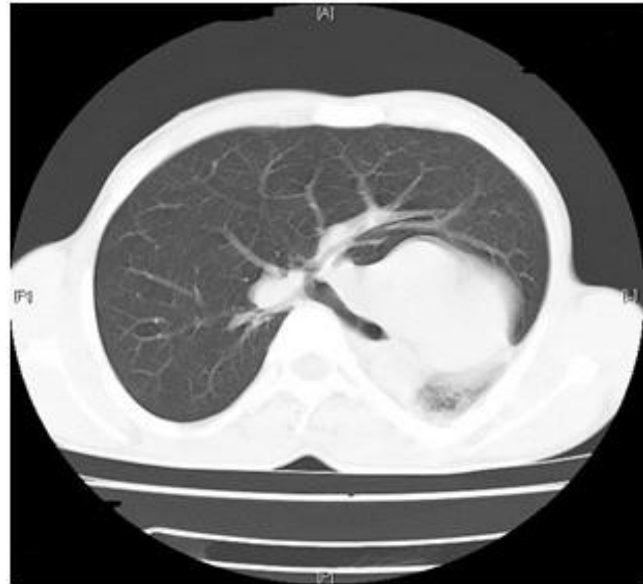

Image 3



3. Discussion

Monaldi, Schneider and Boyden have proposed classification systems for pulmonary agenesis. Lung hypoplasia can be termed as primary (idiopathic) or secondary (when it occurs in association with environmental factors or other congenital anomalies that may be implicated in its pathogenesis). The reported incidence of pulmonary hypoplasia in the general population ranges from 9 to 11 per 10000 live births and is 14 per 10 000 of all births.^{3,4} Hypoplastic lungs are smaller in size and there is reduction in airway generation to about 50-70% of normal and also reduced alveolar size. The left lung is affected more frequently than the right, males predominate over females and the majority of cases exhibit other congenital abnormalities like patent ductus arteriosus, pulmonary artery atresia, cardiac malformation, tracheo-esophageal fistula, cardiac malformation and horse-shoe kidney.⁵ Autosomal recessive

chromosomal aberration, associated with consanguineous marriage⁶, deficiency of vitamin A, intrauterine infections, environmental factors have been held responsible for the etiology of congenital lung malformations. Abnormalities of pulmonary arterial system have also been reported to be abnormal in many of the cases consisting of the variation in muscular and elastic tissues in arteries.

Reduced lung volume is clinically diagnosed by the signs of volume loss on ipsilateral side, viz, crowding of ribs, elevated ipsilateral diaphragm and shift of mediastinum ipsilaterally. There may be compensatory emphysema on the contralateral side. Imaging of chest in lung hypoplasia show absence of aerated lung on one side.⁷ CT scan may be required to establish the degree of under development and to differentiate hypoplasia from other conditions that may closely mimic it radiographically: ⁸ atelectasis from other causes, severe bronchiectasis with collapse and advanced fibrothorax. There are no clear clinical diagnostic criteria to facilitate the identification and management of lung hypoplasia. Treatment of hypoplasia is in form of medical as well as surgical care, both before and after delivery. Prenatally amniotomies, antibiotics, steroids may be given. Oxygen and surfactant administration have been found to improve survival. Adults are treated mainly symptomatically by antibiotics, bronchodilators. Prophylaxis for respiratory syncytial virus, pneumococcus, influenza infections are recommended.

References

1. Simon L. F. Walsh and Benjamin J. Robertson. Incidental Agenesis of the Lung Presenting as Dyspnea; *Am. J. Respir. Crit. Care Med.* 2012; 185: 103.
2. Kang Kim, Kyung Hoon Min, Seoung Ju Park, So Ri Kim et al. Right Pulmonary Agenesis in a 12-Year-Old Girl; *Am. J. Respir. Crit. Care Med.* 2011; 184:742-743.
3. Knox WF, Barson AJ. Pulmonary hypoplasia in a regional perinatal unit. *Early Hum Dev* 1986; 114: 33-42.
4. Moessinger AC, Santiago A, Paneth NS, Rey HR, Blanc WA, Driscoll JM Jr. Time trends in necropsy prevalence and birth prevalence of lung hypoplasia. *Pediatric Perinatal Epidemiol* 1989; 3: 421-431.
5. Partha P Roy et al. Unilateral pulmonary agenesis presenting in adulthood. *Respiratory Medicine* 2012 Case Reports: Volume 5,; 81-83.
6. M.K. Mardini, W.L. Nyhan. Agenesis of the lung :Report of four patients with unusual anomalies: *Chest* 1985, 87: 522-527.
7. J.B. Booth, C.L. Berry. Unilateral pulmonary agenesis ; *Arch Dis Childhood* 1967, 42: 361-374.
8. M.Z. Schwartz, P. Ramachandran. Congenital malformations of the lung and mediastinum: a quarter century of experience from a single institution. *J Pediatr Surg* 1997, 32: 44-47.