

## Case Report

### Persistent Mullerian Duct Syndrome- A Case Report

D. Madhavi\*

Assistant Professor, Department of Anatomy, Guntur Medical College, Guntur-522004, A.P, India.

#### \*Correspondence Info:

Assistant Professor,

Department of Anatomy,

Guntur Medical College, Guntur-522004, A.P, India

Email: [madhavikondepudi@gmail.com](mailto:madhavikondepudi@gmail.com)

#### Abstract

The persistent Mullerian duct syndrome is a rare disorder of male sexual organ development, the incidence of which is not known. It is characterized by the presence of uterus, fallopian tubes and upper vagina in otherwise normal male individuals. The Mullerian duct is normally regressed under the influence of anti-Mullerian hormone (AMH), which is secreted by primitive sertoli cells of testes. A failure of this process, either due to defective AMH synthesis or defective AMH receptor results in persistent Mullerian duct syndrome.

**Keywords:** persistent Mullerian duct syndrome, Anti-Mullerian hormone (AMH), Orchidectomy, cryptorchidism

#### 1. Case Report

The present case is of an eight months old male child (born to a 30 year old 2<sup>nd</sup> gravida, 2<sup>nd</sup> para mother), who had a right inguinal hernia and left undescended testis since birth. Ultrasound demonstrated a transverse ectopic testis in the right inguinal canal. Surgery was performed under general anaesthesia. A heavy hernia sac was noticed on opening the right inguinal canal. On opening the hernia sac a testis, an ovary and rudimentary uterus were found. Subsequently fallopian tubes and vasa deferentia were also found bilaterally. The female reproductive structures were removed and orchidopexy was performed.

#### 2. Case History

An eight months old male child was brought to the out-patient department with chief complaints of undescended testis on left side and swelling in the right groin.

**Maternal history:** A 31 year old, 2<sup>nd</sup> para mother. H/O Second degree consanguinity. First baby was healthy. No H/O congenital anomalies. Not an alcoholic. No systemic disease during gestation. She was a booked case and adequate iron tablets has been given. No drug or radiation exposure during pregnancy.

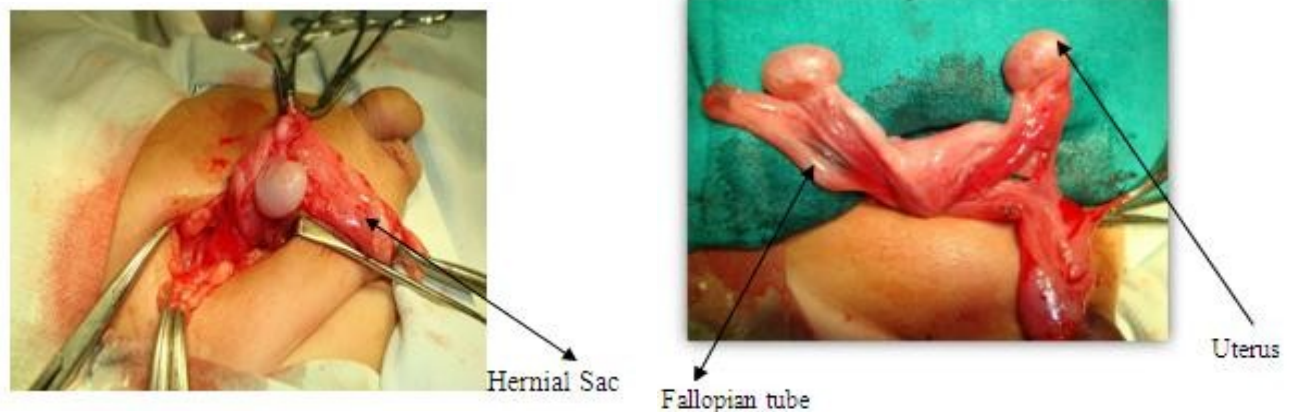
**Investigations of baby:** Haemogram: Normal, Urine analysis: Normal.

**Ultrasonography:** Right testis in the right scrotal sac. Left testis in the right inguinal canal.

**Diagnosis:** The case was diagnosed as Transverse Testicular Ectopia.

**Management:** surgery.

**Surgical Procedure:** Under general anaesthesia, right inguinal crease was incised. A heavy hernial sac was noticed on opening the inguinal canal. Hernial sac was opened. The left testis was seen in the hernial sac. A rudimentary uterus with fallopian tubes was found. Uterus and fallopian tubes were removed cautiously without traumatizing the vasa deferentia. The ectopic testis was positioned in the left scrotal sac. The incisions were sutured

**Fig 3:showing development of male and female reproductive organs.**

**Final diagnosis:** The case was finally diagnosed as Persistent Mullerian Duct Syndrome (PMDS) with Transverse Testicular Ectopia.

### 3. Discussion

It is a rare syndrome, characterized by the presence of Mullerian duct derivatives in an otherwise normal male individual. It was first described by Nilson in 1939. Inherited as an autosomal excessive condition.

**Incidence:** 0 -1 per 100,000 live births.

**Cause:** Persistence of Mullerian duct. Mutations in Anti Mullerian Hormone (AMH), gene . Lack of AMH .Absence of AMH receptors . No response to AMH.

#### Types

Type I : Due to mutations of gene for AMH on chromosome 19p33.Incidence: About 45%

Type II : Due to mutations of gene (AMH-RII) for the AMH receptor on 12q13. Incidence: About 39%

**Anatomical Types:** Testis in scrotum; uterus and ipsilateral fallopian tube in the inguinal canal. In some cases, contra lateral testis and fallopian tube are also in the hernial sac.

**Female Type:** Least common form. Characterized by bilateral cryptorchidism with testes embedded in the broad ligaments in an ovarian position with respect to the uterus.

**Diagnosis:** Ultrasonography, Computerized Tomography, MRI, Laparoscopy . Before puberty, serum AMH levels may also help in diagnosis.

**Management:** The Müllerian derivatives should be *surgically excised*. Orchiopexy in children. Orchiectomy followed by testosterone supplementation in adults.

**Complications:** Infertility. Due to damage of vasa deferentia caused by müllerian derivatives. Also due to mal-positioning of testes.

**Malignancy:** Mullerian duct derivatives may acquire malignancy. Abdominal testes at a high risk of developing malignancy.

#### Development of genital ducts

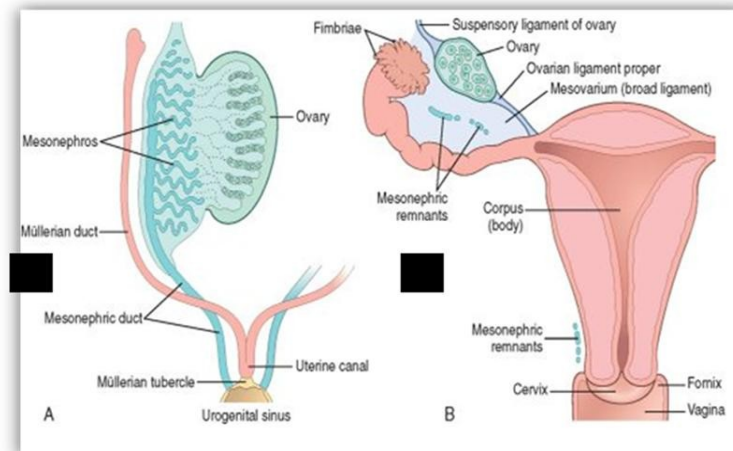
**The paramesonephric ducts:** It starts appearing during sixth week of development.. Cranially, the duct opens into the abdominal cavity with a funnel-like structure. Caudally, it comes in close contact with its counter-part in the midline.

Fate of mesonephric and paramesonephric ducts in males under the influence of testosterone. Each mesonephric duct finally gives:Efferent ductules, (from excretory tubules), Epididymis, Vas deferens, Seminal vesicle. The

paramesonephric ducts regress under the influence of AMH.

Fate of mesonephric and paramesonephric ducts in females under the influence of estrogen. The mesonephric ducts get atrophied; The paramesonephric ducts give rise to: Fallopian tubes, Uterus, Upper vagina

**Fig 3: showing development of male and female reproductive organs.**



Development of paramesonephric ducts is influenced by anti müllerian hormone (AMH).

Anti Mullerian Hormone Secreted by sertoli cells of fetal testes. The action of AMH is predominant during 8<sup>th</sup> week of development. AMH is the product of AMH gene located on short arm of 19<sup>th</sup> chromosome. Expression of this gene is regulated by transcriptional factor SOX9. It acts majorly through type II AMH receptor.

#### 4. Conclusion

In order to prevent further complications such as infertility and malignant change, the surgeon should be aware of PMDS while dealing with patients who present with unilateral or bilateral cryptorchidism.

#### Acknowledgements

I am very grateful to “Dr . Subba Rao Garu , Paediatric Surgeon , GGH, Guntur” for his guidance. I thank the parents of the patient for their cooperation

#### References

1. Clemente A, Macchi V, Berretta M, Morra A: Female form of persistent Mullerian duct syndrome - *MDCT findings*. *Clin Imaging* 2008, 32:314-317.
2. Gujar et al.: Male form of persistent Mullerian duct syndrome type I (hernia uteri inguinalis) presenting as an obstructed inguinal hernia: a case report. *Journal of Medical Case Reports* 2011 5:586.
3. Langman's *Medical Embryology* 10<sup>th</sup> Edition : T. W. Sadler.
4. Prakash N, Khurana A, Narula B: Persistent Mullerian duct syndrome. *Indian J Pathol Microbiol* 2009, 52:546-548.
5. Muhammad Shamim: Persistent Mullerian duct syndrome with transverse testicular ectopia presenting in an irreducible recurrent inguinal hernia. *J Pak Med Assoc*, 2007; Vol. 57: 421-423
6. Nilson O: Hernia uteri inguinalis beim Manne. *Acta Chir Scand* 1939, 83:231.
7. C. H. Yip, K. W. Chang : Persistent Mullerian Duct Syndrome – A Case Report. *Singapore Med Journal*, 1991; Vol. 32: 363-364