

EXPERIENCES WITH Mc INDOES VAGINOPLASTY IN MAYER – ROKITANSKY- KUSTER- HAUSER SYNDROME- A CASE SERIES

Vidyadhar B. Bangal*, Kundankumar N. Dandekar, Kishor C. Gadhve, Rashmi K Singh

*Rural Medical College & Pravara Rural Hospital, Pravara Institute of Medical Sciences (Deemed University), Loni

*Corresponding Author: ybb217@rediffmail.com

This article is available online at www.ssjournals.com

ABSTRACT

Background: - Vaginal agenesis or developmental absence of the vagina is one of the major congenital anomalies of the female genital tract. It is estimated to occur in 1 in 4,000-5,000 live female births. It may present either as an isolated developmental defect or within a complex of more extensive anomalies. Vaginal agenesis is most commonly associated with Mayer-Rokitansky-Küster-Hauser (MRKH) syndrome. The aim of this study was to share the experiences of McIndoe vaginoplasty operation, in the creation of a neovagina for patients with vaginal agenesis.

Material and Methods: - This is a retrospective study of ten cases of vaginal agenesis, which had undergone McIndoe vaginoplasty over a period of 4 years (2008-2011) at Pravara Rural Hospital, a tertiary care teaching hospital located in rural area of Maharashtra, India.

Results:- : McIndoe Vaginoplasty was performed with acrylic mould covered with partial thickness skin graft from the thigh in ten patients. The average age of the patients was 20 years. Nine women were unmarried at the time of surgery. The anatomical results were quite satisfactory. There were no major peri-operative complications. Average duration of hospital stay was twelve days. Four patients were found to have vaginal stenosis during the follow-up visits, due to non use or infrequent use of the vaginal mould.

Conclusion: - McIndoe Vaginoplasty is a safe, technically simple and useful procedure to treat the patients of vaginal agenesis. Good compliance regarding persistent use of the mould in postoperative period is essential for attaining functional neovagina.

Keywords: Vaginal agenesis, Mayer Rokitansky Kuster Hauser Syndrome, Vaginoplasty

1. Introduction:-

Vaginal agenesis is congenital anomaly of the female genital tract and may occur as isolated developmental defect or as part of a complex of anomalies.¹ It is estimated to occur in 1 in 4000-5000 live female births. Majority of these patients form part of Mayer-Rokitansky-Kuster-Hauser syndrome, with either absence or presence of only remnants of the uterus. There is association of renal or skeletal anomalies but ovarian functions are normal^{2,3}. Absence of the vagina pose many marital, reproductive, and social problems to an individual and is a cause of great concern for the parents. These patients have been managed surgically by McIndoe's vaginoplasty using split thickness skin graft obtained from thigh or buttocks. Autologous graft like buccal mucosa has also been used with success. Allograft like amnion has been used to line the neovagina, which can reduce the morbidity of the graft donor site. Correct postoperative use of mould is recommended to avoid shrinkage

and stricture of neovagina. Present study was carried out to analyse the results of ten cases of McIndoes vaginoplasty in respect to the operative safety, graft uptake and anatomical and functional results.

2. Material and methods:-

A retrospective analysis of all cases of primary amenorrhoea due to vaginal agenesis, who had undergone Mcindoes Vaginoplasty at Pravara Rural Hospital over a period of four years from January 2008 to December 2011, was carried out. All cases were admitted and investigated for primary amenorrhoea. Necessary investigations were carried out to know about the associated renal and skeletal anomalies. Examination under anaesthesia, pelvic and abdominal ultrasound, MRI, Laparoscopy, Buccal smear examination were carried out as per the need in the individual case. Cases were admitted after proper counselling of the patient and the first degree relatives. Detailed procedure, purpose and the possible outcome

was explained to them. Pre operative preparation consisted of preparation of skin graft site and bowel. Coloclean enema was given on evening prior to surgery. Cases were operated under general anaesthesia. Partial thickness skin graft was obtained by general surgeon from medial and or anterior aspect of upper thigh. Raw area of the skin graft site was covered with soframycin tulle and was bandaged. Patient were put in dorsal lithotomy position. Bladder was kept empty by self retaining foleys catheter. Pelvic findings were further confirmed by per rectal examination. Following a superficial transverse 2 centimeter curvilinear incision in the suburethral region, a space was dissected between urethra and bladder anteriorly and rectum posteriorly. Depth of approximately 8 to 10 centimeters was reached by careful blunt dissection done with index fingers of both hands. Dissected space was inspected by careful speculum examination for any bleeders. Bleeding was controlled by pressure packing or by hemostatic sutures. The space was stretched in antero posterior and lateral direction to attain adequate dimensions. Trial of the mould was taken by putting it in the dissected neovaginal space. After confirming the adequacy of the space and the hemostasis, solid mould covered with skin graft was inserted in the neovaginal space. While inserting the mould, precaution was taken for non dislodgement of the graft mounted on the mould. Mould movement and expulsion was prevented by two vulval stiches and the T bandage. Adequate postoperative analgesia and sedatives were administered to reduce the discomfort. Prophylactic antibiotics in the form of ciprofloxacin, metronidazole and gentamycin were administered parenterally for five days and by oral route for additional five days. Soft diet was started on third postoperative day and catheter was continued for seven days. Patients were ambulated out of bed from fourth or fifth day or may be earlier as per their choice. Bowel movement was preferably restricted for four to five days following operation. Stool softeners were started from fifth postoperative day. Perineal area was regularly checked for bleeding, discharge, position of the mould and any cutting through of vulval stiches. Vaginal mould was removed on tenth postoperative day. Neo vagina was inspected for graft uptake. Dead necrotic tissue and the vaginal discharge was removed by gentle irrigation of neovagina normal saline. Patients were discharged from

hospital on twelfth postoperative day and were asked to come for followup after one week. During follow up visit, the neo vagina was inspected for evidence of sepsis. Patients were advised to use the acrylic mould continuously for three months and then during night time, for next three months. They were asked to come for follow up in outpatient department, every fortnight for two months.

3. Results:-

The average age of the patient at the time of vaginoplasty was 19 years.(18-23 years). Nine patients were unmarried and one was married but was living separate from the husband. Nine cases presented with the symptom of primary amenorrhoea and one presented with dyspareunia. Patients were referred to our hospital either by general practitioners or by gynecologists. All patients were accompanied by their first degree relatives. Most of the cases were school dropouts or were engaged in some unskilled work. No previous attempt of surgery was made in any of the cases. Majority of the parents were aware about the abnormal development of the genitalia of their siblings. There was a great amount of stress and feeling of frustration among the parents. They equally had some amount of hope at the back of their mind. All parents were extremely co operative and were eager for the surgical treatment at the earliest possible date.

All cases were operated under general anaesthesia. The average depth of the neovagina achieved was 8 to 9 centimeters. The average time required to create neovagina was ten minutes. Average time to attain hemostasis in the neovagina was 7 to 10 minutes. Average duration of complete surgery, from taking of skin graft to taking of final labial stich, was 45 minutes. In eight cases, there was minimal bleeding from the raw surfaces of the space dissected that did not require any special treatment except pressure packing with hot mops. In two cases, there were active bleeders in the angles of the upper portion (apex) of the neovagina. The bleeding was controlled by hemostatic sutures and electrocautery and the pressure of the solid mould. Blood transfusion was not required in any of the cases. There was no injury to any of the neighbouring structures like urethra, bladder or rectum. All cases required extra doses of analgesic drugs for first 48 hours. All cases could be ambulated out of bed on fourth postoperative day. There was

reactionary fever in four cases, which could be controlled by antipyretic drugs. The graft uptake was hundred percent. There was no evidence of sepsis in the neovagina in any of the cases. Three cases had little foul smelling vaginal discharge in third postoperative week and were controlled by vaginal douch and betadine vaginal pessaries. All patients came for regular follow up in the initial post operative period. Two cases were lost to follow up after three months of surgery. Four cases continued the follow up till one year. Overall compliance for the use of the mould was not satisfactory. Pains, poor motivation, lack of privacy at home were some of the reasons for the poor compliance. There was significant fibrosis and closure of the dissected space (neovagina) in three cases.

4. Discussion:-

The MRKH syndrome is described as congenital vaginal agenesis in an individual with normal female genotype, phenotype and normal endocrine status. These patients have a rudimentary development or total absence of uterus, but they have normal ovaries.³ The vaginal agenesis is often associated with anomalies of the renal (34%) and the skeletal (12%) systems.⁴ The Renal anomalies may include unilateral agenesis of the kidney, ectopic kidney(s), horseshoe kidney, and crossed-fused ectopia and skeletal anomalies may include fused vertebrae or other variants. Vaginal agenesis is associated most commonly with Mayer-Rokitansky -Küster-Hauser (MRKH) syndrome. Hauser and Schreiner in 1961 first described the Mayer- Rokitansky - Küster-Hauser syndrome after reviewing the autopsy reports described by Mayer in 1829, Rokitansky in 1838 and Kuster in 1910.⁵ Awaiting treatments for the diseases and abnormalities of the genital tract and handling genital area, are still considered taboo subjects in the community. This can partially explain the problem of poor compliance for follow up visits. Long term anatomical and functional results of this operative technique could not be assessed for the aforementioned reasons. One of the most important criteria for this operation is the surgeon's conviction that the patient is mature enough to wear the vaginal mould for at least 6 months, unless she is engaging in regular sexual intercourse. Failure to wear the vaginal form, especially with the split-thickness skin graft, is the major cause of failure in this operation. This generally occurs in adolescent

girls, who do not understand the importance of keeping the vaginal mould in place, even if it is inconvenient or uncomfortable. Some workers have used a soft mould made up of foam material with good results. The post operative discomfort with soft mould is much less than the hard acrylic moulds. We feel that the hard mould had proper snug fitting in the vagina, which kept the graft in close contact with the raw surface of the dissected space. It also served haemostatic purpose in two of our cases. It is also suggested to keep the soft material mould for three months and replace it subsequently with hard mould for another three months. Saraf S reported good success with soft mould made up of foam material covered with sterile condom.⁶

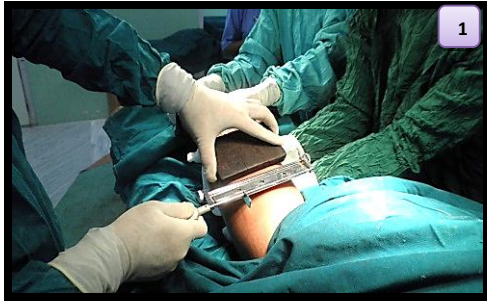Conclusion:-

McIndoe Vaginoplasty is a safe, technically simple and useful procedure to treat the patients of vaginal agenesis. Good compliance regarding persistent use of the mould in postoperative period is essential for attaining functional neovagina.

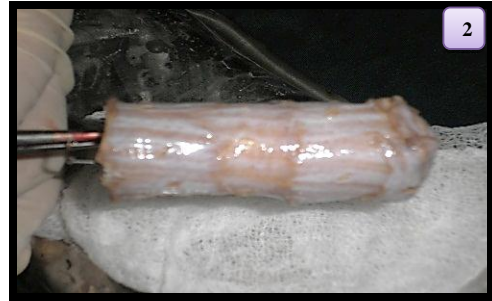References:-

1. Capraro VJ, Gallego MB. Vaginal agenesis. *Am J Obstet Gynecol* 1976;124: 98-107.
2. Tolhurst DE, van der Helm TW. The treatment of vaginal atresia. *Surg Gynecol Obstet* 1991; 172(5):407-14.
3. Hojsgaard A, Villadsen I. McIndoe procedure for congenital vaginal agenesis: complications and results. *Br J Plast Surg* 1995;48(2):97-102.
4. Griffen JE, Creighton E, Madden JD, Harrod MJ, Wilson JD. Congenital absence of the vagina: the Mayer-Rokitansky-Küster-Hauser syndrome. *Ann Intern Med* 1976; 85:224-236.
5. Mobus VJ, Kortenhorn K, Kreienberg R, Freidberg V. Long term results after operative correction of vaginal aplasia. *Am J Obstet Gynecol* 1996;175:617-624.
6. Saraf S, Saraf P : McIndoe Vaginoplasty: Revisited. *The Internet Journal of Gynecology and Obstetrics*. 2007; 6 : 2

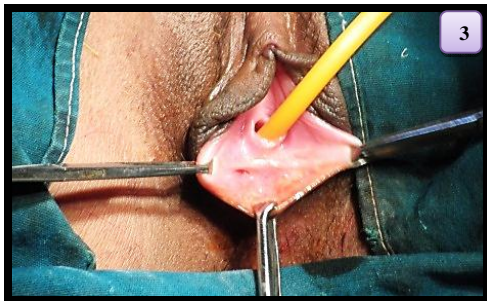STEPS OF Mc INDOES VAGINOPLASTY



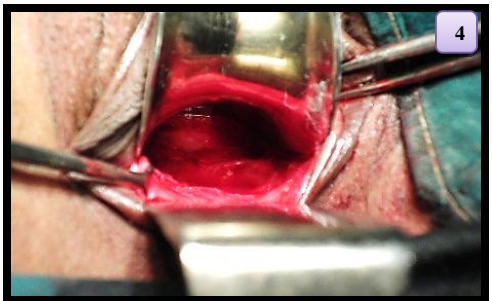
Partial thickness skin graft



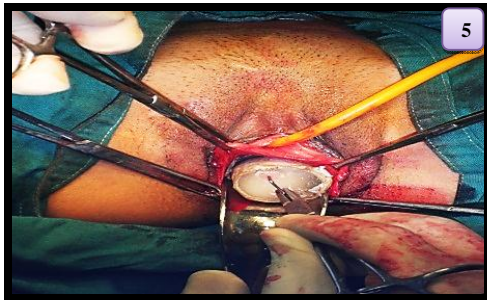
Acrylic mould with skin graft



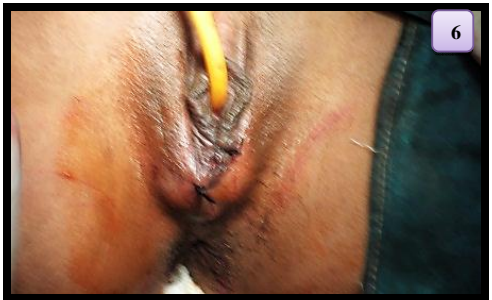Vaginal agenesis before surgery



Creation of neovagina



Mould with skin graft in situ



Vulval stich with mould in situ