

PNEUMOTHORAX FOLLOWING ELECTRICAL BURN INJURY: A CASE REPORT

Shashirekha C A*, Krishna K Prasad & Vijay Agrawal

Dept. of General Surgery, Sri Devaraj Urs Medical College, Tamaka, Kolar Karnataka 563101, India

*Corresponding Author: drca_shashirekha@yahoo.co.in

This article is available online at www.ssjournals.com

ABSTRACT

Electrical injuries are a common occurrence and they can be very trivial or fatal depending on the voltage. Electrical current causes tissue damage by producing heat due to local tissue resistance. Sometimes patients present with visceral damage, organ perforation or pneumothorax. Pneumothorax as an immediate complication of electrical burn injury is a rare entity since, it usually develops two days after significant electrical injury. We report one such treated case of electrical burn injury with right sided pneumothorax as an immediate complication. The outlook is very good in patients who survived the initial electrical exposure and received prompt treatment of complications.

Keywords: Electrical burn injury, Pneumothorax, Chest drain

1. Case Study

A 26 year male was brought to casualty after getting an electric shock, while fitting an electric bulb at home. He was severely restless and breathless. He had no injuries to head and chest. There was no history of any co-morbid conditions. Breath sounds reduced on the right side. He had pulse rate of 150/min regular, blood pressure of 210/120 mm Hg, respiratory rate of 36/min and Sp_o₂ of 45%.

There was superficial to deep burn wounds on palmer aspect of both hands (Figure - 1). Other systemic examinations were within normal limit. His Electrocardiograph (ECG) was normal except for sinus tachycardia.

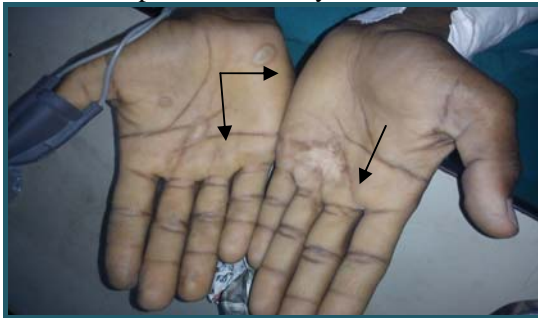

Figure 1- shows site of entry and exit wounds

Laboratory investigations were normal.

Chest X-ray showed right pneumothorax with no rib or clavicle fractures (Figure - 2).

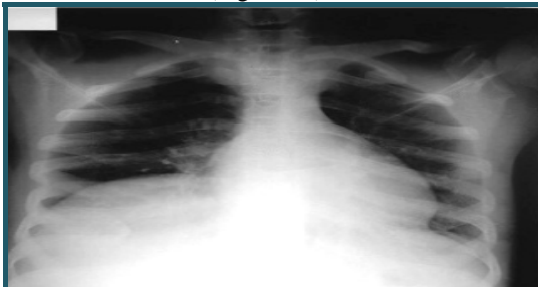

Figure 2- shows right sided pneumothorax following electrical injury

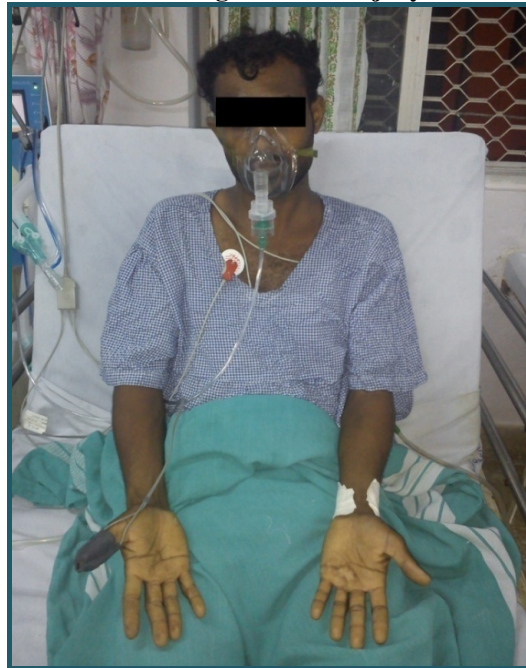

Figure 3- shows patient with Intercostal drain in place

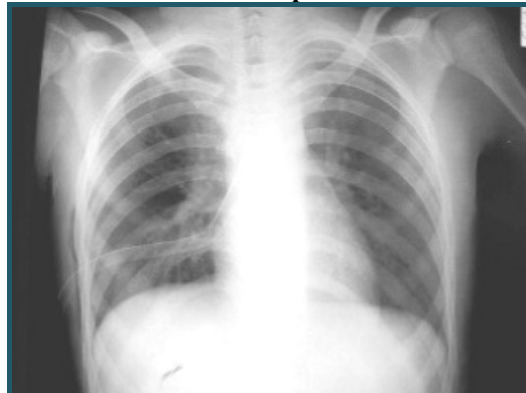


Figure 4- shows pneumothorax has subsided after Intercostal drain (ICD) insertion

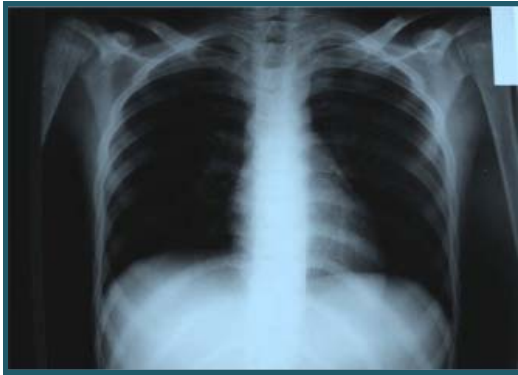

Figure 5- Eight days after removal of the chest drain; pneumothorax has resolved completely. Immediately an Intercostal drain was inserted and after 20 minutes, patient became stable with pulse rate of 86/min, Blood pressure of 140/100 mm Hg and spo2 of 90%.

Follow up chest X-ray showed decreased pneumothorax with Intercostal drain in situ (Figure-3). Patient was shifted to surgical intensive care unit (SICU) for monitoring.

Post operatively patient's condition improved rapidly.

Post Intercostal drain insertion (day-8) chest X-ray was within normal limit. (Figure-5)

Patient was discharged on day 8 after Intercostal drain removal.

Patient is doing well on follow up.

2. Discussion:

Electrical current causes tissue damage by producing heat due to local tissue resistance^{1,2}. Sometimes patients present with visceral damage, organ perforation or pneumothorax³. Pneumothorax as an immediate complication of electrical burn injury is a rare entity since, it usually develops two days after significant electrical injury². The voltage necessary for electrocution depends on the current through the body and the duration of the current. Traditional teaching is that the severity of electrical injury depends on Kouwenhoven's factors⁴.

- Type of current (direct [DC] or alternating [AC])
- Voltage and amperage (measures of current strength)
- Duration of exposure (longer exposure increases injury severity)
- Body resistance
- Pathway of current (which determines the specific tissue damaged)

However, electrical field strength, a newer concept, seems to predict injury severity more accurately.

The current's pathway through the body determines which structures are injured.

The hand is the most common source point, followed by the head. The foot is the most common ground point.

Current travelling between arm and arm or between arm and foot is likely to traverse the heart, possibly causing arrhythmia. This current tends to be more dangerous than current travelling from one foot to the other.

If skin resistance is low, skin burns are less extensive or absent, with more electrical energy transmitted to internal structures. Thus, the absence of external burns does not predict the absence of electrical injury, and the severity of external burns does not predict the severity of electrical injury⁴.

Conclusion:

Electrical injury needs emergency medical as well as surgical care.

Symptoms may include skin burns, damage to internal organs and other soft tissues, cardiac arrhythmias, and respiratory arrest. Diagnosis is by history, clinical criteria and selective laboratory testing.

The probability of pneumothorax must be considered in high-voltage electrical injuries having ports of entry on the trunk⁵.

Treatment is supportive, with emergency and aggressive care for severe injuries.

References:

1. Mehmet Ceber, Can Ozturk, Semih Baghaki, Can Cinar, Pneumothorax due to electrical burn injury. *Emerg Med J.* 2007 May; 24(5): 371–372.
2. Khan A H, Siddiqui R J., Pneumothorax due to electrical burn *Indian J Chest Dis Allied Sci.* 1998; 40:291–293.
3. Rai I, Jesche M G, Barrow R E. *et al* Electrical injuries: a 30- year review. *J Trauma* 1999. 46:933–936.
4. Mary Ann Cooper, Electrical injuries. *Merkmanual* (January 2009)
5. Sandhir RK, Tiwari IN, Goel A. Management of electrical injuries of the abdomen. *Burns* 1992; 18:253–5.