

PRIMARY FALLOPIAN TUBE CANCER: A CASE REPORT AND SHORT LITERATURE REVIEW

Surekha Tayade*, Madhuri Bagde, Poonam V Shivkumar, Nilajkumar Bagde, Atul Tayade

*Dept of Obstetrics and Gynecology, Mahatma Gandhi Institute of Medical Sciences, Sewagram, Wardha, Maharashtra, India

*Corresponding Author: surekhatayademgims@yahoo.co.in

This article is available online at www.ssjournals.com

ABSTRACT

Primary fallopian tube cancer is a rare malignancy. It is commonly confused clinically with ovarian mass. The commonest clinical features are clear or blood stained discharge per vaginum and abdominal pain. As the fallopian tube distends with the mass the patient has severe abdominal pain and thus presents earlier to the clinician. However thorough clinical examination may still not enable a preoperative diagnosis and thus intraoperative inspection becomes very important to label it as primary tubal origin. The management is similar to epithelial ovarian cancer. It carries a better prognosis than ovarian tumors as it tends to be diagnosed early and has a better five year survival rate.

Keywords: PFTC; Doppler study; laprotomy

1. INTRODUCTION

Primary fallopian tube cancer (PFTC) was first described by Renaud in 1847. It is the rarest gynecologic cancer and accounts for about 0.3% of all the primary female genital tract malignancies. The annual incidence of the tumor is reported to be 0.41 per 100,000 women in the year 1998 to 2002 in United States¹. The Finland cancer registry recorded a rising trend in the incidence of this cancer especially in the urban circles and higher socioeconomic classes².

Preoperative diagnosis of PFTC is rare as the clinical features are non specific and mimic those of ovarian cancer. Most cases are diagnosed during surgery or after histopathological examination. The tumor presents at an earlier stage and has 48% lower cancer specific mortality compared to ovarian cancer even at advanced stages³. The sporadic occurrence of this tumor, confusing, clinical picture and good response to treatment make it an interesting clinical experience for presentation.

2. CASE SUMMARY

A 50 year old female was admitted from the Obstetrics and Gynecology outpatient department, Mahatma Gandhi Institute of

Medical Sciences, Sewagram with the chief complaint of watery discharge per vaginum since six months. The discharge was intermittent, painless, clear, with no aggravating or relieving factor. There was no history of bleeding per vaginum or any other associated complaints. She had attained menopause two years ago. She was para four and both her children were normal deliveries adequately breast fed. There was no history of any other major illness and her personal history and family history were not significant.

Her weight was 45 kilograms, Body Mass Index was 19.2 kg/m² and vital signs were stable. General and systemic examination was unremarkable. Per speculum examination revealed a pale vaginal mucosa with a normal cervix. On per vaginum examination, the uterus was small size, erect, and mobile. A 5x 5 cm non tender mass was palpable in the right fornix, separate from the uterus, hard in consistency, and fixed. The left fornix did not have any palpable pathology.

Ultrasonographic evaluation demonstrated a well defined, solid, hypo echoic mass of size 5.7 x 4.8cm in the right adnexal region. The right ovary was not visualized separately. The uterus and left ovary were unremarkable. Doppler study showed increased vascularity in

the mass. There was no other abdominal pathology. Her Ca 125 was 25.80 U/ml.

Evaluation under anesthesia along with dilatation and curettage was done and histopathological examination of cervical and endometrial tissue did not demonstrate any pathology.

An exploratory laprotomy was planned in view of a solid mass with increased vascularity in a post menopausal woman despite low Ca 125 level. A staging laparotomy showed a tubular mass arising from the fimbrial end of right fallopian tube with hard consistency and papillary excrescences. The right ovary was separately seen from the mass and its architecture was preserved. The uterus, left tube and ovary appeared uninvolved. There was no ascites and intestine, omentum, liver, and undersurfaces of diaphragm appeared uninvolved. Total abdominal hysterectomy, bilateral oophorectomy and left salpingectomy was done with removal of right tube with tumor mass.

Histopathology demonstrated a Papillary Serous Adenocarcinoma arising from the fimbrial end of right fallopian tubes with normal ovaries and uterus. Omental biopsy and cytological analysis of fluid specimens were negative for tumor.

The final diagnosis was stage I Papillary Serous Adenocarcinoma of the Right fallopian tube and the patient was given six cycles of chemotherapy consisting of Cisplatin and Cyclophosphamide after extensive literature review. She has completed the cycles and is doing well on follow up examination.

3. DISCUSSION:

PFTC is a malignancy of the tubal epithelium. Adenocarcinoma is the commonest histological subtype followed by endometrioid, mixed, undifferentiated, clear cell, transitional, and mucinous tumors⁴. Lymphatic invasion is earlier than epithelial ovarian cancer. Metastasis to the brain and lung has been reported.

As the tumor closely resembles ovarian malignancy and is in close proximity to the ovary, it is important to differentiate it from primary ovarian tumor. Sedlis described the following criteria to label a tumor as primary fallopian tube cancer:

1. The cell of origin is endosalpingeal.
2. The tumor resembles the epithelium of the tube
3. A zone of transition from benign to malignant epithelium is present
4. The ovaries are normal or the ovarian tumor is smaller than the tubal tumor.

The median age at diagnosis varies from 52-62 years^{4,5,6}.

Parity and use of oral contraceptives decrease the risk of PFTC^{4, 7}. Infertility increases the risk but infertile patients have a better prognosis⁴. A study in Finland demonstrates a higher risk in smelting workers, artistic workers, hairdressers, packers, and clerical workers⁸. A few authors also report an association between pelvic inflammatory disease and PFTC.

As the fallopian tubes distend with tumor, symptoms develop earlier than ovarian tumors. The common clinical features include postmenopausal bleeding, abdominal pain, abdominal distension, abnormal Pap smear, and Latzko's triad [intermittent profuse serosanguinous discharge along with colicky pain relieved by discharge and an abdominal or pelvic mass]. Another classical pathognomonic feature is Hydrops Tubae Profluens⁹ described as intermittent discharge of fluid per vaginum followed by shrinkage of the adnexal mass. The fluid may be clear, serosanguinous, blood stained, or yellowish. It occurs due to distension of the tube by fluid and relief of symptoms after the fluid escapes from the tube. Ultrasonography is relatively nonspecific. The tumor may present as a solid adnexal mass, cystic adnexal mass, solid mass with cystic component, sausage shaped mass, or a multiloculated mass with cogwheel appearance^{10,11}

The management is based upon the stage of the tumor and combines surgical as well as chemotherapeutic approaches. Various regimens for chemotherapy combine cisplatin or carboplatin with paclitaxel or cyclophosphamide for six courses followed by a second look laprotomy. The five year survival ranges from 93% in stage I tumors to 40% for stage IV tumors as per a SEER report. Even within stage the survival declines as the years since diagnosis increase¹².

CONCLUSION

This case presented many challenges as the mass was relatively small in size and Ca 125 level was low thus creating a diagnostic dilemma. The watery vaginal discharge however pointed towards a need for an invasive diagnostic modality. Vigilance is important in such cases and it was a high index of suspicion that guided us towards delivering an optimal outcome for this patient. Thus we can advocate that even a small sized adnexal mass, hard in consistency in a post menopausal woman should be an indication for diagnostic laparotomy/laparoscopy so that the clinician can catch the cancerous condition at an early stage.

REFERENCES

1. Stewart SL, Wike JM, Foster SL, Michaud F. The incidence of primary fallopian tube cancer in the United States. *Gynecol Oncol*. 2007 Dec;107(3):392-7. Epub 2007 Oct 24.
2. Riska A, Leminen A, Pukkala E. Sociodemographic determinants of incidence of primary fallopian tube carcinoma, Finland 1953-97. *Int J Cancer*. 2003 May 1; 104(5):643-5.
3. Wethington SL, Herzog TJ, Seshan VE, Bansal N, Schiff PB, Burke WM, Cohen CJ, Wright JD. Improved survival for fallopian tube cancer: a comparison of clinical characteristics and outcome for primary fallopian tube and ovarian cancer. *Cancer*. 2008 Dec 15;113(12):3298-306.
4. Pectasides D, Pectasides E, Economopoulos T. Fallopian tube carcinoma: a review. *Oncologist*. 2006 Sep; 11(8):902-12. Review.
5. Ng P, Lawton F. Ann. Fallopian tube carcinoma--a review. *Acad Med Singapore*. 1998 Sep; 27(5):693-7.
6. Schneider C, Wight E, Perucchini D, Haller U, Fink D. Primary carcinoma of the fallopian tube. A report of 19 cases with literature review. *Eur J Gynaecol Oncol*. 2000;21(6):578-82.
7. Riska A, Sund R, Pukkala E, Gissler M, Leminen A. Parity, tubal sterilization, hysterectomy and risk of primary fallopian tube carcinoma in Finland, 1975-2004. *Int J Cancer*. 2007 Mar 15;120(6):1351-4.
8. Riska A, Martinsen J, Kjaerheim K, Lyng E, Sparen P, Tryggvadottir L, Weiderpass E, Pukkala E. Occupation and risk of primary fallopian tube carcinoma in nordic countries. *Int J Cancer*. 2011 Jul 29. doi: 10.1002/ijc.26337.
9. Sinha AC. Hydrops tubae profluens as a presenting symptom in primary carcinoma of the fallopian tube: report of two cases and review of literature. *Br Med J*. 1959 Nov 14;2(5158):996-1001.
10. Haratz-Rubinstein N, Russell B, Gal D. Sonographic diagnosis of Fallopian tube carcinoma. *Ultrasound Obstet Gynecol*. 2004 Jul;24(1):86-8.
11. Slanetz PJ, Whitman GJ, Halpern EF, Hall DA, McCarthy KA, Simeone JF. Imaging of fallopian tube tumors. *AJR Am J Roentgenol*. 1997 Nov;169(5):1321-4.
12. Ries LAG, Young JL, Keel GE, Eisner MP, Lin YD, Horner M-J (editors). SEER Survival Monograph: Cancer Survival Among Adults: U.S. SEER Program, 1988-2001, Patient and Tumor Characteristics. National Cancer Institute, SEER Program, NIH Pub. No. 07-6215, Bethesda, MD, 2007, Chapter 20; Cancer of the fallopian tube, Author; Carol L. Kosary

Figure 1: Primary Fallopian tube cancer (long black arrow), both ovaries (short black arrows) and uterus are seen uninvolved

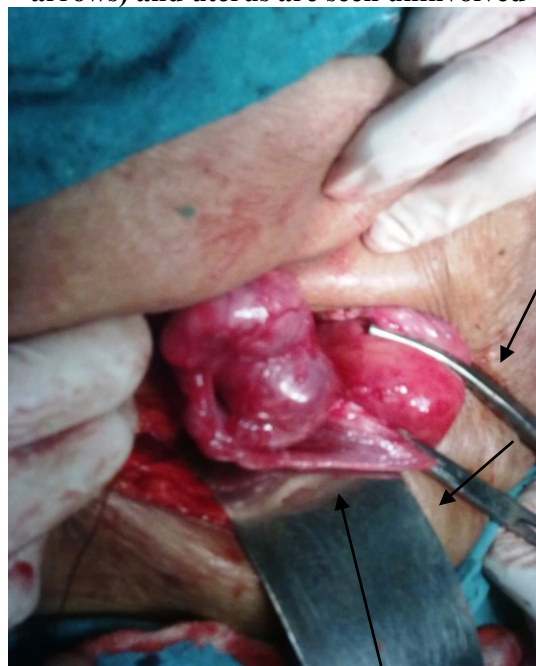

Figure 2 showing microscopic appearance of Adenocarcinoma arising from fallopian tube (40 X)

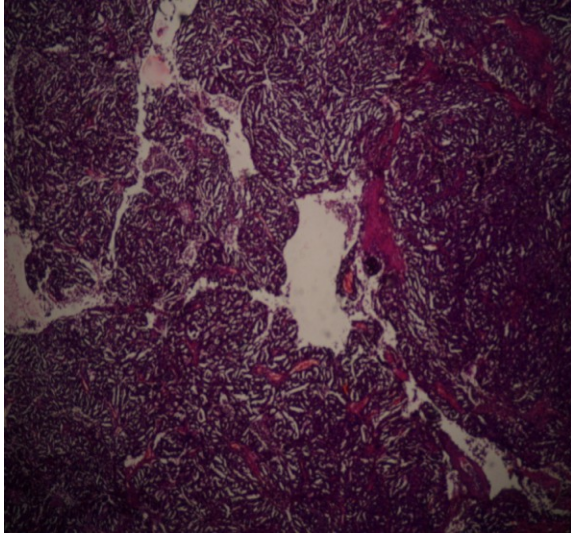


Figure 3 showing microscopic appearance of Adenocarcinoma of Fallopian Tube (10 X)

