

## Risk of urolithiasis due to topiramate as weight loss drug

Elias Sharma<sup>1</sup> and Jaideep M Ratkal<sup>\*2</sup><sup>1</sup>Associate Professor, Department of Urology, Medical College, Jammu, India<sup>2</sup>Associate Professor, Department of Urology, Karnataka Institute of Medical Sciences Hubli, India

### Abstract

Topiramate is sulfamate-substituted monosaccharide anti-epileptic and migraine drug, recently FDA approved as an anti-obesity medicine. Many reports of symptomatic urolithiasis with Topiramate usage as anti-epileptic and migraine drug are available including those studies with biochemical and stone risk profile. We present cases of symptomatic urolithiasis in patients on Topiramate for weight loss and to express caution that the drug usage should be limited and accompanied by assessment of risk profiles at regular intervals.

**Keywords:** Topiramate, Nephrolithiasis, Urolithiasis.

#### \*Correspondence Info:

Dr. Jaideep M Ratkal  
Associate Professor,  
Department of Urology,  
Karnataka Institute of Medical Sciences,  
Hubli, India

#### \*Article History:

**Received:** 02/01/2019  
**Revised:** 09/01/2019  
**Accepted:** 09/01/2019  
**DOI:** <https://doi.org/10.7439/ijbr.v10i1.5031>

#### QR Code



**How to cite:** Sharma E., Ratkal J. Risk of urolithiasis due to topiramate as weight loss drug. *International Journal of Biomedical Research* 2019; 10(01): e5031. doi: 10.7439/ijbr.v10i1.5031 Available from: <https://ssjournals.com/index.php/ijbr/article/view/5031>

Copyright (c) 2019 International Journal of Biomedical Research. This work is licensed under a [Creative Commons Attribution 4.0 International License](https://creativecommons.org/licenses/by/4.0/)

### 1. Introduction

Topiramate discovered by Bruce E Maryanoff and Joseph F Gardoki in 1979 as an anti-epileptic has been in regular usage since then. The drug has a long half life and is mostly excreted unchanged in urine. Dose dependent weight reductions have been observed in rodents on Topiramate [1]. Retrospective studies involving patients on Topiramate for epilepsy have shown progressive weight loss [2]. Subsequently Topiramate has been studied as a pharmacotherapy for weight loss in those patients with type2 Diabetes, essential hypertension [3,4]. Studies have shown 1.5% incidence of urolithiasis in patients on topiramate for epilepsy. This prospective study involves 10 patients on topiramate for obesity who developed urolithiasis with regards to type of stones, biochemical profiles.

### 2. Material and method

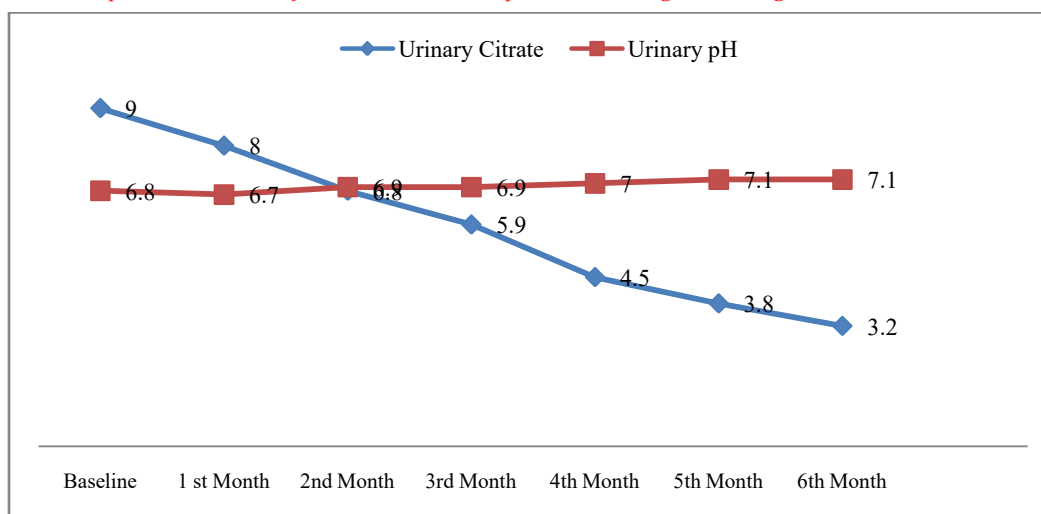
Ten patients [M/F: 6/4] on topiramate for obesity were serially followed during six-month period with monthly ultrasonography, Urinary pH, 24-hour urinary calcium, Uric acid and Citrate levels. Patients were in the age group of 30-50 years. All ten patients had normal baseline ultrasonography and normal urinary biochemical parameters. As the weight reduction on topiramate, the dose

increments were at two weekly periods, reaching optimum dosage of 300mg at the end of 2<sup>nd</sup> month. All the patients had unrestricted normal Indian vegetarian diet. Patients who developed symptomatic urolithiasis were treated expectantly, operative treatment offered only when necessary. Stone analyses were obtained when in those patients who expelled stone on their own or had the stone surgically removed.

### 3. Results

At the end of study period at six months six patients were found to have urolithiasis on ultrasonography, varying in size from 5 to 10 mm. Out of these, two patients expelled the stones on their own and two had their stones removed surgically. In all four stones were available for analysis. Stone analysis showed the stone to be composed of Calcium Apatite, Oxalate and uric acid, apatite being the content in 80% of the stones.

Mean urinary pH increased from a baseline value of 6.8[6.4 to 7.2] to 7.1 [6.6 to 7.6] at six months. Mean urinary citrate levels decreased with time from 890 mg/dl [630 to 1150 mg/dl] to 320 mg/dl [282 mg/dl to 368 mg/dl]. There was no significant change in the urinary levels of calcium and uric acids. The urinary pH and citrate levels are as depicted in the graph [Citrate levels equivalent to 1000 x the value in the graph].



**Figure 1:** Graph showing levels of Urinary pH and Citrate during the course of treatment from baseline. Citrate levels equivalent to the number in the graph X 100 in mg/dl

#### 4. Discussion

Topiramate, first introduced as an anti-epileptic has variously been used for weight reductions, alcohol dependence and binge eating disorders. Incidental observation of weight reduction in rodents stimulated its application for weight reductions. Usage of topiramate for seizure disorder also led to the discovery of its worrying adverse effect of causing urolithiasis in 1.5 % of individuals [5].

Topiramate leads to stone formation by inhibiting carbonic anhydrase at proximal tubule level similar to acetazolamide though in a less potent way. Inhibition of carbonic anhydrase at this level of renal tubule impairs exchange of  $H^+$  for  $Na^+$  and also to reduced  $HCO_3^-$  reabsorption [6]. Though the changes induced by topiramate are less compared to acetazolamide, increasing experience has shown, development of significant metabolic acidosis. It is well known that urinary citrate levels decrease dramatically with metabolic acidosis as well as with carbonic anhydrase inhibition [7] leading to reduced solubility of urinary calcium and urolithiasis. Our study corroborates the same, showing a linear decrease in urinary citrate with time and dose of topiramate which was similar to the study published by Warner BW *et al* [8].

Notably in our study, the stone analysis showed a predominance of Calcium Phosphate in four patients where the stone analysis was done. The same has been shown in other studies as well [9,10]. Topiramate was earlier believed to cause urolithiasis by a similar mechanism as in Type 1 Renal Tubular Acidosis, by inhibiting Carbonic anhydrase at proximal tubule.

As patients of RTA type 1 do not form urinary stones, Ramsay Kou *et al* postulated that there is failure of urinary acidification at distal renal tubule as well similar to that of RTA Type 2. In their study, one of the patients who had passed a calcium oxalate stone before, the composition of stone changed to predominantly Calcium phosphate

while being on topiramate which could be explained by patient's serum and urinary biochemistry.

#### 5. Conclusions

Topiramate usage leads to dramatic alteration in the milieu of renal tubules leading to effects similar to those due to renal tubular acidosis making the patients susceptible for urolithiasis. Since these are dose and time dependent, we suggest regular monitoring of Serum and Urinary biochemical parameters to determine the stone risk. We also suggest prophylactic usage of potassium citrate to offset the time dependent hypocitraturia in patients on Topiramate. However, we stress that further studies with better sample size are required to corroborate the findings of our study.

**Conflict of interest:** None to declare

**Consent:** Detailed informed consent was sought and obtained before enrolling the patient to make use of the data for the study.

#### References

- [1]. York, D. A., Singer, L., Thomas, S., Bray, G. A. Effect of topiramate on body weight and body composition of Osborne-Mendel rats fed a high-fat diet: alterations in hormones, neuropeptide, and uncoupling-protein mRNAs. *Nutrition* 2000; 16: 967–975.
- [2]. Reife, R., Pledger, G., Wu, S. C. Topiramate as add-on therapy: pooled analysis of randomized controlled trials in adults. *Epilepsia* 2000; 41(Suppl 1): S66–S71.
- [3]. Moradi S, Kerman SR, Mollabashi M. The effect of topiramate on weight loss in patients with type 2 diabetes. *J Res Med Sci.* 2013; 18(4): 297-302.
- [4]. Tonstad S, Tykarski A, Weissgarten J, Ivleva A, Levy B, Kumar A, *et al.* Efficacy and safety of topiramate

- in the treatment of obese subjects with essential hypertension. *Am J Cardiol.* 2005; 96: 243–51.
- [5]. Kou RL, Moran ME, Kim DH, Abraham HM, White MD, Lingeman JE. Topiramate induced nephrolithiasis. *J Endourol.* 2002; 16:229-31.
- [6]. Wasserstein AG, Rak I, Reife RA. Investigation of Mechanistic basis for topiramate associated Nephrolithiasis: Examination of urinary and serum constituents. *Epilepsia* 1995; 39 Suppl 3): S153.
- [7]. Welch BJ, Graybeal D, Moe O W, Maalouf N M, Sakhee Khashayar. Biochemical and Stone risk profiles with Topiramate treatment. *Am J Kidney Dis* 2006; 48(4): 555-563.
- [8]. Warren BW, La Grange CA, Tucker T, Bensalem-Owen M, Pais VM Jr. Induction of Progressive profound hypocitraturia with increasing dose of topiramate. *Urology* 2008; 72: 29-32.
- [9]. Wasserstein AG, Rak I, Reife RA. Nephrolithiasis during treatment with topiramate. *Epilepsia* 1995; 3(suppl 3): S153.
- [10]. Eggener S, Kim SC, User HM, Pazona J, Nadler RB. Urolithiasis associated with Topiramate. *Int Braz J Urol.* 2004; 30:29-31.