

International Journal of Biomedical Research

ISSN: 0976-9633 (Online); 2455-0566 (Print)

Journal DOI: <https://doi.org/10.7439/ijbr>

CODEN: IJBRFA

Original Research Article

Split face comparative study for efficacy of microneedling alone versus microneedling combined with Vitamin C in treating facial acne scars**Rajnish Chakrawarty¹ and Mahendra Kumar Jaiswal^{*2}**¹Department of Skin & V.D., Late B.R.K.M. Govt. Medical College, Jagdalpur (C.G.) 494001 India²Department of Pharmacology, Late B.R.K.M. Govt. Medical College, Jagdalpur (C.G.) 494001 India

QR Code

***Correspondence Info:**Dr. Mahendra Kumar Jaiswal
Assistant Professor,
Department of Pharmacology,
Late B.R.K.M. Govt. Medical College,
Jagdalpur (C.G.) India***Article History:****Received:** 31/10/2017**Revised:** 14/11/2017**Accepted:** 15/11/2017**DOI:** <https://doi.org/10.7439/ijbr.v8i11.4445>**Abstract****Background:** Microneedling a newer treatment modality for facial acne scars induces collagen production through mechanical stimulation of the dermis and leads to the softening of scars, realignment of collagen bundles and stimulation of new collagen. Topical vitamin 'C' have beneficial effect on acne and improves acne scarring when used in conjunction with glycolic acid peels and post-laser resurfacing.**Aims:** Split face comparative assessment of the efficacy of microneedling therapy versus microneedling therapy in conjunction with topical vitamin C in facial acne scars.**Materials and Methods:** This study was performed on 50 patients having facial acne scars after taking informed written consent. The face was divided into right and left half from midline. On the half of face only microneedling and on other side of face microneedling therapy with topical vitamin C (5% L-ascorbic acid) has been used. A total of three sessions at 4 weeks interval was done in each patient. Facial scars were assessed clinically to grade the severity of scarring, as per the ECCA grading system.**Results:** Gradual improvement in global score & acne scar types after each sitting of Microneedling as well as Microneedling + Topical Vitamin-C observed. Overall mean percentage improvement with Microneedling + Topical Vitamin-C was more than the mean percentage improvement with Microneedling alone.**Conclusion:** Microneedling shows significant clinical improvement in the 'M' type scars (rolling), and 'U' type scars (boxcar) and modest improvement in 'V' type scars (ice-pick). Effect of microneedling is enhanced by combining the procedure with application of topical vitamin 'C'.**Keywords:** Microneedling; Microneedling with vitamin c; Post acne scars; Split face study; Dermatology.**1. Introduction**

Acne vulgaris is a common chronic inflammatory disease of the pilosebaceous unit that is primarily seen in adolescent & young adult age group. It is characterized by spectrum of cutaneous lesion which may be non-inflammatory comedones (open & closed) & inflammatory papules, pustules, nodulocystic lesion. The severely inflamed or in certain cases the less severe inadequately treated acne may lead to scarring.[1]

Acne vulgaris is the most common cause of facial scar.[2] Broadly post-acne scars are classified into two category; atrophic & hypertrophic. Atrophic acne scar are further sub-classified into ice-pick, boxcar & rolling scar.[3] To standardized the evaluation of facial acne scars, Dreno *et al*[4] in 2006 formulated a grading scale. This Grading scale named ECCA (e'chelle d, evaluationchinique des lesion d, acne) involve description of acne scars into 2

subgrades. Subgrade 1 includes 'V' shaped (ice-pick) atrophic scar, 'U' shaped (boxcar) atrophic scar, 'M' Shaped (rolling) atrophic scar, superficial elastosis, while subgrade 2 includes hypertrophic scars & keloidal scars.

The modalities available for treatment of post-acne scars are various types of ablative and non-ablative resurfacing technique, use of dermal fillers[5,6] & surgical method such as dermabrasion[7], subcision[8,9], & punch elevation[10]. Microneedling using roller has been recently added in the treatment armamentarium in facial acne scars. Microneedle roller is a drum shaped roller studded with 192 fine microneedles in eight rows and 20mm wide.

The needle have varied length of 1.5-2.5mm and a diameter of 0.25 mm. Depending on the applied pressure, the needle penetrate the scar tissue between 0.1 and 1.3 mm. Rolling consists in moving, with some pressure, 4 times in 4 directions: horizontally, vertically, and diagonally right and left. This ensures an even pricking pattern resulting in about 250-300 pricks per cm².

It is hypothesized that, the needles pierce the stratum corneum and creates micro conduits (holes) without damaging the epidermis. This induces collagen production through mechanical stimulation of the dermis and leads to the softening of scars, realignment of collagen bundles and stimulation of new collagen.[11]

Also known by percutaneous collagen induction therapy, Fernades *et al* and others described neocollagenosis and neovascularisation as reasons responsible for substantial improvement of acne scars.[11,12]

Topical vitamin 'C' has been demonstrated to have beneficial effect on acne and improves acne scarring when used in conjunction with glycolic acid peels and post-laser resurfacing.[13] This beneficial effect may be due to its ability to enhance collagen production and also help to preserve existing collagen.[14]

Another possible mechanism responsible for beneficial effect is due to its well know potent anti-inflammatory activities through suppression of activation of NF-kb by inhibiting TNF alpha.[15]

Overall, the pertinent literatures regarding the use of microneedling therapy in facial acne scars are scarce from the Indian subcontinent. Furthermore, there are very

few studies on microneedling with topical vitamin 'C' in facial acne scars.

Also there is no study available on literature which compare the effectiveness of microneedling therapy and microneedling therapy with topical vitamin 'C' in facial acne scars. The aim of this study was to assess the efficacy of microneedling therapy in facial acne scars; to assess the usefulness of topical vitamin C when used in conjunction with microneedling therapy in facial acne scars and to compare both in split face.

2. Materials and methods

The present study was hospital based prospective cohort study conducted on patient having facial acne scars (skin phenotypes IV & V) attending the outpatient Department of Dermatology, Venereology & Leprosy, Vardhman Mahavir Medical College & Safdarjung Hospital, New Delhi.

2.1 Inclusion Criteria

- Patient with facial acne scars.
- Patient should not have used any acne scars revision therapy during the previous three months.

2.2 Exclusion Criteria

- Presence of any active acne lesion on the face.
- History of keloidal tendency.
- Systemic retinoids or immunosuppressive drug intake during the previous six month.
- Patient with any immunocompromised state.

The present study was performed on 50 patient having facial acne scars. The patient has been selected after detailed clinical examination, and history of prior acne lesion leading to development of acne scars has been carefully obtained. An informed written consent was obtained from all the patients who were enrolled for the study. Multiple photographs of the patient in the three different directions have been taken for each patient in comparable sitting. Facial scars were assessed clinically at the time of enrolment to grade the severity of scarring, as per the ECCA grading system.

The details are as follows:

Description	Weighting factor (b)	Semi quantitative score (b)	Grading (a x b)
V-shaped atrophic scars, diameter <2 mm & punctiform	15	0 = no scar 1 = few scar (<5) 2 = Limited no. of scars (between 5-20) 3 = many scars (>20)	
U-shaped atrophic scars, diameter of 2-4 mm, with seer edges	20	0 = no scar 1 = few scar (<5) 2 = Limited no. of scars (between 5-20) 3 = many scars (>20)	
M-shaped atrophic scars, diameter of >4 mm, superficial with irregular surface	25	0 = no scar 1 = few scar (<5) 2 = Limited no. of scars (between 5-20) 3 = many scars (>20)	
Superficial elastosis	30	0 = no scar 1 = few scar (<5) 2 = Limited no. of scars (between 5-20) 3 = many scars (>20)	
Sub grading 1			
Hypertrophic inflammatory scars, scars of 2<yrs. of age	40	0 = no scar 1 = few scar (<5) 2 = Limited no. of scars (between 5-20) 3 = many scars (>20)	
Keloidal scars, Hypertrophic scars, scars of > 2 yrs. of age	50	0 = no scar 1 = few scar (<5) 2 = Limited no. of scars (between 5-20) 3 = many scars (>20)	
Sub grading 2			
Global score (sub grading 1 + 2)			

The face was divided in right and left half from midline. On the right side of face only microneedling and on left side of face microneedling therapy with topical vitamin C (5% L-ascorbic acid) has been used. Microneedling using roller with needle size 1.5mm (in length) has been done 4 times in each horizontal, vertical and oblique direction. The end point for any treatment session was the presence of uniform pinpoint bleeding over the scar area. Patient was advised topical antibiotic application for 2-3 days and sun protection for at least 1 week after microneedling therapy.

A total of three sessions of microneedling therapy and microneedling therapy with topical vitamin 'C' at 4 weeks interval was done in each patient. The patient was assessed carefully for clinical improvement of acne scars using same grading scale and fresh photograph on each visit, before the next session is conducted. After the completion of the treatment period of 12 weeks, patients

was followed for one month. The final assessment and global scoring of scars was done after one months of completion of treatment regimen. Follow up photographs has been taken and the appearance and global scoring of scars was compared with previous photograph.

Data were coded entered using SPSS version 17 (SPSS, Inc., Chicago, IL). Data were summarized using mean \pm standard deviation for qualitative variables and percentages for qualitative variables. Comparison between groups were made using parametric test (e.g., Paired t-test). Correlation was done to test linear relation between quantitative variables. $p < 0.05$ was considered significant.

3. Results

This study included 50 patients from various age groups comprising of 46% male and 54% female patients. A maximum of around 26.00% patients were from age of 25 years.

Table 1: Patient demographic data

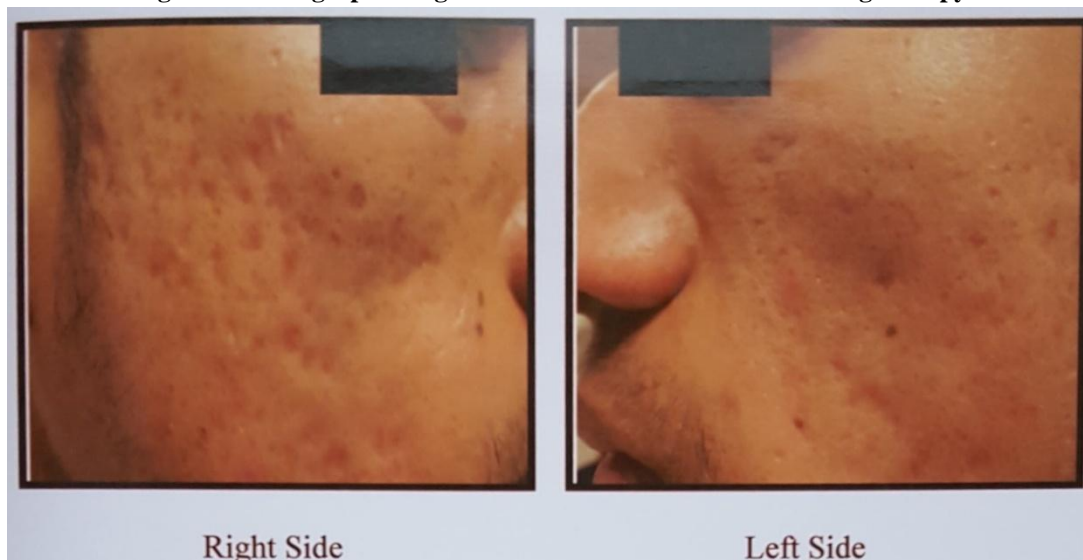	Characteristics	Frequency (n=50)	Percentage
Gender	Male	23	46.00
	Female	27	54.00
Age (Years)	21	2	4.00
	22	4	8.00
	23	12	24.00
	24	6	12.00
	25	13	26.00
	26	6	12.00
	27	5	10.00
	28	2	4.00
Duration of Scar (Years)	1	2	4.00
	2	5	10.00
	2-3	16	32.00
	3-4	17	34.00
	3	2	4.00
	4-5	6	12.00
	5-6	2	4.00

In our study, patients with different types of atrophic acne scars were included for split face (Left and Right). No statistically significant difference was found between the left and right side regarding overall scar severity before treatment.

Table 2: Comparison data before and after every sitting of Microneedling Vs Microneedling + Topical Vit. 'C'

Parameter	Mean percentage improvement with						
	Microneedling alone			Microneedling + Topical Vit. 'C'			
	First sitting	Second sitting	Third sitting	First sitting	Second sitting	Third sitting	
Global score	15.00	22.47	44.72	18.99	25.81	70.67	
Acne Scar Type	V-shaped scar	6.00	14.33	28.67	11.00	19.67	38.00
	U-shaped scar	11.33	19.33	63.33	16.67	25.33	77.33
	M-shaped scar	17.33	22.33	71.33	22.33	27.33	81.33

There was gradual improvement in global score & acne scar types after each sitting of Microneedling as well as Microneedling + Topical Vitamin-C. Overall mean percentage improvement with Microneedling + Topical Vitamin-C was more than the mean percentage improvement with Microneedling alone.

Figure 1: Photograph of right and left side of face before starting therapy**Figure 2: Photograph of right and left side of face after 1st sitting of therapy.**

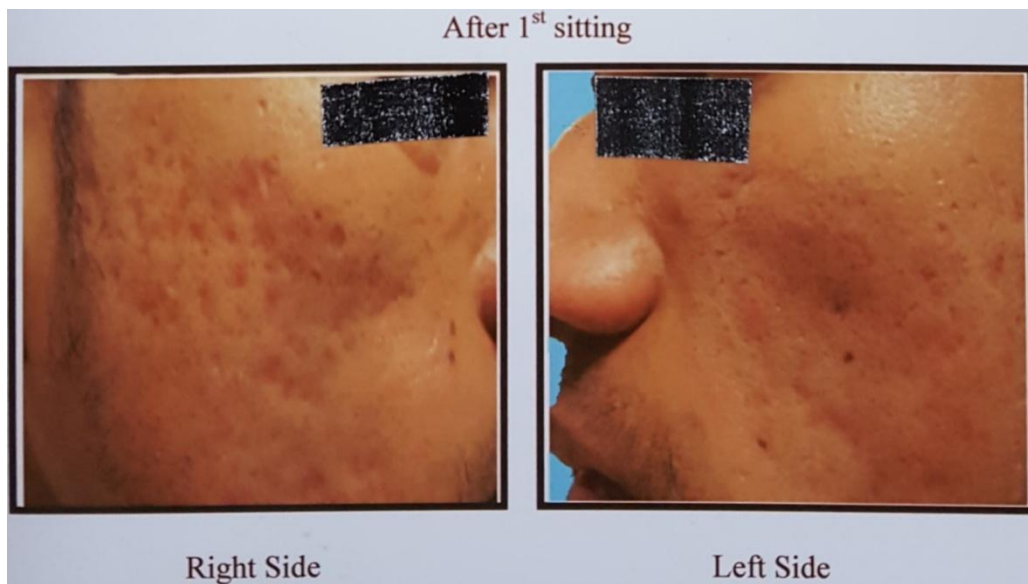


Figure 3: Photograph of right and left side of face after 2nd sitting of therapy.

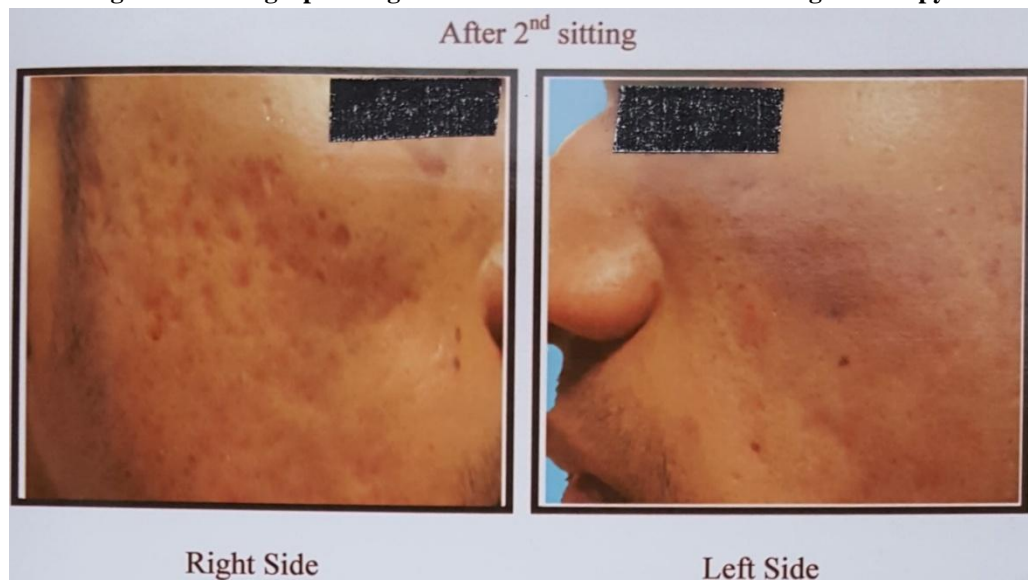
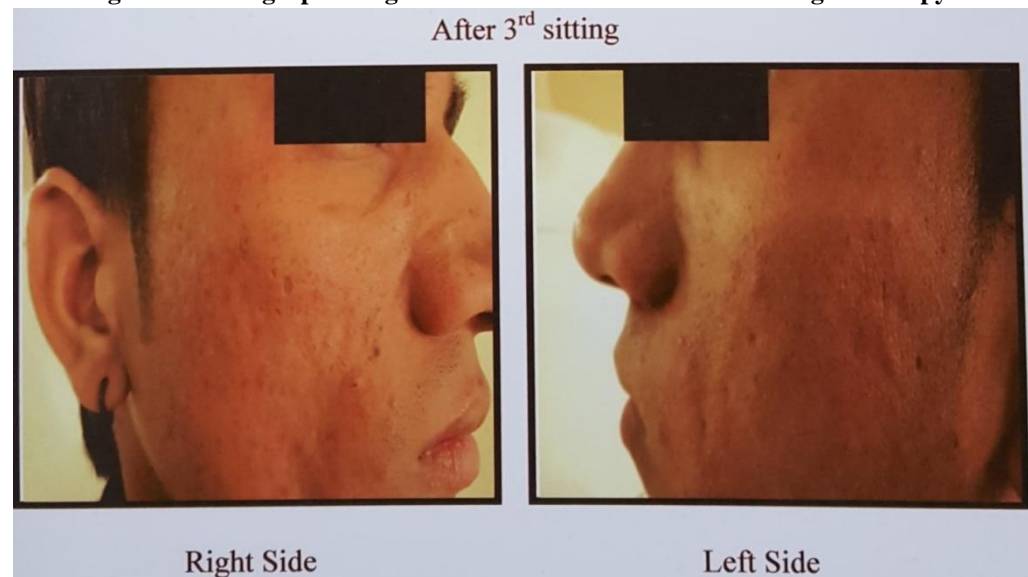
Figure 4: Photograph of right and left side of face after 3rd sitting of therapy.



There was no side effect like post-inflammatory hyper pigmentation or photosensitivity recorded in this study.

4. Discussion

Present study revealed that microneedling done on the right side of face lead to improvement of atrophic acne scars in significant way. This is evident by improvement in the mean percentage global score. In this study, after the 1st sitting i.e. at the end of the 1st month mean percentage global score was 15.00% which increased to 44.72% 1 month after 3rd sitting. We speculate that the maximum improvement seen after the 3rd sitting may be attributed to the collagen laying process which is initialized by the microneedling procedure done at 2 week intervals. Similar finding were reported by Aust and colleagues [12] in their retrospective analysis of 480 patients, who were treated with microneedling for the treatment of fine wrinkles, lax skin, scarring and stretch mark and showed clinical improvement between 60% and 80%.

In this study the different type of acne scars showed variable improvement after microneedling. The mean percentage improvement 1 month after the 3rd sitting of microneedling procedure for 'V' shaped scars (ice-pick) was 28.67%, for 'U' type scars (boxcar) 63.33% and for 'M' type scars (rolling) scar was 71.00%. Maximum improvement was thus seen in 'M' type (rolling) scar and good improvement in 'U' type (boxcar) scar. Least response of microneedling procedure was seen in 'V' type scar (ice-pick). This may be explained due to the depth of 'V' type scars which extend vertically to the microneedling process. Our result were consistent with a previously published studies carried out by Fabbrocini *et al*[16], Leheta *et al*[17] and I Majid[18].

Microneedling on the left side of the face was carried out with topical vitamin 'C' (5% L-Ascorbic acid) in this study. The improvement in the acne scars as per the mean percentage global score was 70.67% after the 3rd sitting. This was significantly better than the mean percentage global score seen on the right side of the face. The different type of acne scars showed variable improvement after the 3rd sitting of microneedling procedure for 'V' shaped scars (ice-pick) was 38.00%, for 'U' type scars (boxcar) 77.33% and for 'M' type scars (rolling) was 81.33%. The global score and every type of atrophic acne scar on the left side of the face showed 10-25% more mean percentage improvement than the right side of the face. The discrepancy between the two sides can be explained by the ability of topical vitamin 'C' to enhance the collagen production and help in maintenance of the existing collagen. This has been demonstrated in the study carried out by Fernades *et al*[11], wherein they showed that microneedling with preoperative topical vitamin 'C' application leads to improvement of wrinkle and scars between 60-80%.

The results revealed an overall improvement of atrophic acne scars on both sides of the face. The improvement seen on the left side of face (microneedling with topical vitamin 'C') was significantly higher as compared to the right side of face (only microneedling) ($p < 0.05$). Fernades[11] showed that collagen induction technique (CIT) had undisputable advantage compared with the usage of conventional methods for the treatment of acne scars.

The distinct advantage offered by microneedling is that the epidermis remains intact, thereby, eliminating the risk and unwanted side effect of ablative laser resurfacing and chemical peeling. The decreased risk of photosensitivity, post inflammatory hyperpigmentation, and the decreased downtime associated with the microneedling procedure, makes it promising therapy for the management of atrophic acne scars.

5. Conclusion

Microneedling is a simple, inexpensive, relatively nonablative office based method for the treatment of atrophic acne scars. Microneedling shows significant clinical improvement in the 'M' type scars (rolling), and 'U' type scars (boxcar) and modest improvement in 'V' type scars (ice-pick). Effect of microneedling is enhanced by combining the procedure with application of topical vitamin 'C'. There is enough evidence to confirm the usefulness of topical vitamin 'C' in increasing collagen synthesis, thereby helping in the management of atrophic acne scars. Microneedling appears to be suitable therapy for acne scars in skin type (IV-V) and patients with history of post-inflammatory hyperpigmentation.

References

- [1]. Gollnick H, Unilife W, Berson D, *et al*, Global alliances to improves outcomes in acne, management of acnes & report from global alliances to improves outcomes in acnes: *J Am Acad Dermatol* 2003; 49(s.1): S1 – S.37.
- [2]. Shambon A T & Naurakar V A; Multimodal treatment of acne, acne scars & pigmentation; *Dermatol Clinics*; 2009; 27 (3): 459-71.
- [3]. Jacob C.I. *et al*; Acne Scarring: A classification system & review of treatment option; *J Am Acad Dermatol* 2001; 45: 109-117.
- [4]. Dreno B. *et al*; ECCA Grading scale; An original validated acne scar grading scale for clinical practices in Dermatology; *J Am Acad Dermatol*; 2007; 214; 46-51.
- [5]. Klein AW. Implantation technique for injectable collagen. *J Am Acad Dermatol* 1983; 9: 224-8.

- [6]. Selmanowitz WJ, Orentreich N. Medical grade fluid silicone: a monographic review. *J Dermatol Surg Oncol* 1977; 3:597-611.
- [7]. Aronsson A, Errifsson T, Jacobsson S *et al.* Effect of dermabrasion on acne scarring: a review and study of 25 cases. *Acta Dermatol* 1997; 77: 39-42.
- [8]. Orentreich DS, Orentreich N. subcutaneous incisionless (subcision) surgery for the correction of depressed scars and wrinkles. *Dermatol Surg* 1995; 21: 543-9.
- [9]. Chandrashekhar BS, Nandini AS. Acne scar subcision. *J Cut aesth Surg* 2010; 3(2): 125-126.
- [10]. Arouete J. Correction of depressed scar on the face by a method of elevation. *J Dermatol Surg Oncol* 1976; 2: 337-9.
- [11]. Fernades D. Minimally invasive percutaneous collagen induction. *Oral Maxillofac. Surg. Clin North Am* 2006; 17: 51-63.
- [12]. Aust MC, Fernades D, Kolokythas P *et al.* Percutaneous collagen induction therapy; an alternative treatment for scars, wrinkles & skin laxity; *Plast. Reconstr. Surg.* 2008; 21: 1421-29.
- [13]. Alster TS, West T; Effect of topical vitamin C on postoperative laser resurfacing erythema; *Dermatol Surg* 1998; 24; 331-334.
- [14]. Farris P K; Topical vitamin C: A Useful agent for treating photoaging & other Dermatologic conditions; *Dermatol Surg* 2005; 31:7(2):132-13.
- [15]. Carcamo JM, Pedrezza A, Borquez- Ojeda O *et al.* Vitamin C suppress TNF alpha - induced NF kappa B activation by inhibiting I kappa B alpha phosphorylation. *Biochemistry* 2002; 41; 12995-13002.
- [16]. Fabbrocini G, Chu AC, Brazzini B *et al.* Percutaneous Collagen Induction Therapy: A New treatment for Acne scarring; *J Am Acad Dermatol*; 2010; 62(3): S. AB 17.
- [17]. Leheta *et al.* Percutaneous collagen induction vs full-concentration 100% TCA in the treatment of atrophic acne scars. *Dermatol Surg* 2011; 37: 207-216.
- [18]. Majid I. Microneedling therapy in atrophic facial scars; An Objective assessment. *J. Cut. & Aesth. Surg.* 2009; 2; 26-30.