

**International Journal of Biomedical Research**

ISSN: 0976-9633 (Online); 2455-0566 (Print)

Journal DOI: <https://doi.org/10.7439/ijbr>

CODEN: IJBRFA

**Case Report****Recurrent florid vulval warts in a human Immunodeficiency virus reactive patient: Excision****Shambe I.H.\*** and Obu C.*Department of Obstetrics and Gynaecology, University of Jos, Jos Nigeria*

QR Code

**\*Correspondence Info:**

Dr. Iornum Hembe Shambe  
 Department of Obstetrics and Gynaecology,  
 University of Jos, Jos Nigeria

**\*Article History:**

Received: 08/09/2017

Revised: 07/10/2017

Accepted: 07/10/2017

DOI: <https://doi.org/10.7439/ijbr.v8i10.4383>**Abstract**

Anogenital warts are caused by the Human Papilloma Virus (HPV). They are usually more common in Human Immunodeficiency Virus (HIV) infected people than uninfected people and are often very difficult to treat. The authors report a case of recurrent florid vulval warts in an HIV positive patient to illustrate such difficulties in management with the limitations of practice in a developing country.

**Keywords:** Genital warts, HIV, vulval warts.**1. Introduction**

Genital warts are found in sexually active adults but more commonly in HIV infected persons than non-infected persons.[1,2] Those who are HIV positive also have a higher risk of recurrence. [2] They can also present in pregnancy and in women with other forms of immunosuppression other than HIV. They generally have a typical appearance and can be diagnosed clinically. The incidence in Nigeria is reported to be 2.7 per 1000 women.[3] Treatment may be surgical excision or medical with application of podophylin or 5 Fluorouracil. Where there is no background immunosuppression, the lesions may also spontaneously resolve.[3]

Although the HPV types that cause genital warts are the low risk types that are not associated with the risk of malignancy, the presence of one HPV makes a patient makes a patient more likely to have another type including the high risk types which are associated with vulval, cervical and anal neoplasias.[4] We report a case of recurrent vulval warts in an HIV positive woman that

offensive odour and contact bleeding. She had surgical excision of the mass 4 years before presentation at a private clinic in Abuja only for the growth to reoccur one year later. She had used topical podophylin but stopped because she experienced severe burning pains on surrounding unaffected skin with the use of podophylin that persisted even when she used petroleum jelly before application of the cream. She had been using herbal medications also with no improvement. She had been diagnosed HIV positive 3 years before presentation at the hospital where the vulval growth was excised and was on Highly Active Antiretroviral Therapy. He was unable to remember the names of the drugs.

Examination revealed a young woman who was not wasted. Her pulse rate was 84 beats per minute and the blood pressure was 110/70mmHg. She had a florid vulval tumour that had a cauliflower appearance and a malodourous smell measuring 30cm by 20cm. (Figure 1)

An assessment of vulval warts in a known HIV positive patient was made. Her Packed Cell Volume was 41%, Blood group was O Rhesus positive and the Urea, electrolytes and Creatinine values were within normal limits. Her CD4 count was 1,100cells per/mm<sup>3</sup>.

**2. Case Report**

A single 25 year old nulliparous woman presented at the gynaecology clinic with a 10 year history of a progressive vulval growth that was associated with an

She was counselled about the diagnosis, admitted and prepared for excision of the vulval warts.

Intraoperative findings were a large warty vulval growth 30cm by 20cm in diameter involving the vaginal introitus but with anal involvement and no cervical spread. The inner thighs were also not affected. The skin wound was closed subcuticular vicryl 2/0. She had antibiotic therapy with Intravenous ceftriaxone 1g 12hly and Metronidazole 500mg 8hly for 48hours. Analgesia was achieved with intramuscular Pentazocine 60mg 4hourly for 48hrs. She made a satisfactory recovery and was discharged 6 days later. She was reviewed 2 weeks later at the gynaecology clinic with the histology report that confirmed vulval warts with no evidence of malignancy. A papanicolau smear showed no evidence of a premalignant cervical lesion.

### 3. Discussion

Vulval warts are also known as condylomata acuminata are sexually transmitted lesions caused in 90% of cases by HPV types 6 and 11. They are common in anatomic sites like the introitus in women but may also be seen in the foreskin of uncircumcised men or the shaft of the penis but they can be found anywhere along the Anogenital epithelium or tract often at multiple sites such as the cervix, vagina or urethra.[5] These warts commonly spread by expansion and have a rich blood supply.[6] The causative agent HPV is highly transmissible through genital, anal and oral contact with some instances of vertical transmission during passage of a baby through the birth canal.[7]

The lesions are commoner in immunocompromised patients such as those with HIV and HTLV with occasional rapid growth in pregnancy [8]. In the presented case, the HIV infection is the likely reason for the florid nature of vulval warts as well as the recurrence following the initial excision.

Treatment options for vulval warts are aimed at addressing cosmetic concerns as the warts appear unsightly, They include medical as well as surgical options and should be guided by available resources, patient preference and experience of the health care provider. Factors that also influence the choice of treatment are the size of the warts and the anatomical location. The patient applied medical options are 0.5% Podophylin solution or gel, 5% imiquinod and 15% Sinetachins. Other options are Trichloroacetic acid (TCA) and cryotherapy with liquid nitrogen or cryoprobe, surgical excision as was done in the presented case is also an option.[5]

This patient was not tolerating podophylin use however and preferred not to use it even when the lesions

were smaller instead opting for traditional herbs before her presentation at our facility.

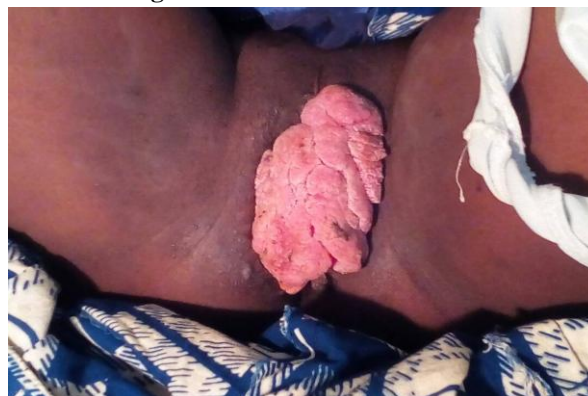Podophylin is an inexpensive option particularly for smaller lesions whose total area should not exceeded 10cm<sup>2</sup>. It is an antimetabolic agent that is self-applied to visible warts over 3 days followed by 4 therapy free days. Sinocatechins are green tea extracts that are not recommended in immunocompromised patients.[5]

This patient had a vulvectomy and had a good outcome after which she had a pap smear because of the risk of co infection with high risk HPV types that could later lead to cervical cancer. Early presentation when the lesions were smaller in size may have made the medical options more feasible.

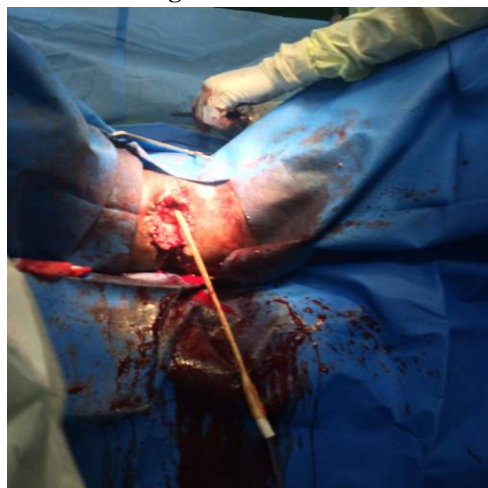### 4. Conclusion

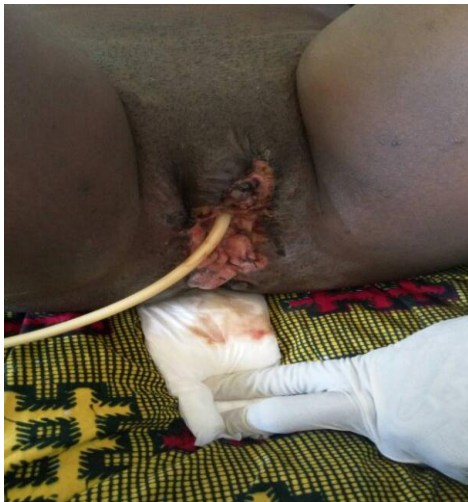
Vulval warts are lesions that can be diagnosed clinically by their cauliflower appearance. They are commoner in immunocompromised patients such as those with HIV. Medical management with podophylin is suited for smaller warts but florid warts such as in the presented case often need surgical excision.

**Figure 1: florid vulval tumour**



**Figure 2: Intra OP**



**Figure 3: Post operative**

## References

- [1]. Koutsky L.A, Galloway D. A. Holmes K.K. Epidemiology of genital Human Papilloma Virus infection. *Epidemiol Rev.* 1988; 10:122-163.
- [2]. Minkoff H.L, Eisenberger-Matityahu D., Feldman J., Prevalence and Incidence of gynecologic disorders among women infected with Human Immunodeficiency Virus. *Am J Obstet Gynecol.* 1999; 180: 824-836.
- [3]. Ozumba B.C, Megafu U. Pattern of Vulval warts at the University of Nigeria teaching hospital, Enugu. Nigeria. *Int J Gynaecol Obstet* 1991; 34: 347-352.
- [4]. Carter P.S., de Ruitter A, Whatrup C. Human Immunodeficiency Virus infection and genital warts as risk factors for anal epithelial neoplasia in homosexual men. *Br J Surg.* 1995; 4: 473-474.
- [5]. Genital warts. 2010 STD Treatment guidelines. Available at [www.cdc.gov/std/treatment](http://www.cdc.gov/std/treatment). Accessed 7<sup>th</sup> September 8, 2017.
- [6]. Nwokedi EE, Ochicha O, Mohammed AZ, Florid Anogenital *condylomata acuminata* in a male African. A case report. *African Journal of Clinical and Experimental Microbiology* 2006; 7: 139-142.
- [7]. Scheinfeld N, Lehman DS. An evidence based review of medical and surgical treatments of genital warts. *Dermatol Online J.* 2006; 12(3): 5.
- [8]. Basita CS, Atallah AN, Saconato H, da Silva EMK. 2010 5 FU for Genital warts in non immunocompromised individuals. In: Cochrane Data base of Systematic Reviews. John Wiley and Sons, Ltd, USA.