

## Neutral Zone- A Clinical Report

Ankit Suhag<sup>1</sup>, A. K Verma<sup>1</sup>, Mariyam Ali<sup>1</sup>, Nishant Gaba<sup>\*2</sup>, Saurabh<sup>1</sup> and Deepika Yadav<sup>3</sup>

<sup>1</sup>Department of Prosthodontics, Career Dental College, Lucknow, Uttar Pradesh, India

<sup>2</sup>Department of Prosthodontics Inderprastha Dental College and Hospital, Ghaziabad, Uttar Pradesh, India<sup>3</sup>Department of Conservative and Endodontics, NIMS Dental College, Jaipur, India

### \*Correspondence Info:

Dr. Nishant Gaba,

Senior Lecturer,

Department of Prosthodontics,

Inderprastha Dental College and Hospital, Ghaziabad, Uttar Pradesh, India

E-mail: [nishant\\_gaba08@yahoo.com](mailto:nishant_gaba08@yahoo.com)

### Abstract

Edentulism from a long term results in high resorption of lower edentulous ridge which often pose a problem in stability of mandibular complete dentures. It is a challenge for a prosthodontist to rehabilitate those patients to near normal function, irrespective of the clinical picture. This paper presents neutral zone technique in a functional approach to overcome the problem of instability of lower dentures caused in patients by a more potential musculature.

**Keywords:** Neutral Zone, Poor Neuromuscular Coordination, Over Musculature.

### 1. Introduction

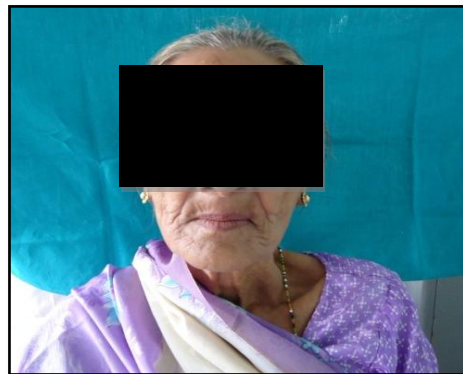All oral functions, such as speech, mastication, swallowing, smiling, and laughing, involve the synergistic actions of the tongue, lips, cheeks, and floor of the mouth which are very complex and highly individual. The coordination of complete dentures with the neuromuscular function is the foundation of successful, stable denture.[1] If dentist fails to recognize the correct tooth position and proper flange position then it creates more problems to the patient rather than without complete dentures. The unstable lower complete denture is a continuing problem for our profession.[2] Incorrect tooth placement and arbitrary shaping of the polished surfaces may have an adverse effect on the success of the prosthesis.

The neutral zone is the potential space between the lips and cheeks on one side and the tongue on the other, that area or position where the forces between the tongue and cheeks or lips are equal.[3]

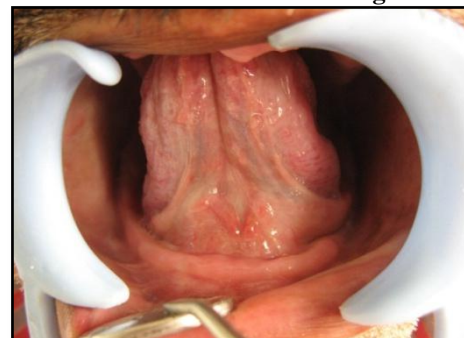Many materials have been suggested for shaping the neutral zone: modelling plastic impression compound, soft wax, a polymer of dimethyl siloxane filled with calcium silicate, silicone, and tissue conditioners and resilient lining materials. In the present case report, speech technique located the neutral zone, with the help of Mac-cord impression material.

### 2. Case Report

A female patient aged about 62 years reported with a completely edentulous and severely resorbed mandibular ridge (Figure 1).



**Figure-1: Patient with edentulous and severely resorbed mandibular ridge**

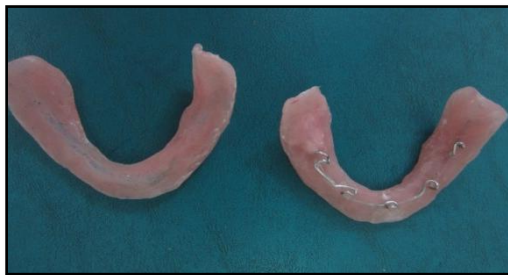

**Figure 2: Severely resorbed mandibular ridge**

Here, in this case report the management of a mandibular resorbed ridge with neutral zone technique using admixed impression material i.e.7:3 ratios of low fusing impression compound and high fusing impression compound has been described.

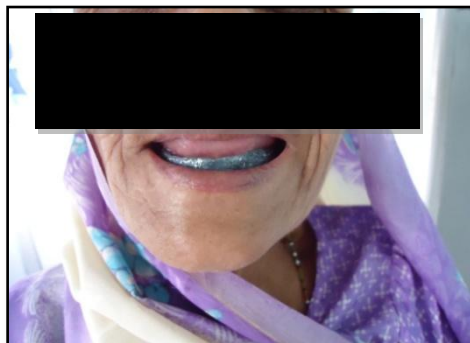Primary impressions of the upper jaw and lower jaw were made with impression compound and the model was poured.

Maxillary final cast was fabricated by the conventional manner but as lower ridge was highly resorbed, recording of neutral zone was planned to record that, denture base was fabricated with wire loops embedded in it for holding the admixed impression material during al movements. (Figure3)



**Figure 3: Denture base was fabricated with wire loops**

The lower special tray with the softened admixed compound in a 65o C water bath. was placed in the patient’s mouth; this tray was very carefully adjusted in the mouth to be sure that it was not overextended and remained stable during opening, swallowing, and speaking. The patient was then asked to talk and pronounce mainly three sounds i.e. aaa, eee, ooo, swallow, drink some water, etc. fig.4 a, b, c, d



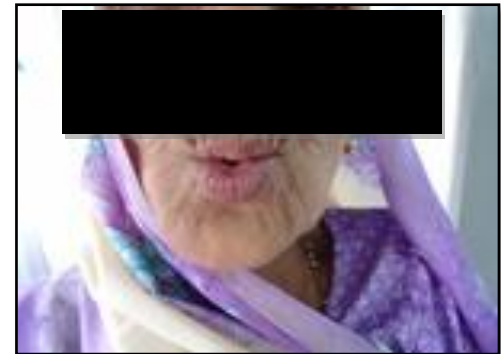**Figure 4(a): Pronouncing sound aaa**



**Figure 4(b): Pronouncing sound eee**

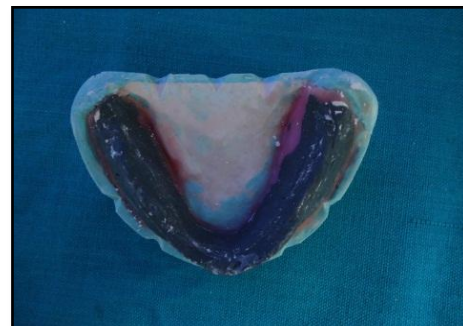

**Figure 4(c): Drinking**



**Figure 4(d): Pronouncing sound ooo**

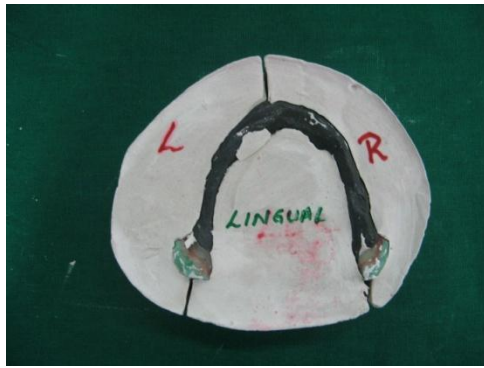
After 5–10 min, the set impression was removed from the mouth and examined. (Figure 5)



**Figure 5: Set impression**

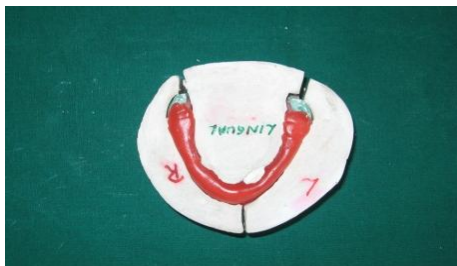The internal and external muscle groups have been brought into play, moving them through their respective action paths. In doing so, reciprocating pressures have been exerted upon the compound, which had gradually molded into a state of neutral balance and become centrally inert in relation to all of the complex forces acting upon it. After a tentative vertical dimension and centric relation have been established, the final impression was made with a closed- mouth procedure. Only when the final impressions were completed were the occlusal vertical dimension and centric relation finally determined.

The neutral zone impression so obtained was placed on master model, location grooves were cut on the Master cast and was covered with a dental plaster index around the impression on both the labial and lingual sides. (Figure 6)

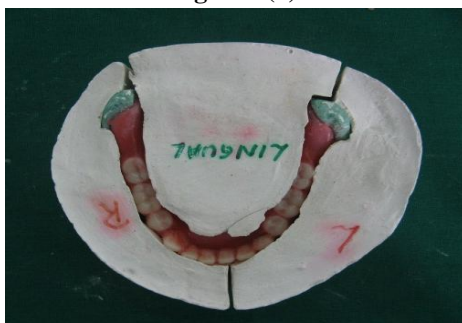

**Figure 6: The neutral zone impression so obtained was placed on master model**

The denture base withholding the recorded neutral zone material was removed from index and new denture base was fabricated and wax rim was fabricated according to the index and teeth were arranged exactly following the dental plaster index. (Figure 7 a,b)

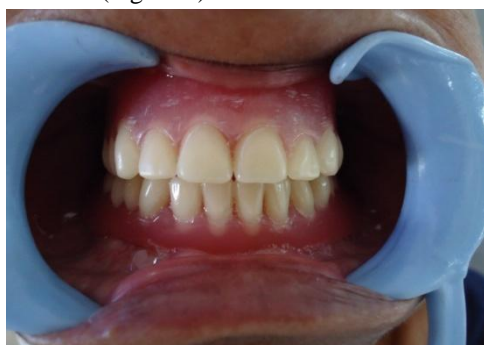

**Figure 7(a)**



**Figure 7(b)**

The position of the teeth was checked by placing the index together around the wax try-in. Once the waxed up dentures were ready, they were checked in the patient's mouth for esthetics, phonetics and occlusion. Once the try in was deemed satisfactory, the dentures were processed, finished and inserted. (Figure 8)



**Figure 8(a):**



**Figure 8(b):**

### 3. Discussion

Main dislodging factors for the mandibular dentures are all normal physiologic movements such as speech, mastication, swallowing, smiling, and laughing. Hence, the denture fabricated must be in harmony with all these movements. Conventional methods used for these patients result in denture contours that may not facilitate prosthesis stability against expected oral and perioral muscle function. This may lead to ill fitted prosthesis which might be improper and uncomfortable for the patient. From the technique illustrated in the paper we came to know that, whatever the materials are used, it seems that two factors cannot be overlooked: The impression of the neutral zone must be recorded at the occluso-vertical dimension determined at a previous visit using an occlusal rim. The material should be reasonably slow setting to permit the oral musculature to shape it to the appropriate contour and dimensions.

### 4. Conclusion

Neutral zone technique the best alternative techniques in case of highly resorbed mandibular residual ridge other than implant supported dentures, but it is rarely used because of the extra clinical step involved and complexity. Complete and partial denture failures are often related to non-compliance with neutral zone factors. Thus the neutral zone must be evaluated as an important factor before one rates any changes in arch form or alignment of teeth.

### References

- [1] Beresin VE, Schiesser FJ. The neutral zone in complete dentures. *J Prosthet Dent* 1976; 36(4):356-67.
- [2] The glossary of prosthodontic terms. *J Prosthet Dent* 2005; 94:10-92.
- [3] Russell AF. The reciprocal lower complete denture. *J Prosthet Dent* 1959; 9(2):180-190.

- [4] Makzoumé JE. Morphologic comparison of two neutral zone impression techniques: A pilot study. *J Prosthet Dent* 2004; 92(6):563-8.
- [5] Tinker A. Ageing in the United Kingdom — what does this mean for dentistry? *Br Dent J* 2003; 194(7): 369–372.
- [6] Beresin VE, Schiesser FJ. The neutral zone in complete and partial dentures. Mosby Co., Page 15; ed 2: 1978.
- [7] Basker RM, Harrison A, Ralph JP. A survey of patients referred to restorative dentistry clinics. *Br Dent J* 1988; 164(4):105–108.
- [8] Atwood DA. Post extraction changes in the adult mandible as illustrated by micrographs of midsagittal sections and serial cephalometric roentgenograms. *J Prosthet Dent* 1963; 13(5):810–824.
- [9] Ohkubo C, Hanatani S, Hosoi T, Mizuno Y. Neutral zone approach for denture fabrication for a partial glossectomy patient: A clinical report. *J Prosthet Dent* 2000; 84(4):390–393.
- [10] Fish EW. An analysis of the stabilizing factors in full denture construction. *Br Dent J* 1931; 52:559–570.
- [11] Fish EW. Using the muscles to stabilize the full lower denture. *J Am Dent Assoc* 1933; 20:2163–2169.
- [12] Lott F, Levin B. Flange technique: an anatomic and physiologic approach to increased retention, function, comfort and appearance of dentures. *J Prosthet Dent* 1966; 16(3):394–413.
- [13] Fahmi FM. The position of the neutral zone in relation to the alveolar ridge. *J Prosthet Dent* 1992; 67(6):805–809.