
Sarcomatous lesions of Mediastinum - An uncharted territory: A tale of two case reports

Soham Chakraborty^{*1}, Sanghamitra Mukherjee¹, Manisha Mahata¹, Rajarshi Gayen²,
Nabanita Chakraborty³ and Tushar Kanti Das¹

¹Department of Pathology, R. G. Kar Medical College, 1, Khudiram Bose Sarani, Kolkata – 700004, West Bengal, India

²Department of General Surgery, Midnapore Medical College, Vidyasagar Road, Midnapore, Dist – Paschim Medinipur, West Bengal, India

³Department of Anatomy, R. G. Kar Medical College, 1, Khudiram Bose Sarani, Kolkata – 700004, West Bengal, India

***Correspondence Info:**

Dr. Soham Chakraborty,
Resident,
Department of Pathology,
R. G. Kar Medical College, 1, Khudiram Bose Sarani,
Kolkata – 700004, West Bengal, India,
E-mail: soham85rgkmc@yahoo.co.in

Abstract

Various primary and metastatic malignant lesions can occur in the mediastinum and may cause diagnostic dilemmas in achieving definitive diagnosis. Synovial sarcoma is a malignant neoplasm predominantly affecting soft tissues of the extremities of adolescents and young adults. Its occurrence as a primary neoplasm in mediastinum is rare. Ewing's sarcomas are also rare high grade malignant neoplasms that predominantly affect children and young adults and involve the major long bones, pelvis, and ribs. Primary mediastinal Ewing's sarcoma is extremely rare. We, hereby, present two unusual cases of sarcoma in mediastinum. First case was a 62 year old male patient presented with chest pain and cough. Microscopic examinations of the resected mediastinal tumor showed areas of epithelial differentiation with well-formed glandular spaces intimately admixed with monotonous population of plump spindle-shaped cells confirming the diagnosis of synovial sarcoma. Another case of 23 years old male patient presented with chest pain and cough. Microscopic examinations of the mediastinal mass revealed presence of a tumor tissue composed of sheets and nests of small round cells with hyperchromatic nuclei and scanty cytoplasm. Histopathological diagnosis of Ewing's sarcoma was made. In conclusion, it can be said that mediastinum could be rarest of the rare locations for primary sarcomas – our search for literature also revealed very few cases across the globe which imparts further credence to the true rarity of the neoplasm. Early management by the oncologist may be hindered further owing to diverse differential diagnosis unless surgical pathologists undertake a cautious pragmatic approach.

Keywords: Mediastinal sarcomas, synovial sarcoma, Ewing's sarcoma.

1.Introduction

The mediastinum is a site where various primary and metastatic tumors can arise which can pose diagnostic dilemmas in clinching definitive diagnosis.

Synovial sarcoma is a malignant neoplasm predominantly affecting the soft tissues of the extremities of adolescents and young adults [1]. This neoplasm has been described in a wide variety of locations. Although synovial sarcoma has been reported to metastasize to the mediastinum [2], its occurrence as a primary neoplasm in this location is

rare. On the other hand Ewing's sarcomas are high grade relatively rare malignant neoplasms that predominantly affect children and young adults and involve the major long bones, pelvis, and ribs. Primary mediastinal Ewing's sarcoma and peripheral primitive neuroectodermal tumor (ES/PNET) are extremely rare [3]. We, hereby, present two unusual cases of sarcoma in mediastinum which ought to be remembered by surgical pathologist and oncologist for diagnosis and management protocol.

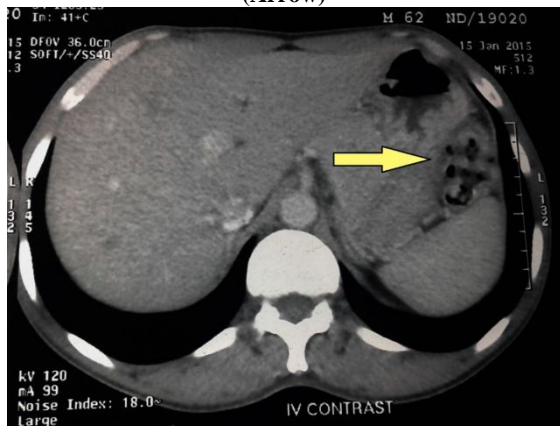2. Case reports

2.1 Case 1

A 62 year old male patient turned up in the OPD with the complaints of left sided chest pain and cough for two months. He also complained of gradually increasing shortness of breath and generalized weakness for same duration.

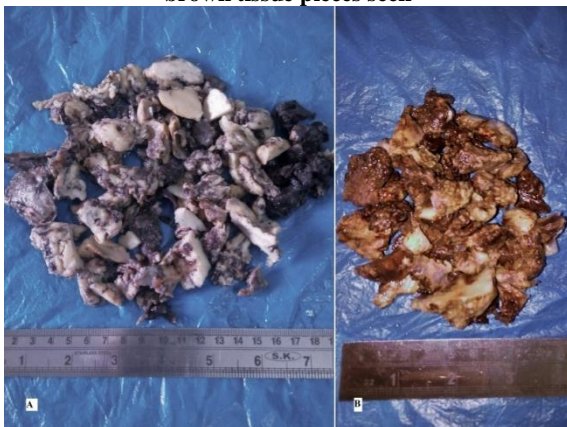A contrast enhanced CT scan of chest revealed the presence of a well-circumscribed, heterogeneously enhancing mixed attenuating lesion at the middle mediastinum, measuring 9x8x6 cm. [Figure 1].

Figure 1: CECT scan of chest (case 1) showing presence of a well-circumscribed, heterogeneously enhancing mixed attenuating lesion at the middle mediastinum (Arrow)



Left thoracotomy was performed followed by debulking of the tumor, and the specimen was sent for histopathological examination. On gross examination, multiple greyish white tissue pieces seen, altogether measuring 15x13x3 cm. [Figure 2A]. Multiple tissue sections were embedded from different parts, and stained with Haematoxylin and Eosin stain.

Figure 2: A: On gross examination (case 1), multiple greyish white tissue pieces seen. B: On gross examination (case 2), multiple fragmented greyish brown tissue pieces seen

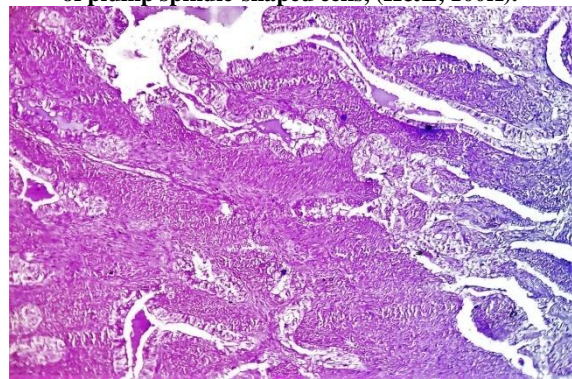


Microscopic examinations showed areas of epithelial differentiation with well-formed glandular spaces intimately admixed with monotonous

population of plump spindle-shaped cells having significant nuclear atypia and prominent hemangiopericytoma-like vascular pattern confirming the diagnosis of biphasic synovial sarcoma [Figure 3].

Patient was referred to the department of oncology and now undergoing therapy.

Figure 3: Photomicrograph (case 1) showing areas of epithelial differentiation with well-formed glandular spaces intimately admixed with monotonous population of plump spindle-shaped cells, (H&E, 100X).

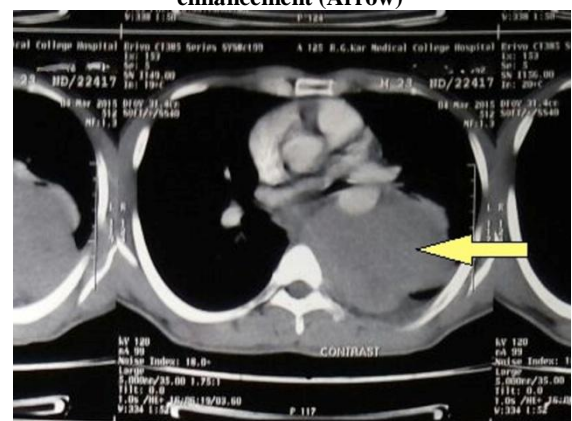

2.2 Case 2

A 23 years old male patient attended the OPD with the complaints of retrosternal chest pain and cough for one month. He was also having shortness of breath and dysphagia for one week.

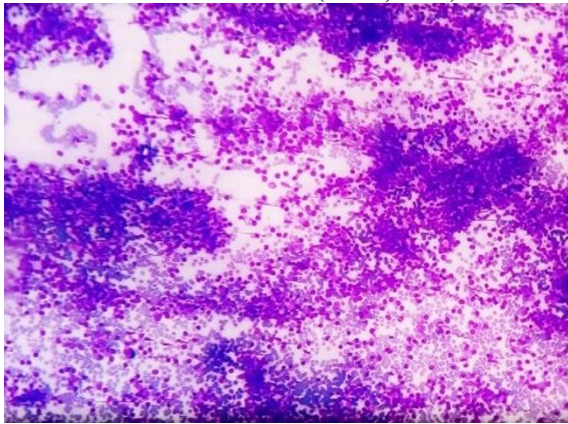
On CT scan a soft tissue density mass was seen at left side of middle mediastinum extending into posterior mediastinum. The mass was compressing trachea and left bronchus. The mass showed homogeneous contrast enhancement. No calcification or necrosis was seen [Figure 4].

Figure 4: CT scan (case 2) showing a soft tissue density mass at left side of middle mediastinum extending into posterior mediastinum, having homogeneous contrast enhancement (Arrow)



CT guided FNAC was done from the tumor. Microscopic examination showed highly cellular smear composed of small cells with round, hyperchromatic nuclei and scanty cytoplasm, suggestive of round cell tumor [Figure 5].

Figure 5:CT guided FNAC (case 2) showing highly cellular smear composed of small cells with round, hyperchromatic nuclei and scanty cytoplasm, suggestive of round cell tumor (MGG, 400X)

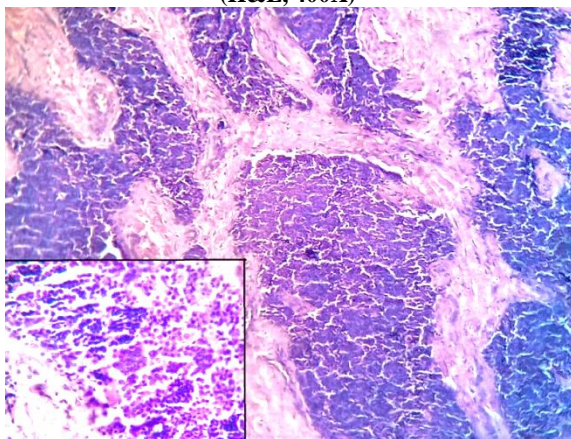


Thoracotomy was performed followed by excision of the tumor, and the specimen was sent for histopathological examination. On gross examination, multiple fragmented greyish brown tissue pieces seen, altogether measuring 11x10x3 cm. [Figure 2B]. Multiple tissue sections were embedded from different parts, and stained with Haematoxylin and Eosin stain.

Microscopic examinations revealed presence of a tumor tissue composed of sheets and nests of small round cells with hyperchromatic nuclei and scanty cytoplasm. Histopathological diagnosis of Ewing’s sarcoma was given [Figure 6].

Patient was referred to the department of oncology and on follow up now.

Figure 6: Photomicrograph (case 2) showing tumor tissue composed of sheets and nests of small round cells, (H&E, 100X). Inset: Round cells having hyperchromatic nuclei and scanty cytoplasm, (H&E, 400X)



3. Discussion

The mediastinum is host to a vast array of both primary and metastatic neoplasms, the differential diagnosis of which are diverse and depends upon the exact site of mediastinal compartment involved, clinical history, presentation, and age of the patient. The anterior compartment is

the most common area for thymoma, lymphoma, and germ cell tumors. In the middle compartment, foregut cysts, lymphoma, and metastatic tumors to lymph nodes constitute the majority of lesions. Most posterior compartment lesions are tumors of neurogenic origin, although other mesenchymal and lymphatic tumors may also arise in this location [4].

Synovial sarcoma is a rare mesenchymal neoplasm that primarily affects the deep soft tissues of the extremities and predominates in adolescents and young adults between 15 and 40 years of age [1]. Although synovial sarcoma has been reported to metastasize to the mediastinum, its occurrence as a primary neoplasm in this location is rare and has only recently been recognized [2]. Because of its rarity in this location, this tumor may be mistaken for other neoplasms that are more common in this location, in particular, malignant mesothelioma.

Synovial sarcoma is composed of two types of cells that form a characteristic biphasic pattern: epithelial cells, resembling those of carcinoma, and fibrosarcoma-like spindle cells. Depending on the relative prominence of these two elements, synovial sarcoma can be classified into four subtypes: biphasic type, monophasic fibrous type, monophasic epithelial type, and poorly differentiated (round cell) type [1,5]. Biphasic synovial sarcoma has a relatively limited differential diagnosis when it occurs in the extremities. However, the differential diagnosis is more extensive when this tumor arises in atypical locations such as the mediastinum.

The Ewing sarcoma family of tumors (ESFT), characterized histologically by primitive small round cells of neuroectodermal origin, includes classic osseous Ewing’s sarcoma, PNET, Askin tumor (Ewing sarcoma of the chest wall) and extraosseous (soft-tissue) Ewing sarcoma [6]. Extraskelatal Ewing sarcoma represents a small subset of the ESFT, though the exact incidence has not yet been ascertained [7]. While more frequent sites of ESFT include the retroperitoneum, paravertebral space, and chest wall, specific organs of involvement described in the literature also include the kidneys, pancreas, colon, uterus, and ovaries [8]. The prognosis of treated patients with localized extraosseous ESFT was similar to that reported for all ESFT patients treated [9]. The mediastinum represents a rare organ of primary involvement.

Ewing’s sarcoma is a small round cell tumor and it is difficult to distinguish histologically from other small round cell tumors like rhabdomyosarcoma, desmoplastic small round cell tumor, poorly differentiated synovial sarcoma, mesenchymal chondrosarcoma, neuroblastoma, lymphoma, and small cell osteosarcoma. Cytologic appearance of ES is distinctive. Smears are highly

cellular and composed of both single cells and groups of loosely cohesive cells with a high nuclear/cytoplasmic ratio, hyperchromatic nuclei with fine chromatin and one or two nucleoli. The cells have clear or eosinophilic cytoplasm, and indistinct cytoplasmic membranes. Holmer Wright rosettes may be seen in differentiated one. The distinction of different small cell tumors is difficult in extraskelatal cases and diagnosis can be clinched by immunohistochemical studies. In the background of classical histopathological findings staining for CD99 will be helpful [10]. Ancillary techniques like cytogenetics, RT-PCR, and FISH are also helpful. Detection of t (11; 22)(q24, q12) chromosome is highly specific and is found in more than 90% of cases.

In conclusion, it can be said that mediastinum could be rarest of the rare locations for primary sarcomas – our search for literature also revealed very few cases across the globe which imparts further credence to the true rarity of the neoplasm. Early management by the oncologist may be hindered further owing to diverse differential diagnosis unless surgical pathologists undertake a cautious pragmatic approach.

References

- [1] Weiss SW, Goldblum JR, Folpe AL. Malignant soft tissue tumors of uncertain type. In: Enzinger and Weiss's soft tissue tumors. 6th ed. St. Louis, MO: Mosby; 2013. p. 1028–110.
- [2] Trassard M, Le Doussal V, Hacène K, Terrier P, Ranchère D, Guillou L, et al. Prognostic factors in localized primary synovial sarcoma: a multicenter study of 128 adult patients. *Journal of Clinical Oncology* 2001; 19(2): 525-34.
- [3] Burchill SA. Ewing's sarcoma: diagnostic, prognostic, and therapeutic implications of molecular abnormalities. *Journal of clinical pathology* 2003; 56(2): 96-102.
- [4] Juanpere S, Cañete N, Ortuño P, Martínez S, Sanchez G, Bernado L. A diagnostic approach to the mediastinal masses. *Insights into imaging* 2013; 4(1): 29-52.
- [5] Fletcher CDM, Bridge JA, Hogendorn P, Mertens F. WHO classification of tumours of soft tissue and bone. 4th ed. Lyon: IARC; 2013. p. 1847-49.
- [6] Takahashi D, Nagayama J, Nagatoshi Y, Inagaki J, Nishiyama K, Yokoyama R, et al. Primary Ewing's sarcoma family tumors of the lung a case report and review of the literature. *Japanese Journal of Clinical Oncology* 2007; 37(11):874-7.
- [7] Van den Berg H, Heinen RC, Van der Pal HJ, Merks JH. Extra-osseous Ewing sarcoma. *Pediatric Hematology and Oncology* 2009; 26(4):175-85.
- [8] Suarez Antelo J, Rodriguez Garcia C, Montero Martinez C, Vereá Hernando H. Pulmonary Ewing sarcoma/primitive neuroectodermal tumor: a case report and a review of the literature. *Arch Bronconeumol* 2010; 46(1):44-6.
- [9] Shannon Orr W, Denbo JW, Billups CA, Wu J, Navid F, Rao BN, et al. Analysis of prognostic factors in extraosseous Ewing sarcoma family of tumors: Review of St. Jude Children's Research Hospital experience. *Annals of Surgical Oncology* 2012; 19(12):3816-22.
- [10] Wick MR. Immunohistochemical approaches to the diagnosis of undifferentiated malignant tumors. *Annals of diagnostic pathology* 2008; 12(1): 72-84.