

## Lingual Schwannoma – A common tumor in uncommon location

Pritha Ghose\*, Manisha Mahata, Jayati Datta, Sanghamitra Mukherjee and Tushar Kanti Das

Department of Pathology, R G Kar Medical College, Kolkata, West Bengal, India

### \*Correspondence Info:

Dr. Pritha Ghose  
R G Kar Medical College,  
Department of Pathology,  
Kolkata-700004, West Bengal, India  
E-mail: [prithaaghose@gmail.com](mailto:prithaaghose@gmail.com)

### Abstract

Schwannoma (neurilemmoma) is a solitary, benign, truly encapsulated tumor originating from proliferating Schwann cells of nerve sheath. Though the overall incidence of Schwannoma is 25-45% in head & neck region, only 1% is seen in oral cavity. Tongue is most common in oral cavity. We report a rare case of lingual schwannoma in a 23 years old male patient who presented with painless, small, slow-growing mass over right lateral border of the tongue of three months duration. A clinical diagnosis of traumatic fibroma was made. The patient underwent complete surgical excision. Histopathological examination confirmed the diagnosis of schwannoma.

**Keywords:** schwannoma, neurilemmoma, tongue, lingual.

### 1. Introduction

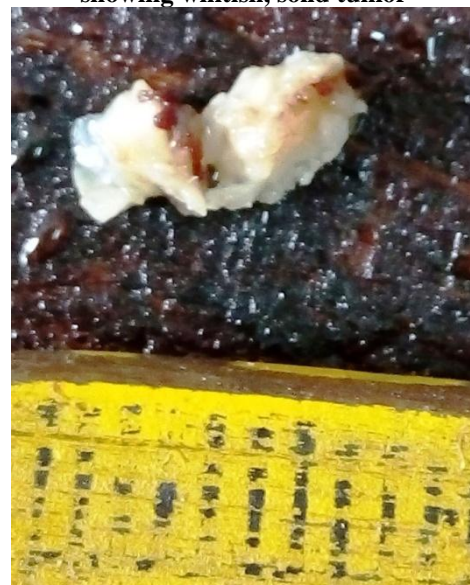Schwannoma (neurilemmoma) is a solitary, benign, encapsulated, slow growing tumor originating from Schwann cells of peripheral sensory or motor nerve [1]. Though the overall incidence of Schwannoma is 25-45% in head & neck region, only 1% is seen in oral cavity, among which tongue is the most common site. Because of its low incidence and absence of definite signs and symptoms, it is often not included in differential diagnosis of tongue swelling. Histopathological findings are sufficient for diagnosis [2]. We present a rare case of Schwannoma of the lateral border of tongue in a 23 year old male patient who was clinically diagnosed as traumatic fibroma but later on biopsy revealed schwannoma.

### 2. Case history

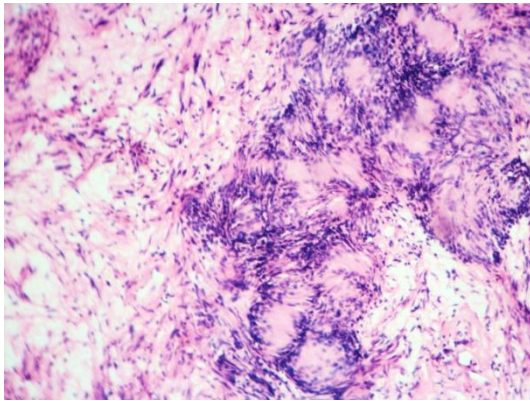
A 23 year old male patient presented with a swelling at right lateral border of tongue for three months without any complain of pain, difficulty in deglutition, chewing and phonation. On local examination, a small, firm, nontender, submucosal swelling was noted. Examination of oral cavity was unremarkable. Due to frequent history of tongue bite lesion was provisionally diagnosed as traumatic fibroma. The patient underwent transoral resection. Surgery was uneventful and the specimen was sent for histopathological examination. Grossly the

resected specimen is single, greyish-white tissue, measuring 1.2 x 0.8 x 0.5 cm. Cut section is solid, white and homogenous (Figure -1). Microscopy revealed a well encapsulated mass (Figure-2) having cellular area comprising of bland spindle cells (Antoni A) and loose myxoid area (Antoni B) (Figure -3). Verocay body and thick hyalinised blood vessels are also seen. Histopathological diagnosis of Schwannoma was made and confirmed by immunohistochemistry (S100).

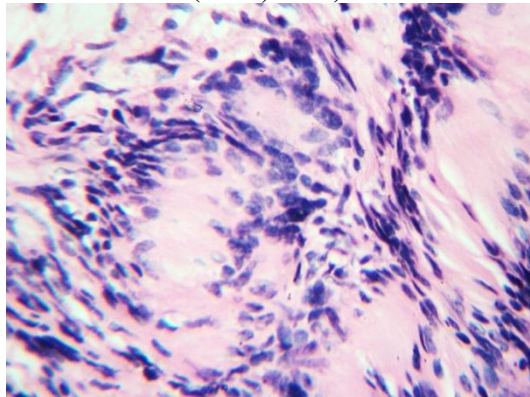
**Figure 1: gross photograph of cut section of tissue showing whitish, solid tumor**



**Figure 2: low power view showing tumor mass composed of hypocellular and hypercellular areas (H&E, 40X)**



**Figure 3: high power view showing Antoni A areas having bland spindle cells forming Verocay body (H&E, 100X)**



### 3. Discussion

Only 1% of head and neck schwannomas occur in oral cavity, of which the most common site is lateral border of tongue (36.3%), followed by base (24.2%), tip (21.2%) and ventral surface (15.1%) [3]. It is usually solitary tumor occurring in 2<sup>nd</sup> to 3<sup>rd</sup> decade of life without any gender predilection [4]. The risk of malignant transformation is very low (8-10%) [5]. Lingual schwannomas are usually asymptomatic when the average size is less than 18.2mm and symptomatic when more than 33mm [6]. Clinically, it can be confused with neurofibroma, traumatic fibroma, lipoma, leiomyoma [7]. MRI can be used to locate the extension of the tumor which helps in surgical planning. Imaging modality is not needed if the mass is in the tip or lateral border of tongue due to ease of excision [3]. Complete excision is the treatment of choice. Histopathology is almost always confirmatory which can be further corroborated by immunoreactivity for S100 [8]. Recurrence after complete excision is extremely rare [9].

### 4. Conclusion

Though schwannoma is very rare in oral cavity especially in tongue, it should be considered as a differential diagnosis while dealing with tongue mass. Our case is unique due to rarity of its location.

### References

- [1] Bhola N, Jadhav A, Borle R, Khemka G, Bhutekar U, Kumar S. Schwannoma of the Tongue in a Paediatric Patient: A Case Report and 20-Year Review. *Case Rep Dent*. 2014;2014: 780762
- [2] Cohen M, Wang MB. Schwannoma of the tongue: two case reports and review of the literature. *Eur Arch Otorhinolaryngol*. 2009; 266:1823–1829
- [3] Erkul E, Cıncık H, Haholu A, Çekin E, Güngör A. Schwannoma of the tongue: A report of two cases and review. *Gulhane Med J*. 2013; 55:135-40.
- [4] Jayaraman V, Balasubramanian B, Senthivelu R. v Schwannoma of the Tongue – A Rare Clinical Entity. *International Journal of Dental Sciences and Research*. 2013; 1(3): 53-55.
- [5] Lira RB, Gonçalves Filho J, Carvalho G.B., Pinto C.A., Kowalski L.P. Lingual schwannoma: case report and review of the literature. *eActa Otorhinolaryngol Ital*. 2013; 33:137-140.
- [6] Ozdemir O, Kurt C, Coskunol E, Calli I. Schwannomas of the hand and wrist: long-term results and review of the literature. *Journal of Orthopaedic Surgery*. 2005;13(3):267-272.
- [7] Kinra PK, Jayakumar K, Michael MJ. Neurilemmoma of the tongue: A case report. *International Journal of Case Reports and Images*. 2014; 5(3):218–221.
- [8] Kurup S, Thankappan K, Krishnan N, Nair PP. Intraoral schwannoma – a report of two cases. *BMJ Case Rep*. 2012; 2012: 1220115389.
- [9] Zaifullah S, Aboud SK, Yunus MRM, Rose IM, Nasser Z. Schwannoma of the tongue: A case report. *RMJ*. 2012; 37(1): 66-67.