
Unilateral minihemithorax – A range of diagnosis

Kapil Iyer*, Swapnil Kulkarni and Mahesh Jansari

Department of Pulmonary Medicine, ESIS hospital, LBS Road, Mulund (W), Mumbai –400080 Maharashtra, India

***Correspondence Info:**

Dr. Kapil Iyer,
501, Spring Leaf,
Military Road, Andheri East,
Mumbai – 400059, Maharashtra, India
E-mail: iyerkapil@gmail.com

Abstract

Unilateral mini hemithorax of the lung is an entity which is seldom encountered in clinical practice. It requires an exhaustive history taking as well as an intensive workup for the possible causes. Very often a chest x - ray is the first diagnostic tool to raise a suspicion, but further diagnostic workup reveals the inadequacy of a chest X ray. We present 3 cases of unilateral mini hemithorax and their respective diagnostic workup and diagnosis.

Keywords: Mini hemithorax, ventilation perfusion scan, Fibreoptic bronchoscopy, vascular hypoplasia.

1. Introduction

Unilateral mini hemithorax is an entity in which one of the hemithorax is substantially smaller than the other. It may either be an opaque mini hemithorax or lucent mini hemithorax. It is a seldom encountered diagnostic challenge. Such cases usually require a high degree of clinical suspicion and a systematic approach towards chest X ray reading and its subsequent interpretation. A simple chest x ray PA view showing a distinct discrepancy in the sizes of the hemithoraces, opens the gateway to a wide array of diagnostic possibilities. This entity requires an exhaustive history taking as well as an intensive diagnostic workup. We present 3 cases of unilateral mini hemithorax and their respective diagnostic workups and diagnosis.

On examination, she was conscious and well oriented in time place and person. Her vitals were stable. Auscultation revealed decreased breath sounds in the left hemithorax. Systemic examination was normal.

Her chest x ray PA view, showed left hyperlucent mini hemithorax with right upper zone fibrocalcific opacities. A Computed Tomography confirmed a left sided hyperlucent mini hemithorax, with areas of post tuberculous fibrosis in the right upper lobe. She was further subjected to a ventilation perfusion scan, which revealed absent ventilation and perfusion in the left lung. In fact the left lung contributed to only 8.6% of the total ventilation, whereas the right lung contributed the remaining 91.4%. She was thus diagnosed as a case of Mcleod or Swyer James syndrome.

2. Case Reports

2.1 Case No 1

38 year old woman, a known case of retroviral disease with a CD4 count of 218, presented with recurrent episodes of cough with expectoration and progressive breathlessness. She gave a past history of pulmonary tuberculosis 10 years ago, for which she had received a 7 month course of anti tuberculous medications. She also gave a history of childhood pneumonia at the age of 5 years, which was managed with antibiotics.

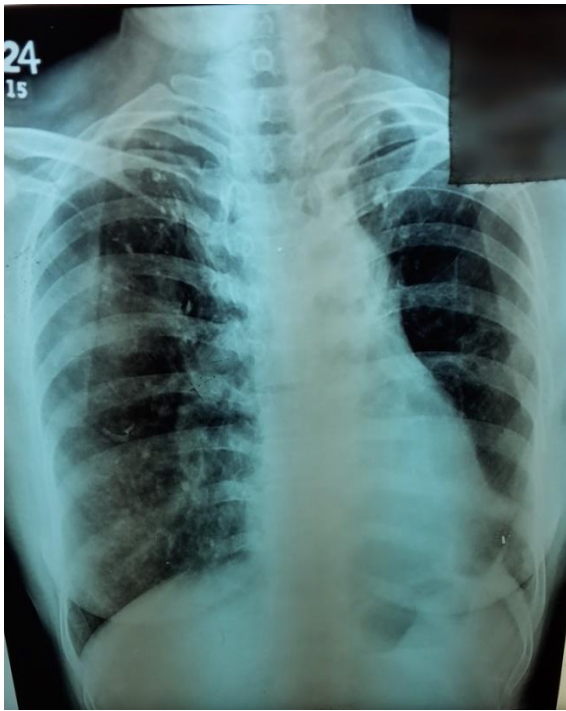


Figure 1: chest x ray showing left sided hyperlucent mini hemithorax with right upper zone fibrocalcific opacities.

congenital vascular anomaly. The dimension of left main pulmonary artery was just 1 cm, less than 50 percent of normal. Thus the cause of his unilateral mini hemithorax could be attributed to vascular hypoplasia. 2 dimensional echocardiography was normal.

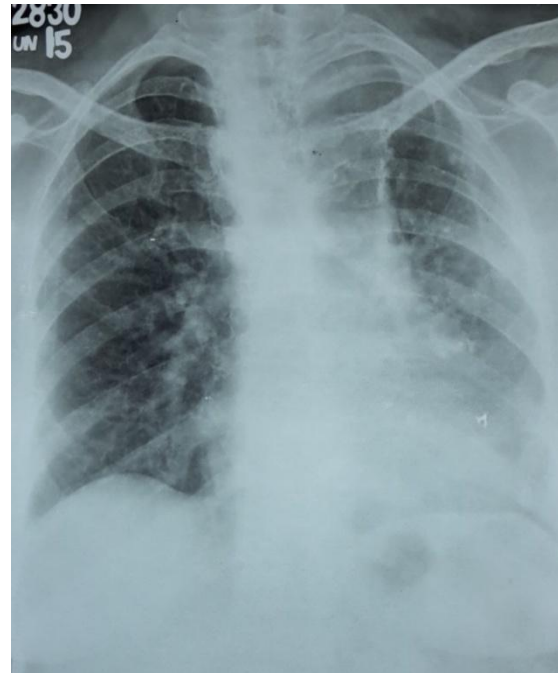


Figure 3: Chest X ray PA view showing left sided mini hemithorax.




Figure 2: Ventilation Perfusion scan showing absence of both in the left lung.

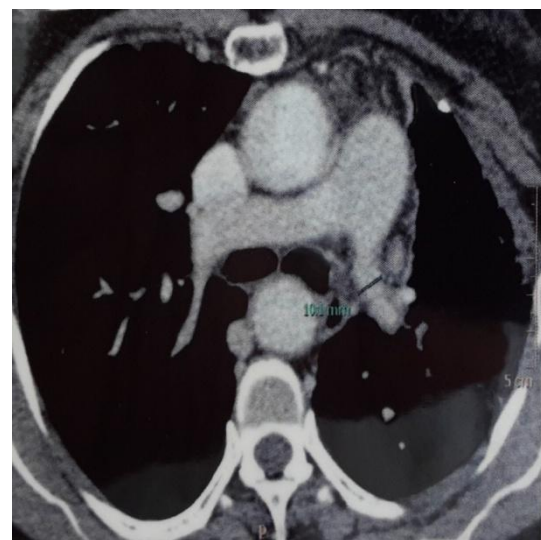

Figure 4: Computed Tomography showing a decrease in the size of left main pulmonary artery.

2.2 Case No 2

47 year old male presented to our outpatient department for pre employment check up. He denied any respiratory complaints, and did not have any past history of pulmonary tuberculosis. Clinical examination was unremarkable. A chest x ray revealed a left sided mini hemithorax. His sputum culture was negative for Acid Fast Bacillus. A Computed tomography of thorax revealed a

2.3 Case No 3

A 40 year old male presented to our outpatient department with complaints of cough with mucopurulent expectoration since 4 days. He gave a past history of pulmonary tuberculosis 10 years back, which was adequately treated with anti tuberculous medications.

On examination his vitals were stable. His chest x ray showed left sided mini hemithorax with ill defined haziness in the left lower zone. His sputum culture for Acid Fast Bacillus was negative. A high resolution computed tomography revealed patchy areas of consolidation in the left lower lobe. He was subjected to the procedure of fiberoptic bronchoscopy, which showed stenosis of the left main bronchus. He responded to a course of broad spectrum antibiotics and postural drainage, and was subsequently discharged.

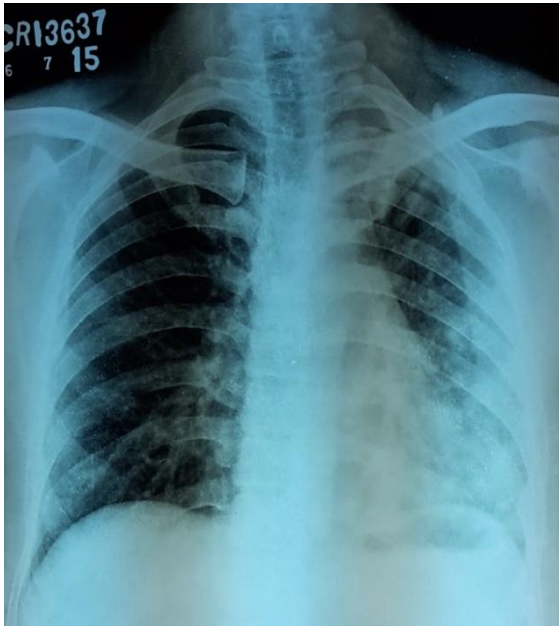


Figure 5 : chest x ray PA view showing left sided mini hemithorax with ill defined opacities in the left lower zone.

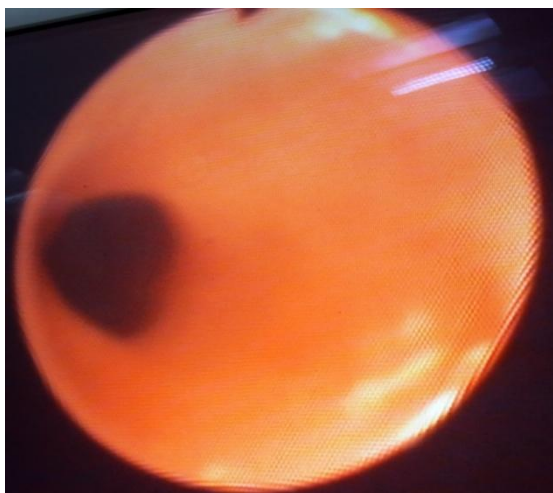


Figure 6: fiberoptic bronchoscopy showing stenosis of the left main bronchus.

3. Discussion

Unilateral mini hemithorax poses a diagnostic challenge. It is very often a subtle finding,

which usually goes unnoticed. An immaculate knowledge and comprehension of chest x ray is required to pick up the discrepancy in the size of the hemithoraces. The subsequent workup depends on the history of the patient and the clinical findings. Very often, Computed Tomography of the thorax and bronchoscopy are required to evaluate the patient.

The first patient was diagnosed as McLeod or Swyer James syndrome. It is a rare lung condition that manifests as unilateral hemithorax/lucency as a result of post-infectious obliterative bronchiolitis. It usually follows a viral respiratory infection such as adenoviruses or mycoplasma pneumonia infection in infancy or childhood.[1-4] Swyer-James syndrome refers to an inability of the lungs to grow after a severe obstructive bronchiolitis. On CT scan, the affected lung shows small size and decreased vascularity, hyperexpansion and hyperlucency, and, rarely, bronchiectasis. Small regions of hyperlucency representing air trapping are reported in some patients. Adenovirus infection is considered the most usual epidemiology. On ventilation-perfusion lung scanning, diminished activity of the affected lung is seen with perfusion scanning, and decreased gas exchange is seen during the ventilatory phase. The lung perfusion deficit seen in patients with Swyer-James syndrome occurs because the peripheral branches of the pulmonary vessels have not developed normally, and vasculature is arrested at the stage at which the causative infection occurred. These patients usually respond to bronchodilators, as was the case seen in our patient.

The second patient was diagnosed as a case of left pulmonary artery hypoplasia. Absence of the pulmonary artery is caused by involution of the proximal embryologic sixth aortic arch and persistence of the connection of the intrapulmonary pulmonary artery to the distal sixth aortic arch. If the ductus arteriosus closes after birth, the ipsilateral intrapulmonary pulmonary artery loses its blood supply, and diminishes in size. Collaterals to the affected lung may arise from bronchial arteries, but have also been reported to arise from the intercostal, subclavian, abdominal aorta branches, and even the coronary arteries. Patients with isolated hypoplasia of the pulmonary artery are usually asymptomatic. Non-specific clinical signs and symptoms at presentation (median age 14-years) might include recurrent respiratory tract infections, dyspnea, and hemoptysis. Other patients may present with pulmonary artery hypertension, pulmonary hemorrhage, or heart failure. Hence these patients need to be regularly evaluated with 2 dimensional echocardiography.[5,6]

The third patient was diagnosed as a case of stenosis of left main bronchus. Bronchial stenosis is

very important pathological diagnosis which should be recognised at the earliest. It can either be intrabronchial, endobronchial or extrabronchial. A tuberculous etiology should always be considered in a country like India, which has a high prevalence of tuberculosis.[7] Any obstruction of the respiratory tract leads to changes in the lung physiology. As the degree of obstruction increases, it leads to the development of a check valve mechanism, which allows the inflow of air but prevents its outflow. The broncho pulmonary segment distal to the obstruction may either become hyperinflated or may harbour accumulated tracheobronchial secretions, leading to repeated infections. Thus such patients tend to present clinically with repeated bouts of lower respiratory infections.

4. Conclusion

Unilateral mini hemithorax is a radiological diagnosis having a wide variety of clinical diagnosis. Its etiology may include disorders of the airways, pulmonary vasculature as well as the tracheobronchial tree. It requires a high degree of suspicion and an exhaustive diagnostic workup.

References

- [1] Moore AD, Godwin JD, Dietrich PA et-al. Swyer-James syndrome: CT findings in eight patients. *AJR Am J Roentgenol.* 1992; 158 (6): 1211-5.
- [2] Shi HS, Yang F, Han P et-al. Findings of chest radiograph and spiral computed tomography in Swyer-James syndrome. *Chin. Med. Sci. J.* 2006; 21 (1): 53-6.
- [3] Marti-bonmati L, Ruiz perales F, Catala F et-al. CT findings in Swyer-James syndrome. *Radiology.* 1989; 172 (2): 477-80.
- [4] Lucaya J, Gartner S, García-peña P et-al. Spectrum of manifestations of Swyer-James-MacLeod syndrome. *J Comput Assist Tomogr.* 22 (4): 592-7.
- [5] Bouros D, Pare D, Panagou P, et al. The Varied Manifestation of Pulmonary Artery Agenesis in Adulthood. *Chest* 1995; 108(3): 670-676.
- [6] Shostak E, Sarwar A. A 50-year-old Woman with Dyspnea, Lower Extremity Edema, and Volume Loss of the Right Hemithorax. *Chest* 2009; 136(2): 628-632.
- [7] Cohen A G, Wessler H. Clinical recognition of Tuberculosis of the major bronchi. *Arch. Int. Med.* 63:1132, 1939.