

**International Journal of Biomedical Research**

ISSN: 0976-9633 (Online); 2455-0566 (Print)

Journal DOI: [10.7439/ijbr](https://doi.org/10.7439/ijbr)

CODEN: IJBRFA

**Review Article**

---

## **Insights of TMJ through advanced imaging**

---

**Roma Goswami, Pooja Arora, Nishant Gaba\* and Krati Jain**

*Department Of Prosthodontics, Subharti Dental College, Meerut, Uttar Pradesh, India*

**\*Correspondence Info:**

Dr. Nishant Gaba  
Room No. 27,  
Udham Singh Boys Hostel  
Subharti Dental College,  
Swami Vivekanand Subharti University, Subharti Puram, NH-58,  
Delhi Haridwar by Pass Road, Meerut- 250005  
E-mail: [nishant\\_gaba08@yahoo.com](mailto:nishant_gaba08@yahoo.com)

**Abstract**

Temporomandibular disorders (TMD) are clinical manifestations of disorders causing pain and dysfunction in the Temporomandibular Joints (TMJs) and masticatory muscles. TMJ abnormalities cannot be reliably assessed by a clinical examination. Radiographic examination forms an integral component for the routine assessment in patients with temporomandibular joint disorders. Latest imaging modality is making life easy for those clinicians who must evaluate the hard and the soft tissue of the temporomandibular joint complex in patients with TMD's. Conventional radiographic TMJ projections like transpharyngeal, transcranial, panoramic radiograph, conventional tomographic sections of TMJ may be adequate in number of clinical situations but there are bony alterations that occur in these disorders like erosions, osteophytes, pneumatization of articular eminence that are difficult to be detected in the conventional radiographs due to overlapping of anatomical structures. So the advanced imaging techniques such as MRI, Ultrasonography, CBCT are required for the understanding of diseases of Temporomandibular Joint. This paper aims to cover all the latest imaging modalities that can be helpful in the diagnosis of Temporomandibular Joint Disorders.

**Keywords:** TMJ disorders, imaging in TMJ, CBCT, MRI, Radiographic investigations of TMJ

**1. Introduction**

Temporomandibular joint disorders (TMD) are clinical manifestations of disorders causing pain and dysfunction in the temporomandibular joints (TMJs) and masticatory muscles. Complex etiologic factors like trauma, emotional stress, orthopaedic instability, muscular hyperactivity, inflammatory and degenerative diseases, which compromise the equilibrium of the temporomandibular joint (TMJ), have been implicated in the development of temporomandibular joint disorders (TMD). Radiological investigations are of paramount importance in the diagnostic assessment of a patient with TMD.

Conventional radiographic TMJ projections like transpharyngeal, transcranial, panoramic radiograph, conventional tomographic sections of TMJ are sufficient in making diagnosis in most of the

cases but in some conditions for eg: erosion or pneumatization of articular eminence, advanced imaging techniques are required as there is overlapping of anatomical structures in conventional radiographs which may make difficult to diagnose such situations.[1] The remarkable progress and increasing sophistication in the imaging of the Temporomandibular Joint (TMJ) seems to have added to the confusion among practitioners as to when and what imaging should be used. Further all imaging techniques are not equally effective for many conditions in which the TMJ is involved.[2] This article aims to cover all the aspects of various imaging techniques available for Temporomandibular joint disorders.

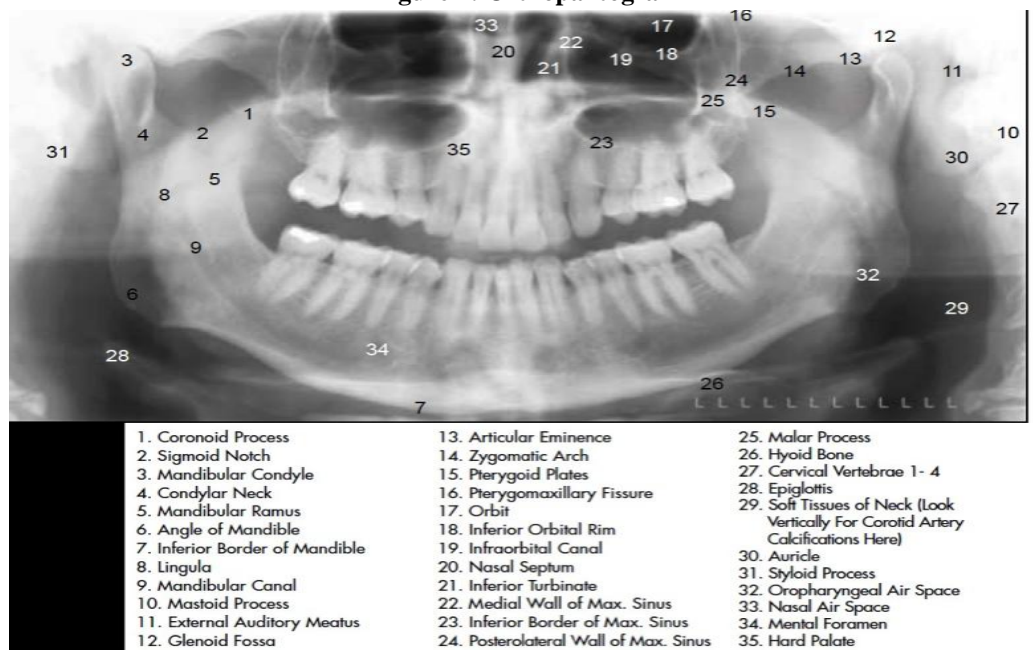
## 2. Radiographic techniques

### 2.1 Panoramic radiography

Panoramic radiograph allows good visualization of all dental elements and their anatomical structures in the maxillo-mandibular complex. In addition, the patient is exposed to a low dose of radiation. A panoramic radiograph is considered a "screening" projection and is often used in combination with other hard tissue imaging techniques to image the TMJs. Panoramic radiographs taken with high technical standards can provide good radiographic finding in diagnosing pathologies in the jaws.

Panoramic radiography is a useful and practical complement during the clinical examination of teeth to diagnose caries, pulp origin diseases, and diseases of the facial bones. In addition, panoramic radiograph allows a dentist to examine all the teeth at once, including those still below the gum line; therefore, caries, tooth fractures, infections, or other diseases of the bones that support the teeth can be viewed and diagnosed.[3] Moreover, situations of bone resorption as well as radicular cysts, tumors, inflammation, post-accident fractures, temporomandibular joint disorders, and sinusitis can be identified.

**Figure 1: Orthopantogram**



### 2.2 Arthrography

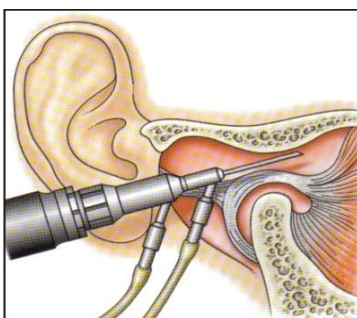
Before the use of computer tomography and magnetic resonance imaging, arthrography was the only reliable method for diagnosing the problems of joint disc complex. The arthrographic technique was already described in the 1940s, but it was not introduced into clinical practice until the end of the 1970s. There are two methods of implementation: contrast substance is injected into the upper joint space (above the joint disc), less often into the lower,

or both spaces. In double-contrast arthrography a small amount of air is introduced after application of the contrast substance.[4]

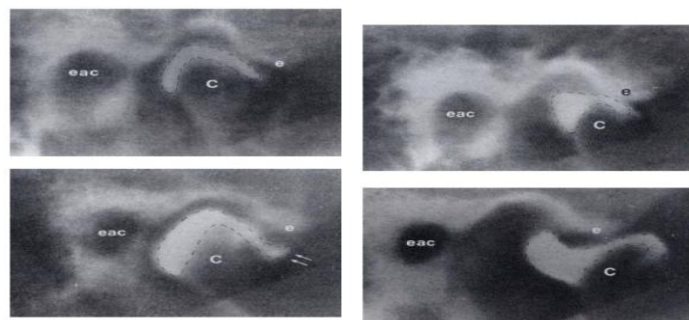
#### Disadvantages of the technique:

- (1) Technique sensitive
- (2) Painful for the patient; and
- (3) Information gained from the examination was, of only limited value for treatment planning and evaluation of prognosis.

**Figure 2.a): Arthrography procedure**



**Figure 2.b): TMJ seen in Arthrography**



### 2.3 Computer Tomography

Computed tomography (CT) is a more sophisticated digital tomographic technique where the patient is exposed to a fan-shaped x-ray beam directed to a series of detectors. The detectors and/or the x-ray beam move around the patient, usually in the axial plane, to acquire numerous projections at various angles. The transmission data from these projections is used to reconstruct the image, which is viewed on a computer monitor. Further manipulation can be done to reformat images in various orientations for viewing. The use of CT in diagnosing TMJ disorders dates back to the late 1980s. It became popular for the diagnosis of disc displacement of the TMJ. It was thought of as a replacement for the

technically more difficult and invasive arthrography[13]; CT imaging provides exquisite detail for bony abnormalities, such as ankylosis, fractures, osseous tumors and arthrosis. With conventional tomography, several exposures are made with the area of interest moving through the plane of focus. A submentovertex (basal) view may be used to determine the angulations of the condylar headlong axes in order to "correct" the angulation of the tomographic images. This produces an undistorted view of joint morphology and allows accurate assessment of condylar position. Arthrography is combined with computer tomography, which enhances the accuracy of the diagnosis of internal TMJ disorders.

**Figure 3: Computed Tomography Image A**

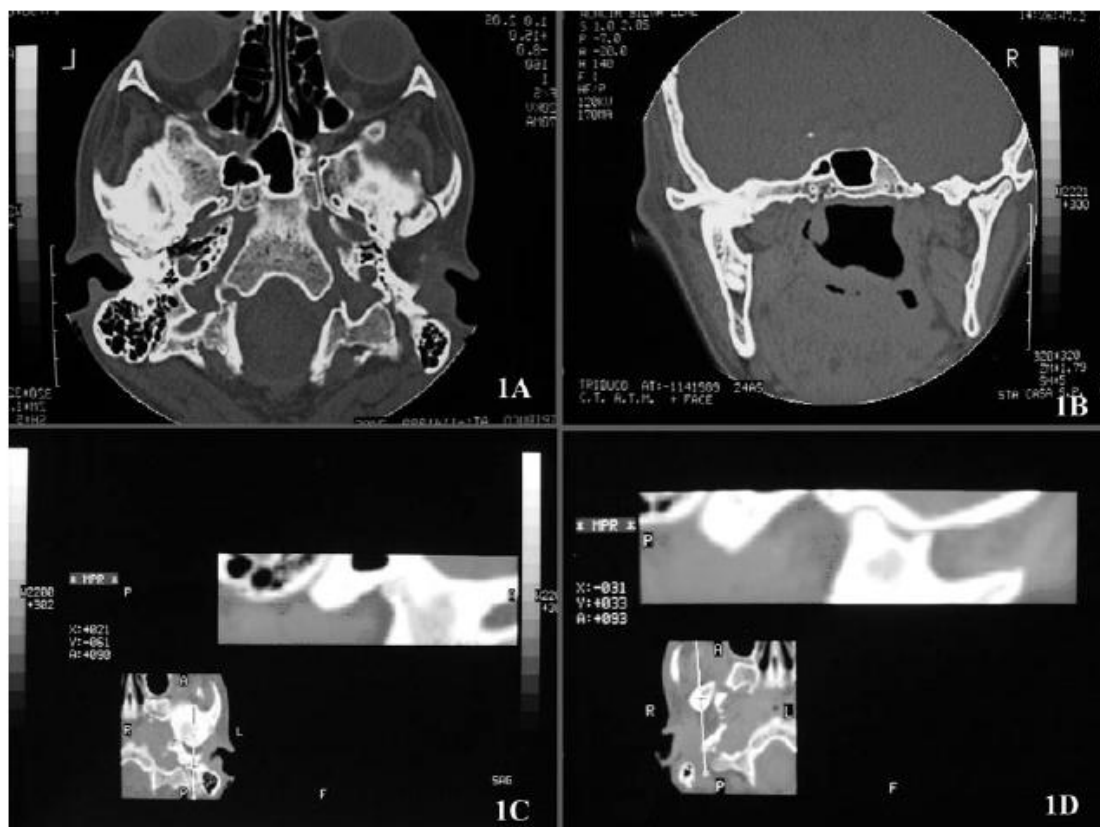


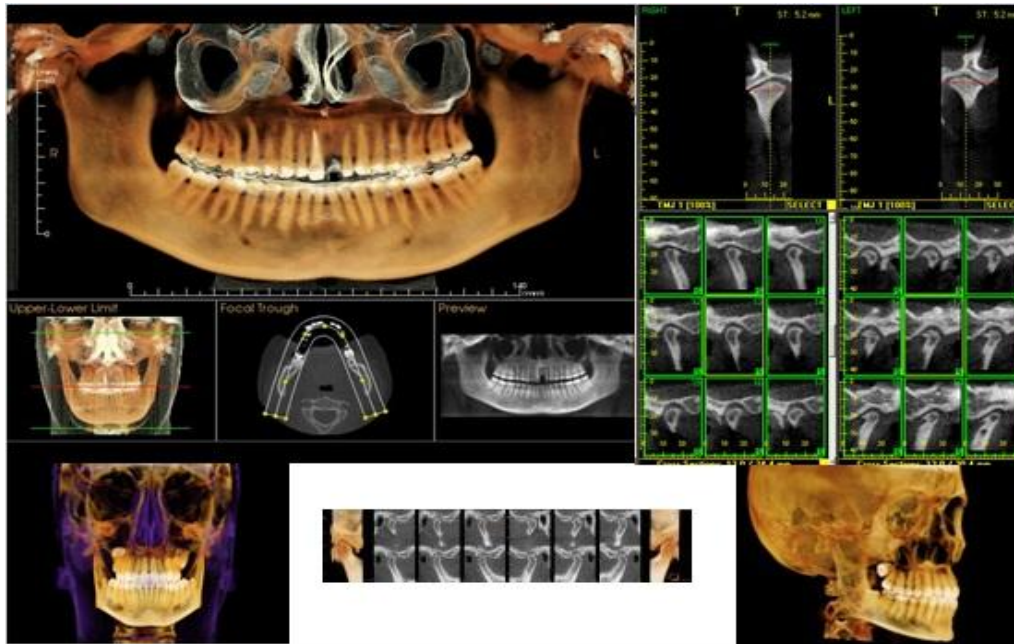Fig. 1. Case 1. A: Axial Slice; B: Coronal Slice; C: Sagittal reformatted image, left

### 2.4 CBCT

The Cone-Beam Computed Tomography (CBCT) scanners were introduced in the late 1990s. Shortly after, the US Food and Drug Administration (FDA) approved the first CBCT unit in 2001. Since then, there has been an enormous interest in this new technology for its clinical and research applications. The CBCT is an imaging acquisition technique that utilizes a volumetric scanning machine. This technology uses a cone-shaped X-ray beam directed towards a flat two-dimensional (2D) detector. When both rotate around the patient's head, a series of 2D

images are generated. The software then reconstructs the images into three-dimensional (3D) data set using a specialized algorithm.<sup>5</sup> The currently available CBCT units utilize radiation doses ranging from 87 to 206  $\mu$ Sv for a full craniofacial scan. These radiation doses are slightly higher than the conventional radiographic techniques such as the lateral cephalograms or the panoramic radiographs and markedly lower than that of multi-slice CT. The scan time varies between 10 to 75 seconds, depending on the FOV and the CBCT unit used.

Figure 4: CBCT Image

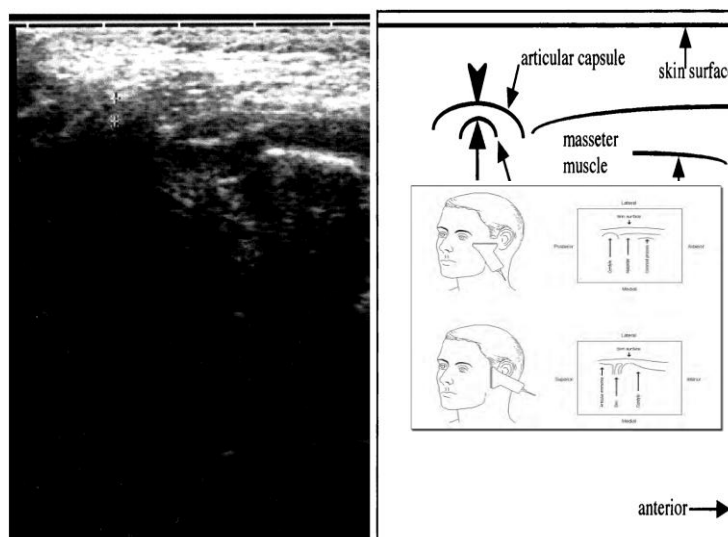


## 2.5 Ultrasonography

TMJ ultrasonography is a non-invasive, readily available and cheap examination for joint and soft tissues. The principle of ultrasonography is based on the fact that ultrasonic sound waves emitted by a device (transducer), travel through the tissue against which they are aimed, and are partly reflected on transiting through dissimilar anatomical structures. The reflected sound waves are then read by the same emitting device, and translated into images. The TMJ region consists of diverse structures that reflect sound waves differently. Bone tissue, represented by the head of the condyle and the articular eminence, is generally hypoechoic (low reflection of sound waves) and appears black in ultrasonography images, however the margin of the

bone is hyperechoic (high reflection of sound waves) and appears white in ultrasonography images. Connective tissue, represented by the joint capsule and the retrodiscal tissue, and muscular tissue, represented by the lateral pterygoid and masseter muscles, are isoechoic (intermediate reflection of sound waves) and appear grey in ultrasonography images and appear heterogeneously grey in ultrasonography images. However the surfaces of the joint capsule, as well as the surface of the muscles, highly reflect the sound waves generating a hyperechoic (white) line. Empty space and water, like the superior and inferior joint spaces, are hypoechoic and appear black in ultrasonography images.[6]

Fig.5 TMJ Image seen in Ultrasonography



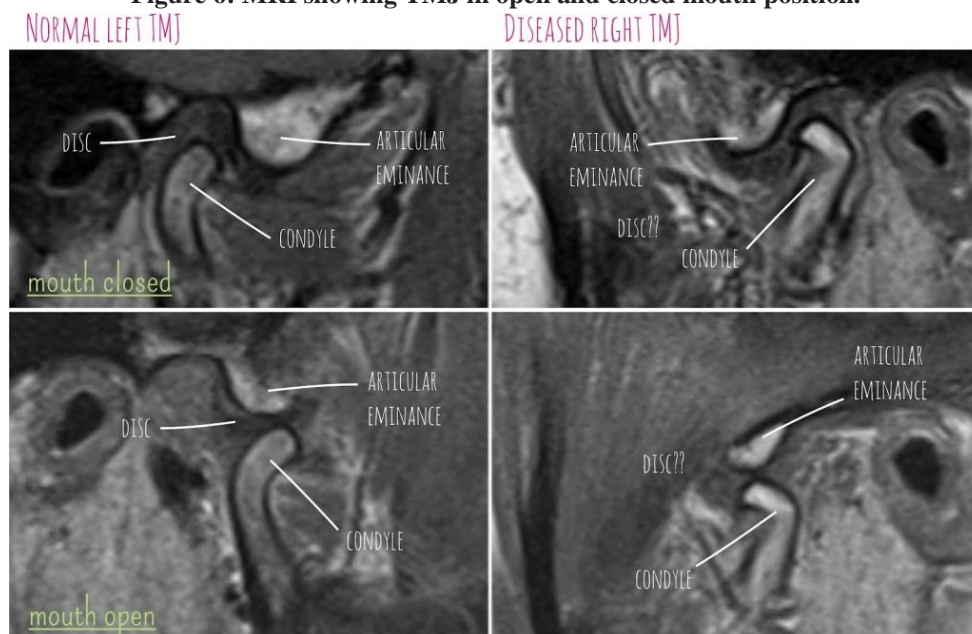
### 2.6 Magnetic Resonance Imaging (MRI):

Magnetic resonance is an imaging method of high resolution efficiency having no undesirable side effects. Magnetic resonance imaging (MRI) has replaced computed tomography (CT) and arthrography as the primary modality in the evaluation of the temporomandibular joint (TMJ). Direct visualization of the disk afforded by MRI is a distinct advantage over arthrography. Despite the superior resolution of CT and limited visualization of cortical bone by MRI, most osseous pathology is accurately depicted.

During the examination the body is placed in a strong magnetic field which causes hydrogen proton dipoles to align parallel to the magnetic field lines. Added radiofrequency pulses of set defined

frequency provoke the resonance of extra and intracellular hydrogen ions. After the radiofrequency pulse is stopped, the so-called relaxing phase sets in. During this phase atomic nuclei irradiate radio waves recorded by the equipment. There are obvious advantages of MR imaging over arthrography, such as being less invasive, less dependent on operator skill, and more accurate for medial and lateral disc displacements. MR imaging also compares favorably with CT for hard-tissue evaluation while providing a more detailed image of the soft tissue and being less invasive, since no radiation is used. The disadvantages of MR imaging include high cost, inability to use with claustrophobic patients, and differences in image quality produced by different scanners and different surface coils.

**Figure 6: MRI showing TMJ in open and closed mouth position.**

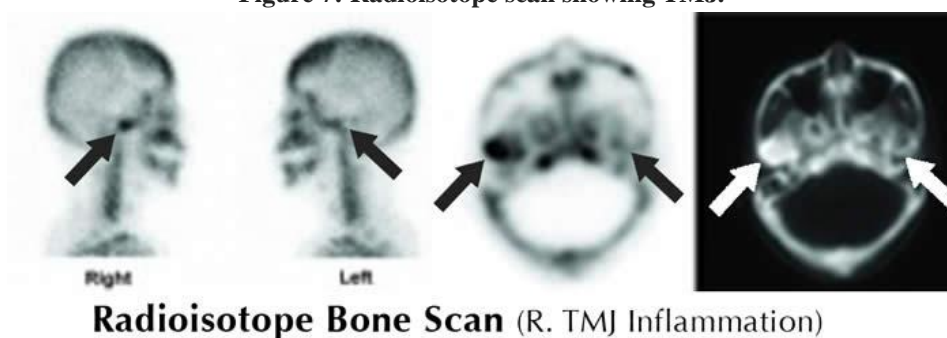


### 3. Radionuclide Examination

Scintigraphy aids to discover early changes in the TMJ skeleton which may also result in the joint disc abnormalities. Radionuclide  $^{99m}\text{Tc}$  is used for the examination. The temporomandibular joint is ideal for what is called SPECT (single photon emission computed tomography), because it is a quite

small joint situated close to the skull base and paranasal sinuses. So SPECT can, unlike the double-dimension featuring, present TMJ separately from the parts of high bone density. The radionuclide examination sensitivity is high, its specificity is however low. Any inflammation, trauma or tumors increase the local isotope concentration.[5]

**Figure 7: Radioisotope scan showing TMJ.**

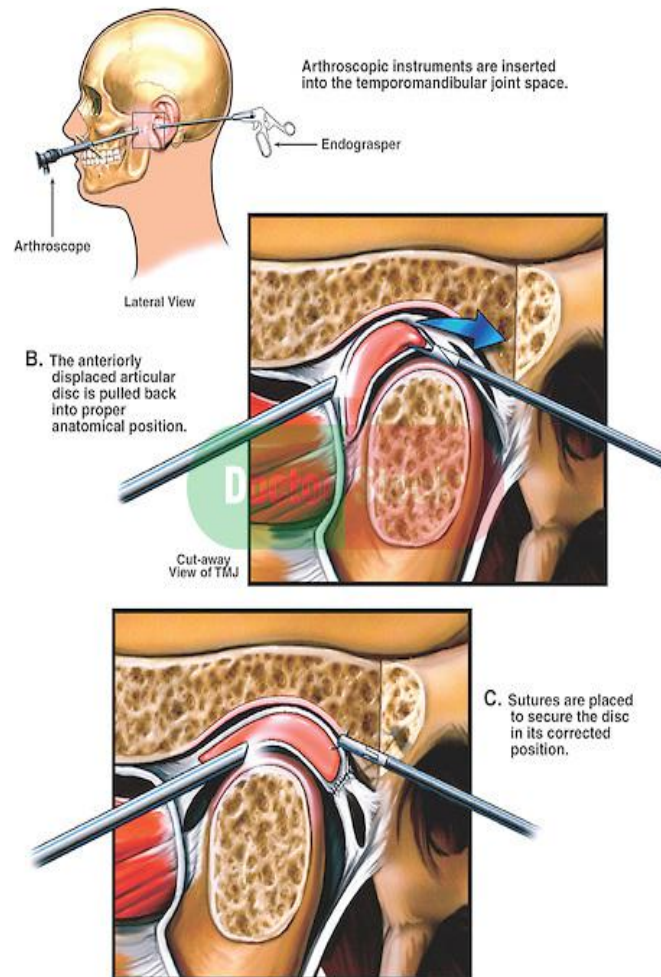


#### 4. Arthroscopy

Arthroscopy is both a therapeutic and miniinvasive endoscopic method for TMJ space examination. It is performed under general anesthesia with percutaneously installed trocars and an optical probe of 1.9–2.4 mm diameter. The intraarticular

picture is transmitted by a light cable onto the screen. However, complications may arise such as haemorrhage, joint cartilage damage, joint disc perforation, face innervation damage, mid ear perforation, intracranial perforations and the risk of infection.

**Figure 8: TMJ Image seen in arthroscopy.**



#### 5. Conclusion

Detailed case history and thorough clinical examination are necessary for determining disease activity and for making the decision whether to go for radiographs or not but usually these tools are insufficient to base exact diagnosis of temporomandibular defects.<sup>7</sup> The assessment of reliability, validity, risk, cost and usefulness of a diagnostic procedure is an essential part of the treatment plan for patients with TMD and therefore a good quality radiographs are required to make a proper diagnosis and to know the extent of damage to the soft and hard structures. Today with all the advances in the existing techniques and the research work for newer techniques, it had been made possible to clearly visualize the hard and soft tissues of

Temporomandibular joint and to modify our treatment plan accordingly.

Ultrasonography, as a completely non-invasive procedure, commonly used in many branches of medicine and applied even in diagnosing functional temporomandibular defects. MRI is capable of demonstrating abnormalities of the disc, its supporting structures, synovium and periarticular structures associated with internal derangements, degenerative and inflammatory arthropathies, and development and traumatic conditions. CBCT provides a definite advantage over other techniques due to its low radiation dose to patient, smaller equipment and ability to provide multiplanar reformation and 3D images.

## References

- [1] Krishnamoorthy Bhuvana, Mamatha NS and Kumar Vinod AR. CBCT in TMJ imaging. *Annals of Maxillofacial Surgery*, 2013; 3(1): 80-83.
- [2] Sinha Vijai P, Pradhan Harsha, Gupta Hemant, Mohammad Shadab, Singh R. K., Mehrotra Divya, Pant M. C. and Pradhan R. Efficacy of plain radiographs, CT Scan, MRI and ultra Sonography in temporomandibular joint Disorders. *National Journal of Maxillofacial Surgery* 2012; 3(1): 2–9.
- [3] Rafel et al: Common positioning errors in panoramic radiography: a review. *Imaging Sci Dent* 2014; 44:1-6.
- [4] Petr Tvrdy et al: Methods of imaging in the diagnosis of temporomandibular joint disorders. *Biomed Pap Med Fac Univ Palacky Olomouc Czech Repub.* 2007, 151(1):133–136.
- [5] Deepak C, Saravanan B, Kishore Kumar S. CBCT a Diagnostic Aid in Dentistry. *Indian Journal of Multidisciplinary Dentistry* 2014; 4 (1): 67-73.
- [6] Melis Marcello, Secci Simona, & Ceneviz Caroline. *American Journal of Dentistry* 2007; 20 (2):73-78. Use of ultrasonography for the diagnosis of temporomandibular joint disorders: A review
- [7] Petersson A. What you can and cannot see in TMJ imaging – an overview. Related to the RDC/TMD diagnostic system. *Journal of Oral Rehabilitation* 2010; 37: 771–778.
- [8] Wiese et al. Association between Temporomandibular Joint Symptoms, Signs, and Clinical Diagnosis Using the RDC/TMD and Radiographic Findings in Temporomandibular Joint Tomograms. *J Orofac Pain* 2008;22:239–251
- [9] Mohl N.D. Reliability and validity OF diagnostic modalities for temporomandibular disorders. *Adv Dent Res* 1993; 7(2):113-119,
- [10] Lobbezoo et al. Topical Review: New Insights into the Pathology and Diagnosis of Disorders of the Temporomandibular Joint. *J Orofac Pain* 2004; 18:181–191.
- [11] Michael J. Pharoah. The Prescription of Diagnostic Images for Temporomandibular Joint Disorders. *J Orofac pain* 1999; 3:251-254.
- [12] Hussain et al. Role of different imaging modalities in assessment of Temporomandibular joint erosions and osteophytes: a systematic Review. *J Orofac pain* 1999; 3:251-254.
- [13] Kaplan Phoebe A. and Helms Clyde A. Current Status of Temporomandibular Joint Imaging for the Diagnosis of Internal Derangements. *AJR* 1989; 152:697-705.
- [14] Westesson P.L. Reliability and validity of imaging diagnosis of temporomandibular joint disorder. *Adv Dent Res* 1993; 7(2): 137-15.