

International Journal of Biomedical Research

ISSN: 0976-9633 (Online); 2455-0566 (Print)

Journal DOI: [10.7439/ijbr](https://doi.org/10.7439/ijbr)

CODEN: IJBRFA

Original Research Article

Gastroenteropancreatic Neuroendocrine Tumours – An Institutional Experience

Tessa Joseph* and Shanthala PR

Yenepoya Medical College, Yenepoya University, Deralakatte, Mangalore, India

***Correspondence Info:**

Dr. Tessa Joseph
Room No.409,
Gardeynia PG Hostel,
Yenepoya Medical College, Lakshmigudde
Deralakatte, Mangalore -575018, Karnataka.
E-mail: tessajoseph.613@gmail.com

Abstract

Objectives: 1) To study the histomorphological spectrum of gastroenteropancreatic neuroendocrine tumours (GEP NETs) and to analyze its clinicopathological features. 2) To classify the GEP-NETs as per WHO 2010 classification system. 3) To analyze the expression of the NET marker Neuron specific enolase (NSE) in the above histomorphological spectrum.

Methods: A retrospective study was done with collected cases of GEP-NET (over 7 year period). Clinical data was collected from medical records. The histopathology slides were retrieved from archives and reviewed. Immunohistochemical (IHC) studies were done with marker NSE.

Results: The study included 11 cases of GEP-NETs. The age of the patients ranged from 13 to 65 years. The most common anatomic location was the appendix and colon with 3 cases each (27.27%). Most of the tumours were grade I (6 cases). None of the tumours were associated with carcinoid syndrome. Six out of eleven cases had metastasis at time of diagnosis (54.54%). IHC studies done with NSE resulted in positivity seen in all 10 cases in which it was done.

Conclusions: Gastroenteropancreatic neuroendocrine tumours are rare and occur over a wide age range. Most of these tumours present late with metastasis at time of diagnosis. The most common location of these tumours was in the appendix and proximal colon. NSE is a good marker for these tumours and is beneficial in confirming the diagnosis.

Keywords: Gastroenteropancreatic, neuroendocrine tumours, immunohistochemistry

1.Introduction

Neuroendocrine tumours (NET) of the gastroenteropancreatic (GEP) system originate from diffuse endocrine system located in the gastrointestinal tract and in the pancreas[1]. These tumours synthesize, store, and secrete various peptides and neuroamines that might produce distinct clinical syndromes like carcinoid syndrome, gastrinomas, and insulinomas etc[2]. Many a times the term carcinoid tumor has been used synonymously for neuroendocrine tumor[3]. The understanding of gastroenteropancreatic NETs originated since Siegfried Oberndorfer in 1907 first commented on tumours of the small intestine and coined the term

karzinoide (carcinoid) meaning cancer-like. The GEP- NETs are rare with reported incidence of 2-5 to 5 cases per 100, 000.[4] Based on various factors, the classification, nomenclatures, grading of these tumours have been changing with time. Thus, there is a need to review these neuroendocrine tumours in the current perspective.

2. Materials and methods

All cases of gastroenteropancreatic neuroendocrine tumours reported over a period of 7 years (June 2007 - June 2014) were reviewed in this study. Clinical details and results of imaging studies

were collected. Routine Haematoxylin and eosin stained slides were evaluated and suitable blocks were selected for immunohistochemistry (IHC) which was performed on 3-Aminopropyl triethoxysilane coated slides. Antigen retrieval was done by heating the sections in citrate buffer at pH 6.0 using pressure cooker. Mouse monoclonal antibody Neuron Specific Enolase (NSE) from NOVOCASTRA company (product code: RTU-NSE-2) was used. Standard streptavidin-biotin peroxidase method of IHC was followed. A positive reaction was taken as crisp golden brown cytoplasmic staining.

3. Results

A total of 11 cases of GEP- NETs were reported during the specified period. The age of the patients ranged from 13 to 65 years. The most common age group affected was 41 to 60 years. The average age at diagnosis was 46.4 years and the male to female ratio was 2.7:1. The most common anatomic location in our study was appendix and colon with 3 cases each (27.27%) followed by 2 cases in pancreas (18.18%) and 1 each in ileum (9.09%), stomach (9.09%) and rectum (9.09%). The details of the cases are given in (Table 1). Most common presenting symptoms were pain abdomen and loss of weight. Blood in stool was observed in cases of tumors of stomach and rectum. All 3 cases of appendix were incidental with 2 cases presenting as acute appendicitis and 1 case was incidental finding in right hemicolectomy specimen of a patient diagnosed as polyposis coli with colonic adenocarcinoma. Neuroendocrine tumor arising within transverse colon presented as intestinal obstruction. The patient with Insulinoma presented with recurrent hypoglycemic episodes. None of the patients showed features of carcinoid syndrome.

In the present study there was no grossly visible tumour in the 3 cases of appendix. The size of other gastrointestinal NETs varied from 2.5x1 cm (ileum) to 13x9x8 cm (caecum). Figure 1 and 2 shows cut surface of neuroendocrine tumor of ileum and stomach respectively. The size of pancreatic NETs ranged from 1.5x1.5x1.4cm to 12x7x3 cm.

Microscopically, on categorization according to 2010 WHO classification for neuroendocrine tumours (Table 2) there were 6 cases of Grade I NET (typical carcinoid like) (Figure 3a & 3b), 2 cases of Grade II NET (atypical carcinoid like) (Figure 4a & 4b) and 3 cases of Grade III neuroendocrine carcinoma – large cell type (Figure 5a & 5b). Clinical evidence of metastasis on imaging studies were reported in 5/11 cases with liver being

the commonest site of metastasis. One case of large cell neuroendocrine tumor had excised lymph nodes showing metastasis.

Immunostaining for NSE was done in 10 cases, all of which showed diffuse cytoplasmic staining. IHC was not done for rectal carcinoid as block was not available.

Figure 1: Cut surface of neuroendocrine tumour of small intestine with mesenteric metastasis



Figure 2: Cut surface of neuroendocrine tumour of stomach

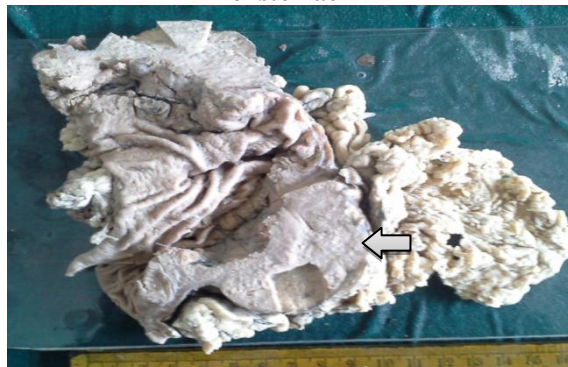


Fig 3a: H&E section of G1 neuroendocrine tumour (100x)-shows organoid pattern

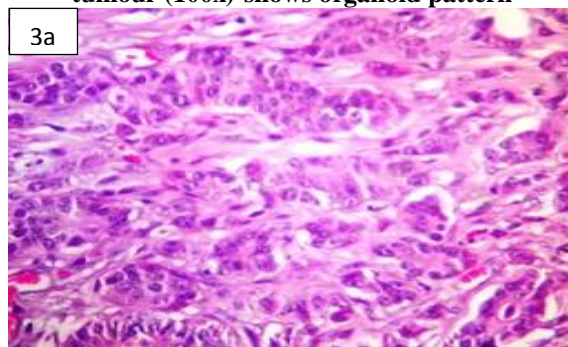


Fig 3b: NSE Section of G1 neuroendocrine tumour (400x)

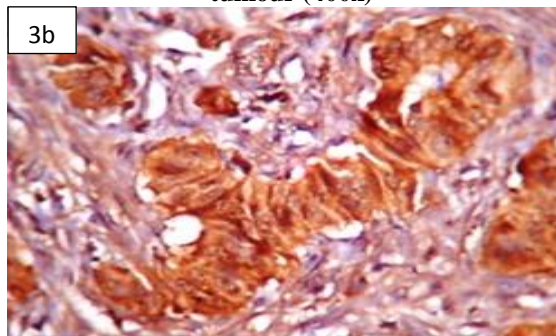


Fig 4a: H&E section of G2 neuroendocrine tumour (100x)- shows organoid pattern & necrosis

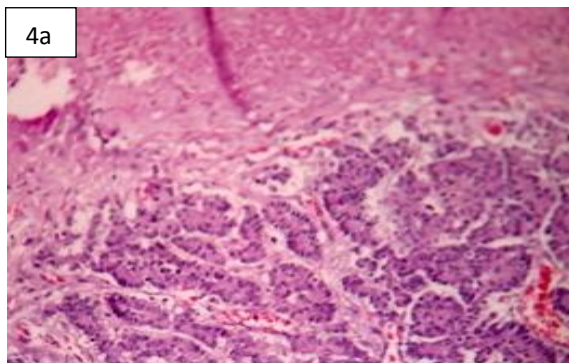


Fig 4b: NSE section of G2 neuroendocrine tumour (100x)

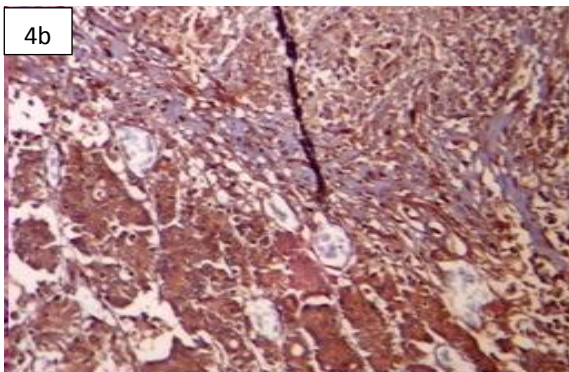


Fig 5a: H&E section of G3 neuroendocrine carcinoma/Large cell neuroendocrine carcinoma(400x)

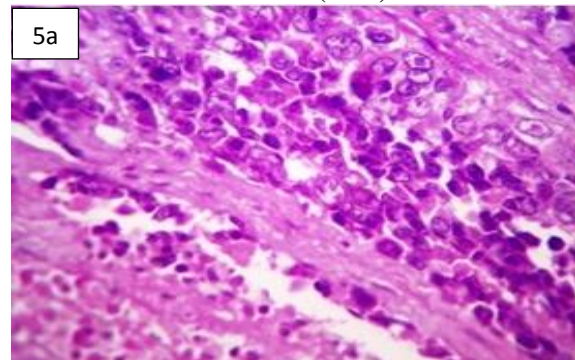


Fig 5b: NSE section of G3 neuroendocrine carcinoma/Large cell neuroendocrine carcinoma (400x)

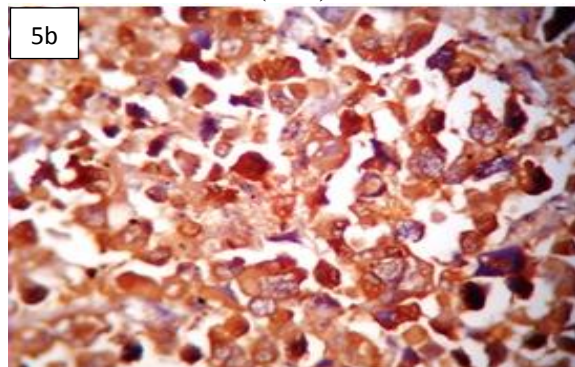


Table 1: Case details of Gastroenteropancreatic Neuroendocrine Tumours

Sl No	Age/ Sex	Site	Clinical Details	Presence of metastasis	Depth of invasion	Type of GEP NETs	NSE positivity
1	49/M	Stomach	Pain in abdomen, weight loss, Malena	Hepatic +	Serosa	Grade II	Diffuse positivity
2	48/M	Ileum	Weight loss, pain abdomen.	Hepatic + Mesentric +	Serosa	Grade I	Diffuse positivity
3	45/M	Appendix	acute appendicitis	-	Submucosa	Grade I	Diffuse positivity
4	65/M	Caecum	Mass & Pain abdomen, Weight loss	Hepatic +		Grade III/ large cell EC	Diffuse positivity
5	52/F	Rectum	Weight loss, pain in abdomen, bloody stool	-	Submucosa	Grade I	Diffuse positivity
6	62/F	Pancreatic mass	Pain abdomen, Weight loss	Ovary +	Serosa	Grade III/ large cell NEC	Diffuse positivity
7	35/M	Ascending colon	Mass & pain abdomen, jaundice	Hepatic +	Serosa	Grade III/ large cell EC	Diffuse positivity
8	13/M	Appendix	acute appendicitis	-	Submucosa	Grade I	Diffuse positivity
9	34/F	Appendix	Incidental finding in colectomy specimen	-	Serosa	Grade I	Diffuse positivity
10	45/M	Pancreas	Giddiness and hypoglycaemia	-	Intraparenchymal	Grade I	Diffuse positivity
11	62/M	Transverse colon	Intestinal obstruction	Lymph Node +	Serosa	Grade II	Diffuse positivity

5. Discussion

The population prevalence of neuroendocrine tumours overall is found to be 1 to 2 cases per 100,000. The gastrointestinal tract is considered to be the commonest site. Though many of these tumours have an indolent course, the changing systems of classification and nomenclatures

over the time have led to the understanding that these tumours vary widely in their biologic behavior. Indian studies regarding GEP-NET have been found to be very few in literature[5].

According to Maggard *et al*[6] the average age at diagnosis for NETs is 60.9 years and 54.2% of the cases occurred in females. Modlin *et al*[7]

conducted a study in 2003 according to which the average age at diagnosis was 61.4 years for patients with carcinoid tumour. In this study age of patients ranged from 13 to 65 years and the mean age (46.4 years) was comparatively lower. In the present study the male to female ratio was 2.7:1. Similarly in a study conducted by Amarapurkar *et al*[5] a male predominant pattern with a M:F ratio of 2.5:1 was noted.

According to Amarapurkar *et al*[5] the most common anatomic location was stomach (30.2%) followed by pancreas (23.3%). Maggard *et al*[6] stated that the small intestine was the most common site (44.7%) followed by rectum (19.6%), appendix (16.7%), colon (10.6%), and stomach (7.2%). But in our study appendix and colon were the commonest sites.

Generally, the clinical manifestations of carcinoid tumours are vague or absent unless the tumour is large enough to create a mass effect or it secretes bioactive mediators that create specific syndromes[8]. Depending on whether the secreted hormone is detectable and associated symptoms are present GEP- NETs can be divided into functioning and non-functioning tumors[9]. In the present study we had only one functioning tumour which was a case of grade I NET in pancreas. This patient presented with giddiness and hypoglycemia, suggestive of the tumour being an insulinoma. None of the patients should features of carcinoid syndrome. In a study by Amarapurkar *et al*[5] only 4.1% patients presented with carcinoid syndrome.

The NETs in general, are categorized as well differentiated and poorly differentiated. Well-differentiated tumours have characteristic organoid arrangement of tumor cells with nesting, trabecular or gyriform patterns. They have relatively uniform tumor cells with abundant neurosecretory granules, reflected by strong and diffuse immunorexpression of neuroendocrine markers. Poorly differentiated NETs have a more diffuse architecture, irregular nuclei; less cytoplasmic granularity and limited expression of neuroendocrine markers[3].

According to the 2010 WHO classification system NETs are divided into 4 categories. The first 2 classes are the pure NETs composed uniformly of cancer cells with a neuroendocrine phenotype. The tumors that show in addition to neuroendocrine cells a non-endocrine component (usually adenocarcinoma structures) exceeding at least 30% of all tumor cells are called as mixed adenoneuroendocrine carcinomas/MANEC and these are come under the 3rd category. Lastly, hyperplastic/ preneoplastic lesions of neuroendocrine cells come under category

4. The pure NETs of the gastrointestinal tract and pancreas were stratified into two groups 1) the well-differentiated NETs and 2) the poorly differentiated neuroendocrine carcinomas(NECs). The well-differentiated NETs were separated by their proliferative activity into either Grade 1 (equivalent to carcinoid) or Grade 2 NETs. The poorly differentiated ones were grouped as Grade 3 tumors and further subtyped into small cell and large cell type. They are also designated as high-grade neuroendocrine carcinomas[3][10].

The size and extent of tumor, histological pattern, type of cell, cytological atypia, necrosis, presence or absence of angioinvasion and metastasis at presentation have been the core factors studied to predict the clinical behavior of these NETs[10]. However, in the recent 2010 WHO classification the proliferative activity of the tumors determined by the mitotic rate and Ki-67 labeling index has been used as the key criteria to grade the tumors as Grade I-III (Table 2). This has been found to be of prognostic significance[3]. In the present study we had 11 cases of pure NETs. The typical organoid pattern was seen in 8 cases, other 3 cases showed features of high grade neuroendocrine carcinoma large cell type. There were 6 cases of WHO grade I, 2 cases of WHO grade II and 3 cases of WHO grade III tumor.

Table 2: The 2010 WHO Grading system for GEP-NETs³

Grade	Mitotic count (10 HPF) ^a	Ki-67 index (%) ^b
G1	<2	≤2
G2	2-20	>2-20
G3	>20	>20

a-10 HPF = 2 mm² based on each HPF being 0.2 mm² with at least 40 fields evaluated in areas at highest mitotic density.
b- Ki-67 index: % of tumour cells in a 2000 cell sample from the areas of highest nuclear labeling.

Appendiceal carcinoid tumours occur over wide age range, with female predominance .Most of these are asymptomatic and are found incidentally in appendicectomies[11]. The 3cases of appendiceal carcinoids in our study were incidental finding. Barakat *et al*[12] and other studies also substantiate the incidental occurrence of appendiceal carcinoids.

In the present study we had a single case of ileal NET. The NETs occur 6.5-8.4 times more frequently in ileum than in duodenum and jejunum[13]. Even though primary tumour was only 2.5 cm, it had already metastasized to the liver and this is in accordance to studies conducted by Kaltsas *et al*[14].

Gastric NETs are of 3 types based on clinicopathologic characteristics. In the first two types there are multiple, small lesions associated with hypergastrinaemia either secondary to chronic atrophic gastritis (type 1) or as part of Zollinger-Ellison syndrome (type 2). Type 3 gastric carcinoids are large, solitary, not associated with hypergastrinaemia and commonly metastasize [14]. In this study we had a single large type 3 gastric carcinoid with hepatic metastasis at time of diagnosis.

In the present study there were 3 right sided colonic NETs. All 3 cases were men in the age range of 35 to 65 years. The size of tumour ranged from 6 cm to 13 cm. Two of these cases were high grade large cell neuroendocrine carcinoma and these had hepatic metastasis. One case was Grade II NET. This patient had regional lymph node metastasis at time of diagnosis. According to Modlin *et al* [2] colonic carcinoids are large tumors and commonly present with liver metastasis. Lauffer *et al* [13] indicated that colonic carcinoids had a female predominance with average age of 70 at the time of diagnosis, but in the present series all of the cases were men.

There was a single case of rectal carcinoid in a 52 year old female patient who had presented with weight loss and blood in stool. Grossly it was a polypoidal growth of size 2x 1 cm. According to Lauffer *et al* [13] there is no gender preponderance for rectal carcinoids and average age at diagnosis is 58.8 years. Also these lesions are generally small, sessile or polypoidal and are usually identified after bleeding episodes. This is in accordance with our study.

Out of the 2 cases of pancreatic NET, We had one case of grade III pancreatic neuroendocrine carcinoma in a 62 year old female. It was a non-functioning tumour of size 12x7x3 cm which had metastasized to the ovary. In a study conducted by Halfdanarson *et al* [15] mean age of patients with pancreatic NETs was 58.8 years and 60.2% had metastasized. These findings are in agreement with the present study. The other case was a Grade I NET/Insulinoma in 45 year old male who had presented with recurrent hypoglycemic attacks. According to Oberg *et al* [16] patients with endocrine pancreatic tumours, often present with metastatic disease, except for insulin-producing tumours, which are benign in 85% of cases.

Though, NSE is described as neuroendocrine marker, it is less explored compared to other markers like chromogranin and synaptophysin. In the present study we have used NSE as the IHC marker to study the expression status

in the tumour spectrum. NSE was diffusely positive in all 10 cases in which it was done. The intensity of staining ranged from moderate to strong cytoplasmic staining. The findings are similar to a study conducted by Simpson *et al* [17] in which all GEP NETS stained positive for NSE. According to Tzontcheva [18] NSE is present diffusely in the cytoplasm of NETs, hence it is consistently positive in most of the NETs.

6. Conclusion

GEP -NETS are rare tumors occurring over a wide age range. The commonest location in our study was appendix and proximal colon. According to literature they frequently present late and less than 10% of these have the characteristic carcinoid syndrome. Appropriate use of IHC can help arise at a diagnosis easily. NSE is a good but less explored marker for NETs.

References

- [1] Warner RR. Enteroendocrine tumors other than carcinoid: A review of clinically significant advances. *Gastroenterol* 2005; 128: 1668-16842.
- [2] Modlin IM, Kidd M, Latich I, Zikusoka MN, Shapiro MD. Current status of gastrointestinal carcinoids. *Gastroenterol.* 2005; 128:1717-1751.
- [3] Klimstra DS, Modlin IR, Coppola D, Lloyd R, Suster S. The pathologic classification of neuroendocrine tumors: A review of nomenclature, grading, and staging systems. *Pancreas* 2010; 39:707-712.
- [4] Modlin IM, Oberg K, Chung DC, Jensen RT, de Herder WW, Thakker RV, *et al.* Gastroenteropancreatic neuroendocrine tumours. *Lancet Oncol.* 2008; 9:61-72.
- [5] Amarapurkar DN, Juneja MP, Patel ND, Amarapurkar AD, Amarapurkar PD. A retrospective clinicopathological analysis of neuroendocrine tumors of the gastrointestinal tract. *Trop Gastroenterol.* 2010; 31(2):101-4.
- [6] Maggard MA, O'Connell JB, Ko CY. Updated Population-Based Review of Carcinoid Tumors. *Ann Surg.* 2004; 240: 117-122.
- [7] Modlin IM, Lye KD, Kidd M. A 5-decade analysis of 13715 carcinoid tumors. *Cancer.* 2003; 97: 934-959.
- [8] Fenoglio-Preiser CM. Gastrointestinal Neuroendocrine / Neuroectodermal Tumors. *Am J Clin Pathol.* 2011; 115(Suppl 1):79-93.
- [9] Barakat MT, Meeran K, Bloom SR. Neuroendocrine tumours. *Endocr Relat Cancer* 2004; 11:1-18.
- [10] Kloppel G. Classification and pathology of gastroenteropancreatic neuroendocrine neoplasms. *Endocr Relat Cancer.* 2011; 18:1-16.
- [11] Hornick JL. Tumors of The Small and Large intestine, Including Anal Canal. In: Christopher

- DM Fletcher (ed). Diagnostic Histopathology of Tumors. 10th Ed. Philadelphia: Elsevier; 2013:434-476.
- [12] Barakat J, Reese D, Menezes G. Carcinoid tumors of the appendix in children: a reminder. *Clin Pract Rev.* 2003; 4(2):69-72.
- [13] Lauffer JM, Zhang T, Modlin IM. Review article: current status of gastrointestinal carcinoids. *Aliment Pharmacol Ther.* 1999; 13:271-287.
- [14] Kaltsas GA, Besser GM, Grossman AB. The diagnosis and medical management of advanced neuroendocrine tumors. *Endocr Rev.* 2004; 25: 458-511.
- [15] Halfdanarson TR, Rabe KG, Rubin J, Petersen GM. Pancreatic neuroendocrine tumors (PNETs): incidence, prognosis and recent trend towards improved survival. *Ann Oncol.* 2008; 19:1727-33.
- [16] Oberg K, Akerstrom G, Rindi G, Jelic S. Neuroendocrine gastroenteropancreatic tumours: ESMO Clinical Practice Guidelines for diagnosis, treatment and follow-up. *Ann Oncol.* 2010;21(suppl 5): 223-227
- [17] Simpson S, Vinik AI, Marangos PJ, Lloyd RV. Immunohistochemical Localization of Neuron-Specific Enolase in Gastroenteropancreatic Neuroendocrine Tumors. Correlation with Tissue and Serum Levels of Neuron-Specific Enolase. *Cancer.* 1984; 54:1364-1369.
- [18] Tzontcheva A. Neuroendocrine Tumors – Laboratory Diagnosis. *J Med Biochem.* 2010; 29 (4): 254–264.