

**Research Article**

**Study on variations in the palmar cutaneous branch of median nerve**

**Raviprasanna K. H<sup>\*1</sup>, Poornima G. C<sup>2</sup> and Dakshayani K.R<sup>3</sup>**

<sup>1</sup>Assistant Professor, Department of Anatomy, Sree Narayana Institute of Medical Sciences, North Kuthiathode, Chalakka, Ernakulam, Kerala.

<sup>2</sup>Associate Professor, Department of Anatomy, Mysore Medical College and Research Institute, Mysore, Karnataka.

<sup>3</sup>Professor and HOD, Department of Anatomy, Mysore Medical College and Research Institute, Mysore, Karnataka.

**\*Correspondence Info:**

Dr. Raviprasanna K. H  
Assistant Professor,  
Department of Anatomy,  
Sree Narayana Institute of Medical Sciences,  
North Kuthiathode, Chalakka, Ernakulam, Kerala.  
E-mail: [pravi\\_kh81@yahoo.in](mailto:pravi_kh81@yahoo.in)

**Abstract**

**Introduction:** Variations in the anatomy of nerves at wrist have been recognised to be of importance to surgeon. Attention has been called for injury to palmar cutaneous branch of median nerve as a cause of the painful dysesthesia that follows carpal tunnel surgery. A comprehensive evaluation in wrist region is essential to avoid complications.

**Objective:** In present study the objective was to study the anatomic variations in number and side of origin of palmar cutaneous branch from median nerve.

**Materials and Methods:** The study included 51 hands from human cadavers at Department of Anatomy, Mysore Medical College & Research Institute, Mysore during the time period of 2011-13. The specimens were fixed in 10% formalin, finely dissected and the numbers and side of origin were noted.

**Results:** The palmar cutaneous branch was present in all 51 specimens and it was located under the tendons of palmaris longus & flexor carpi radialis. The palmar cutaneous branch of median nerve was single in 46 specimens (90.18%) and in 5 specimens it was observed to be multiple (9.8%). In 50 specimens the palmar cutaneous branches originated from radial side of the median nerve (98.04%) and in only one specimen (1.96%) it originated on ulnar side of the median nerve.

**Conclusion:** A key to carry out therapeutic and diagnostic procedures successfully on carpal tunnel depends on the knowledge of the possible variations of nerves which may be encountered. Such variations are not only more prone to iatrogenic injuries but they interfere in the correct interpretation of clinical conditions as well.

**Keywords:** Median nerve; Variations; carpal tunnel

**1. Introduction**

The palmar cutaneous branch is the last branch of median nerve given in the forearm before passing beneath flexor retinaculum of wrist. It supplies the skin over the lateral parts of the palm. This branch is at high risk for iatrogenic injury during carpal tunnel release. One of the most troublesome sequela is the painful neuroma which follows the damage to this nerve. Several studies have suggested that a curved longitudinal incision located on the ulnar side of the ring finger is the best incision that protects the palmar cutaneous branch.<sup>1</sup>

Carroll and Green called attention to the possibility of palmar cutaneous branch damage as a source of painful dysesthesia following surgery for carpal tunnel syndrome.<sup>2</sup> Taleisnik recommended a curved longitudinal incision located on the ulnar side of the long axis of the ring finger.<sup>3</sup> Hobbs concluded that the transverse carpal ligament should be located on the ulnar side of the long axis of the middle finger to prevent damage to the palmar cutaneous branch of median nerve in dissected 25 cadaver hands.<sup>4</sup> Neuroma of the palmar cutaneous branch of median nerve is a common complication of anterior wrist surgery after carpal tunnel decompression.<sup>5</sup>

All the above data states that palmar cutaneous branch will be affected during carpal tunnel surgery invariably; the present study aims at making the following observations in the specimens, to study the presence of multiple palmar cutaneous branches arising from median nerve and to study the side of origin of palmar cutaneous branch of median nerve to avoid further complications during carpal tunnel release.

**2. Materials & Methods**

The 51 human cadaver specimens were obtained from dissection hall, Department of Anatomy, Mysore Medical College & Research Institute, Mysore during time period of 2011-13. Out of 51 specimens, 26 were of right and 25 were of left side. These specimens were fixed in 10% formalin solution. We excluded those cadaver hands from our study which exhibited previous trauma to the upper limb, fractures, any kind of surgical procedures and pathologies.

The dissection was performed as per the Cunningham's manual of practical anatomy.<sup>6</sup> the median nerve was identified in distal forearm between tendons of flexor carpi radialis & palmaris longus. Each palmar cutaneous branch was identified using blunt dissection and traced proximally to its origin from median nerve. Each palmar cutaneous branch was traced distally until its termination in the undersurface of the skin. The numbers in variations and side of origin were noted.

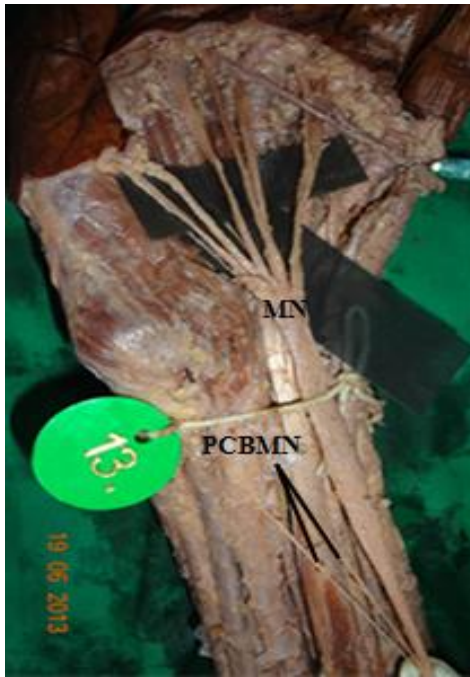**3. Results**

The palmar cutaneous branch was present in all 51 specimens; they were located under the tendons of palmaris longus & flexor carpi radialis. In 46 specimens (90.18%) the palmar cutaneous branches of median nerve were single and in 5 specimens (9.8%) it was observed to be multiple (Figure no-1 and Table: 1). In 50 specimens the palmar cutaneous branches originated from radial side of the median nerve (98.04%) and in only one specimen (1.96%) it originated on ulnar side of the median nerve (Figure no-2).

Table 1: Origin of palmar cutaneous branch of median nerve

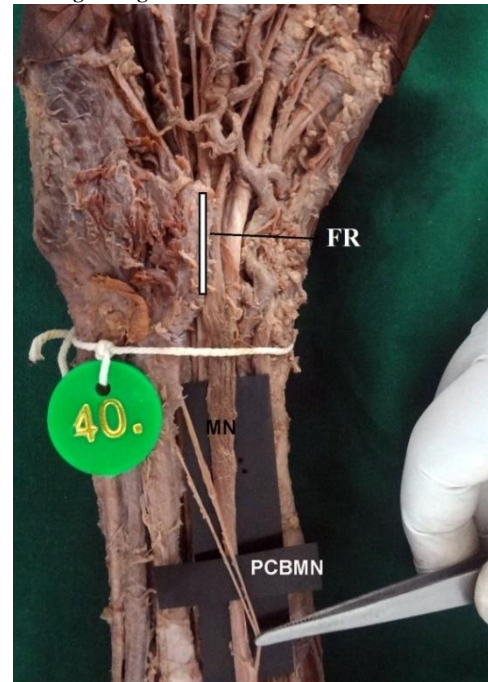
Origin of PCBMN	Site of origin	Right		Left		Total
		N	%	N	%	
Single PCBMN	Given from radial side	25	49.01	21	41.17	46 (90.18%)
	Given from ulnar side	1	1.96	3	5.88	
Multiple PCBMN	Given from radial side	0	0	1	1.96	5 (9.8%)
	Given from ulnar side	0	0	1	1.96	
Total		26	50.97	25	49.01	51 (99.98%)

Figure No-1. Showing the multiple palmar cutaneous branches of median nerve.



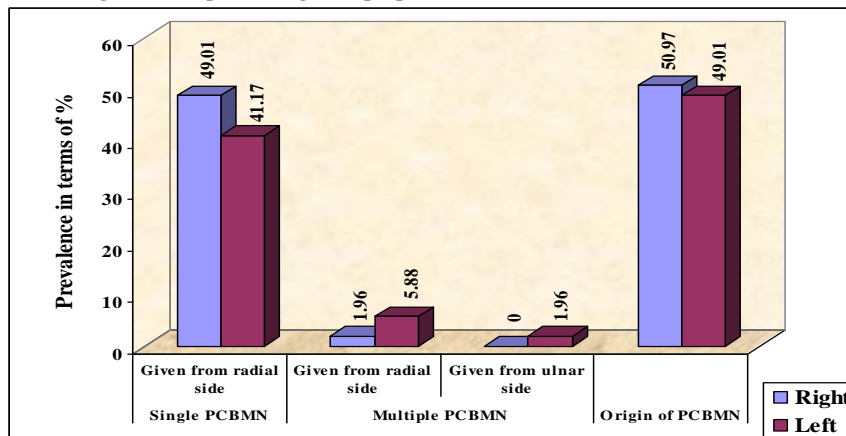
PCBMN- Palmar cutaneous branch of median nerve, MN - Median Nerve, FR- Flexor Retinaculum

Figure No-2. Showing the multiple palmar cutaneous branches originating from ulnar side of median nerve.



PCBMN- Palmar cutaneous branch of median nerve, MN - Median Nerve, FR- Flexor Retinaculum.

Figure 3: Graph showing multiple palmar cutaneous branch of median nerve



#### 4. Discussion

Palmar cutaneous branch being last branch of the median nerve given off in the forearm was present in all dissected specimens. In the present study, origin of single palmar cutaneous branch of median nerve was more from radial side than ulnar side (98.04%). This observation is similar to study done by Mofikoya *et al.*,<sup>1</sup> Juh-Wen *et al.*<sup>9</sup> and Abdulla *et al.*<sup>10</sup> Only in one specimen did the palmar cutaneous branch originate on the ulnar side (1.96%). Multiple palmar cutaneous branches were seen in 9.80% as compared to study done by Mofikoya *et al.*<sup>1</sup> in 40 specimens.

Palmar cutaneous branch is vulnerable in procedures involving distal forearm and palms particularly in carpal tunnel release. Up to one-third of all complications related to carpal tunnel release are attributable to the palmar cutaneous branch injury.

In 1972, Carroll & Green discussed the significance of Anatomical details of the palmar cutaneous branches in the wrist region and high lightened the problem of injury to this nerve, which could lead to post-operative symptoms ranging from mild annoyance to major hand disability.<sup>2</sup>

In 1973, Taleisnk dissected 12 cadaver hands and defined the origin, course and branches of palmar cutaneous branch of median nerve. Taleisnk recommended that a curved longitudinal incision be located on the ulnar side of the ring finger ray and extended through the skin, subcutaneous tissue and transverse carpal ligament.<sup>3</sup>

In 1990, Hobb's dissected 25 fresh cadaver hands and suggested that all branches of the palmar cutaneous nerve can be avoided during carpal tunnel decompression if the skin incision is made 1 cm ulnar to the axis of the third metacarpal.<sup>4</sup>

In 1993, Naff *et al* reported that the origin of palmar cutaneous branch was constant (from radial side of median nerve) in all 21 dissected cadaver specimens.<sup>7</sup>

In 1995, Duncan *et al.* reported a 44 year old woman complaining of 6 month history of pain, numbness and tingling in the palmar triangular area of right hand which on surgical exploration revealed the compression of palmar cutaneous branch of median nerve by fibres of palmaris longus tendon. Decompression was done to relieve the symptoms.<sup>8</sup>

In 2004, Juh-Wen *et al* reported 88.3% of palmar cutaneous branches originated from radial side of median nerve (106 specimens) and in 14 specimens (11.7%) from ulnar side of the nerve out of 120 human hands used for study.<sup>9</sup>

In 2009, Abdulla *et al.* studied 55 patients who underwent open carpal tunnel release at wrist joint and observed origin of palmar cutaneous branches was from the ulnar side of the median nerve and piercing ulnar margin of transverse carpal ligament in 3 cases (5.45%).<sup>10</sup>

In 2012, Mofikoya *et al.* observed multiple cutaneous branch of median nerve in one specimen out of 40 cadaver wrists used for dissection and in 37 hands (92.5%) the palmar cutaneous branches originated from radial side of the nerve and in 3 hands (7.5%) it originated from ulnar side of the nerve.<sup>1</sup>

## 5. Conclusion

A key to carry out therapeutic and diagnostic procedures successfully on carpal tunnel depends on the knowledge of the possible variations of nerves which may be encountered. Such variations are not only more prone to iatrogenic injuries but they interfere in the correct interpretation of clinical conditions as well.

In the present study an attempt is made to know the possible variations of palmar cutaneous branch of median nerve so as to provide additional information which may help to decrease the risk of diagnostic and operative complications.

Such variations of peripheral nerves noticed in routine surgical procedures or in traumatic injuries should be included into the surgical training programmes to help avoiding iatrogenic injuries.

## References

1. Bolaji O Mofikoya, Andrew O Ugburo. Anatomic variations in the palmar cutaneous branch of median nerve among adults in Lagos, Nigeria. *Nigerian Journal of Surgery* 2012 Jul-Dec; 18(2):85-6.
2. Carroll R, Green D. The significance of the palmar cutaneous nerve at the wrist. *Clin Orthop* 1972; 83:24-28.
3. Taleisnk J. The palmar cutaneous branch of the median nerve and approach to the carpal tunnel. *J Bone Joint Surg Am* 1973;1212-7.
4. Hobbs RA, Magnussen PA, Tonkin MA. Palmar cutaneous branch of the median nerve. *J Hand Surg Am* 1990;15A:38-43.
5. Das SK, Brown HG. In search of complications in carpal tunnel decompression. *Hand* 1976;8:243-9.
6. Romanes,GJ. The forearm & hand. In: Cunningham's Manual of Practical Anatomy. 15<sup>th</sup> ed. Oxford University Press, 1986.vol.1, p.740104.
7. N Naff, A.L.Dellon, S.E.Mackinnon. The Anatomical course of the palmar cutaneous branch of the median nerve, including a description of its own unique tunnel. *Journal of Hand Surgery* (British & European volume, 1993) 18B:316-7.
8. Duncan GJ, Yospur G, Gomez-Garcia A, Lesavoy MA. Entrapment of the palmar cutaneous branch of the median nerve by a normal palmaris longustendon. *Ann Plast Surg* 1995; 35:534-536.
9. Juh-Wen Cheung, Jia-FwuShyu, Chih-ChuanTeng, Tien Hua Chen, Cheng-Hsi Su, Yi-Ming Shyr, *et al.*. The Anatomical variations of the palmar cutaneous branch of the median nerve in Chinese adults. *Journal of the Chinese Medical Association* 2004; 67(1):27-31.
10. Abd-Alla MA, Saad AM, Ismaeel FT. Anatomical variations of median nerve at the wrist joint in open carpal tunnel release. *Tikrit Medical Journal* 2009; 15(1):133-9.