

**Case Report**

## **Amyand's hernia: 3 rare case presentations and review of literature**

**Sumit Sharma\***, Rohan Jain, Honeyपालsinh H Maharaul and R.P. Bharaney

*Department of General Surgery, SBKSMIRC, India*

**\*Correspondence Info:**

Dr. Sumit Sharma

3<sup>rd</sup> year resident,

Department of General Surgery, SBKSMIRC, India

E-mail: [sumitdr@yahoo.in](mailto:sumitdr@yahoo.in)

**Abstract**

A vermiform appendix in an inguinal hernia, inflamed or not, is known as Amyand's hernia. We report 3 cases of Amyand's hernia which is a rare presentation with a literature review. Appendicectomy and hernioplasty may be performed at the same time, since the repair of the hernia should be performed without prosthesis implantation due to the contamination of the operating field.

**Keywords:** Amyand's hernia, Appendicectomy

### **1. Introduction**

A vermiform appendix in an inguinal hernia sac, with or without appendicitis, is called Amyand's hernia. Inguinal hernia repair is one of the most common operations in surgical practice. Despite that, hernias often pose technical dilemmas, even for the experienced surgeon<sup>2</sup>. The surgeon may encounter unusual findings, such as a vermiform appendix partly or fully contained in the hernia sac, inflamed or non-inflamed, stretched or curved, and adhered or not adhered to the sac walls. Whether or not an appendectomy should be performed at the same times as the hernia repair is debatable. The aim of this study is to present the experience of our hospital with Amyand's hernias along with a review of the literature on this subject.

### **2. Case presentations**

Three patients presented with Amyand's hernia to surgical Opd. A 36-year-old man had an inflamed vermiform appendix in his hernial sac (acute appendicitis), presenting as an incarcerated right groin hernia, and underwent simultaneous appendectomy and lichenstein repair. Two patients, a 41 and 53 years old, had normal appendix in their sac, which clinically appeared as non-incarcerated right groin hernias. 41 year patient was treated by Lichenstein repair with appendisectomy and 53 year patient was treated by reduction of appendix with Lichenstein repair.

#### **2.1 Case 1**

A 36 year male patient came in surgery OPD with complaints of swelling and pain in right inguinal region. Patient had 4 day history of pain in umbilical region and radiates to suprapubic region. Swelling increased in size over a period of 2 days and intensity of pain also increased. Local examination of swelling was tender, erythematous and nonreducible. This was diagnosed as an inflamed irreducible right inguinal hernia. Routine laboratory investigation included blood test analysis and abdominal radiograph was normal. Patient was planned for surgery.

During surgery, an inflamed and oedematous mass was found inside the inguinal canal. This mass was identified as the tip, body of the appendix, and caecum which adhered to the indirect hernia sac. A small amount of clear fluid was noted in the peritoneum. The base of appendix was free of inflammation, so appendisectomy was done and posterior wall of inguinal canal was repaired, and after the excision of part of the sac, Lichenstein repair done. A vacuum drain was placed which was removed on second post operative day. The patient was given intravenously ceftriaxone 1gm and inj.metrogyl 100 ml daily for 3 days. The postoperative course was uneventful and the patient was discharged in good condition within 10 days.

#### **2.2 Case 2**

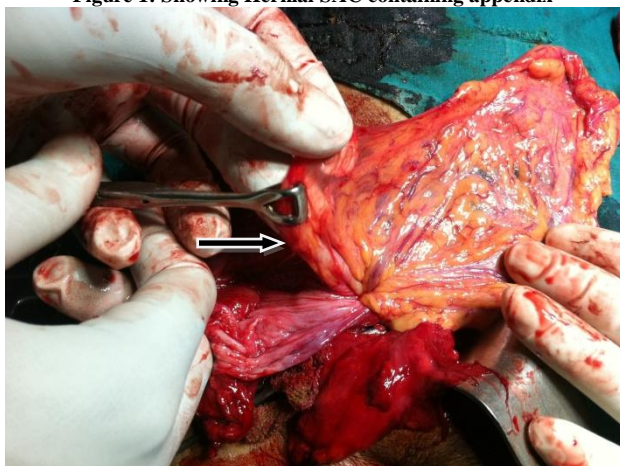
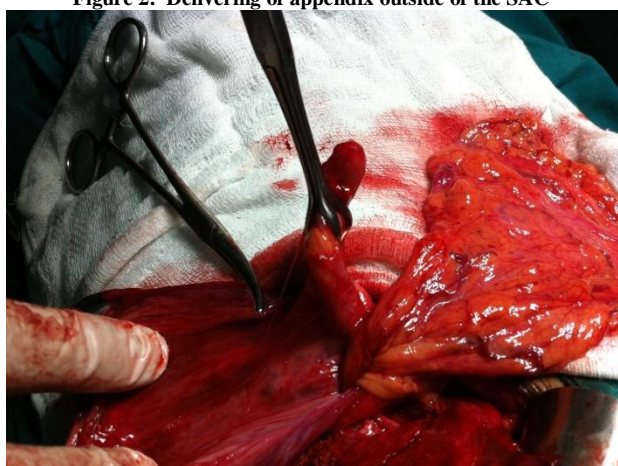
A 41-year old male patient came with presenting complaints of non reducible swelling in right inguinal region since 2 days. The swelling was appeared 2 years back which was gradual in onset and progressive in nature. When it was first appeared it was reducible, it bulged out in standing position and disappeared on lying down position. But since 2 days the swelling was irreducible and associated with dragging type of pain over the swelling while patient walked. There was no erythema, no local rise in temperature, no tenderness, no nausea, no vomiting, and no fever. All routine blood investigations were normal. The patient was diagnosed as right sided irreducible inguinal hernia. The patient was planned for surgery.

During surgery appendix is found in indirect hernial sac. Appendix was normal. There were no signs of appendicitis. Appendisectomy was done. Posterior wall of inguinal canal was repaired after the excision of part of the sac. Lichenstein repair was done. The patient was given intravenous ceftriaxone 1gm and amikacin 500 mg 5 days.

#### **2.3 Case 3**

A 53year for 3 days. The postoperative course was uneventful and patient was discharged in good condition within old male patient came in surgery OPD with complaints of swelling in the right inguinal region since 10 years which was gradual in onset and progressive in nature. The swelling was not associated with any pain. On local examination of the swelling cough impulse was present, ring occlusion test was positive and to get above the swelling was not possible. The patient was diagnosed as right sided reducible indirect inguinal hernia. All routine blood investigations were normal and patient was scheduled for surgery.

During surgery appendix was present in the indirect hernia sac. Appendix was not inflamed. Appendisectomy was not done. Contents of the indirect sac were reduced. Excision of the sac was done. Lichenstein repair was done. The patient was given intravenous antibiotics. The post operative course was uneventful and patient was discharged on 5<sup>th</sup> day.

**Figure 1: Showing Hernial SAC containing appendix****Figure 2: Delivering of appendix outside of the SAC**

### 3. Discussion

Claudius Amyand (1660-1740), a French surgeon working at St George's and Westminster hospitals in London, performed the first successful appendectomy in 1735, on an 11-year-old boy who presented with an inflamed, perforated appendix in his inguinal hernia sac. According to the surgeon's descriptions, the patient also had "a fistula between the scrotum and thigh" and the operation proved to be "very complicated and perplexing," as the pathology consisted of a chronically inflamed appendix contained within the inguinal hernia sac, perforated by a previously swallowed pin. At surgery the appendix was removed. The patient eventually recovered and was "discharged with a truss, which he was ordered to wear for some time." The case was published in the Philosophical Transactions of the Royal Society of London<sup>1</sup>.

Acute appendicitis within an inguinal hernia accounts for 0.1% of all cases<sup>2,7</sup>. Inflammation of the appendix is attributed to external compression of the appendix at the neck of the hernia. The inflammatory status of the vermiform appendix determines the surgical approach and the type of hernia repair. All surgeons agree that if appendicitis exists, the repair of the hernia should be performed with Bassini, Shouldice techniques or Lichtensteins technique.

In the case of a normal appendix, incidentally found within the hernia sac, the performance of a prophylactic appendectomy along with the hernia repair is not favored by many authors<sup>9,10</sup> but can be done as it may complicate later. Appendectomy adds the risk of infection to an otherwise clean procedure. Although general rules are certainly acceptable, there are more clinical scenarios to keep in mind. Losanoff and Basson have distinguished four basic types of Amyand's hernias, which should be treated differently<sup>4,5</sup>.

**Table 1: Classification of Amyand's hernias after Losanoff and Basson<sup>4,5</sup>**

Classification	Description	Surgical Management
Type 1	Normal appendix within an inguinal hernia	Hernia reduction, mesh repair, appendectomy in young patients
Type 2	Acute appendicitis within an inguinal hernia, no abdominal sepsis	Appendectomy through hernia, primary endogenous repair of hernia, no mesh
Type 3	Acute appendicitis within an inguinal hernia, abdominal wall or peritoneal sepsis	Laparotomy, appendectomy, primary repair of hernia, no mesh
Type 4	Acute appendicitis within an inguinal hernia, related or unrelated abdominal pathology	Manage as types 1 to 3 hernia, investigate or treat second pathology as appropriate

The absence of inflammation in Type 1 advocates elective hernioplasty. Using a prosthetic material in such cases carries the expectation of improved longevity of the repair. It avoids tension on the suture lines and circumvents the metabolic problems related to collagen deficiency, which is known to exist in hernia patients. Whether to remove or leave behind a normal appendix in this clinical scenario cannot be determined because no evidence-based information exists. The decision is rather based on common sense, relating to the patient's age, life expectancy, and life-long risk of developing acute appendicitis and the size and overall anatomy of the appendix. Pediatric or adolescent patients have a significantly higher risk of developing acute appendicitis and should therefore have their appendices removed, compared to middle-aged or elderly individuals in whom the appendix should probably be left intact<sup>4,5</sup>. Long, curved appendices have a higher risk of inflammation.

Additionally a long appendix which stretches the cecum may cause chronic pain if left behind. Manipulations to detach and reduce the appendix in the abdomen may stimulate the inflammatory process. Furthermore, consideration of appendectomy in young patients must take into account the size of the hernia, since prosthetic material is contraindicated but large hernias are more likely to recur if repaired by making use of endogenous tissue only.

The decision is easier in Type 2 hernias, where appendicitis is found, as they should be treated with appendectomy; however the hernia repair should be performed without making use of prosthetic materials. On the other hand, in septic patients with Amyand's hernia Type 3 (acute appendicitis with peritonitis), or Type 4 (acute appendicitis with other pathology), even the hernioplasty may be contraindicated if the patient's condition is poor or life expectancy is limited.

Looking at our case series, in case 1 we decided not to place a mesh, due to the presence of acute inflammation--appendicitis. This guarded the hernia repair from possible future extension of inflammation in the mesh. In contrast, a mesh was placed in cases 2 and 3 with a normal appendix in their sac. However, in these cases, we decided not to proceed with appendectomy, because this additional procedure could lead to potential damage of the plastic hernia repair. In case 4, given the young age of our patient and the long appendix in his sac, we decided that the increased likelihood for appendicitis in the future necessitated an individual appendectomy. Consequently, our recommendation is that the decision to perform an appendectomy or/and use the mesh-plug technique should always be individualized to the patient.

#### 4. Conclusion

In conclusion, a surgeon may encounter unexpected intraoperative findings, such as an Amyand's hernia. The decision as to whether one should perform a simultaneous appendectomy and hernia repair is multifactorial. It is important to be aware of all clinical settings and an appropriate and individualized approach should be applied.

#### References

1. Amyand C: Of an inguinal rupture, with a pin in the appendix caeci, incrusted with stone; and some observations on wounds in the guts. *Philos Trans R Soc London* 1736, 39:329-336.
2. Ballas K, Kontoulis T, Skouras C, Triantafyllou A, Symeonidis N, Pavlidis T, Marakis G, Sakadamis A: Unusual findings in inguinal hernia surgery: Report of 6 rare cases. *Hippokratia* 2009, 13(3):169-171.
3. De Garengot RJC: Traite des operations de chirurgie. 2nd edition. Paris: *Huart*; 1731:369-371.
4. Losanoff JE, Basson MD: Amyand hernia: what lies beneath--a proposed classification scheme to determine management. *Am Surg* 2007, 73(12):1288-1290.
5. Losanoff JE, Basson MD: Amyand hernia: a classification to improve management. *Hernia* 2008, 12(3):325-326.
6. Llullaku SS, Hyseni HS, Kelmendi BZ, Jashari HJ, Hasani AS: A pin in appendix within Amyand's hernia in a six-years old boy: case report and review of literature. *World J Emerg Surg* 2010, 5:14.
7. Milanchi S, Allins AD: Amyand's hernia: history, imaging, and management. *Hernia* 2008, 12(3):321-322.
8. Livaditi E, Mavridis G, Christopoulos-Geroulanos G: Amyand's hernia in premature neonates: report of two cases. *Hernia* 2007, 11(6):547-549.
9. Sharma H, Gupta A, Shekhawat NS, Memon B, Memon MA: Amyand's hernia: a report of 18 consecutive patients over a 15-year period. *Hernia* 2007, 11(1):31-35.
10. D'Alia C, Lo Schiavo MG, Tonante A, Taranto F, Gagliano E, Bonanno L, Di Giuseppe G, Pagano D, Sturmiolo G: Amyand's hernia: case report and review of the literature. *Hernia* 2003, 7(2):89-91.
11. Salemis NS, Nisotakis K, Nazos K, Savrinou P, Tsohataridis E: Perforated appendix and periappendicular abscess within an inguinal hernia. *Hernia* 2006, 10(6):528-530.