

Review Article

Perforation of gastric gastrointestinal stromal tumor: A rare phenomenon & review of literature

Vijay P Agrawal*, Nitin Wasnik, Jitendra Yede and Arpit Gupta

Department of General Surgery, NKPSIMS, Nagpur, India

***Correspondence Info:**

Dr. Vijay P Agrawal,
Assistant Professor,
Department of General Surgery,
NKPSIMS, Nagpur, India
E-mail: vijugunnu@gmail.com

Abstract

Gastrointestinal stromal tumor (GIST) is the term for a specific, immunohistochemical KIT-positive mesenchymal neoplasm of the gastrointestinal (GI) tract and abdomen. About 60% of GISTs occur in the stomach, 20% - 30% occur in the small intestine, and 10% occur in other parts of the GI tract. The most commonly known symptoms of small bowel GISTs are abdominal pain, abdominal mass, GI-bleeding, partial or complete small bowel obstruction. Spontaneous perforation of GIST is an extremely rare presentation.

Keywords: Gastric; Perforation; Gastrointestinal stromal tumor

1. Introduction

Gastrointestinal stromal tumor (GIST) is the term for a specific, immunohistochemical KIT-positive mesenchymal neoplasm of the gastrointestinal (GI) tract and abdomen. About 60% of GISTs occur in the stomach, 20% - 30% occur in the small intestine, and 10% occur in other parts of the GI tract. Pathologic activation of KIT signal transduction appears to be a central event in GIST pathogenesis.^{1,2,3}

The most commonly known symptoms of small bowel GISTs are abdominal pain, abdominal mass, GI-bleeding, partial or complete small bowel obstruction.⁴ Spontaneous perforation of GIST is an extremely rare presentation.⁵ Perforated viscus is the frequent cause for Non-traumatic pneumoperitoneum. 14% of all radiological confirmed pneumoperitoneum are due to malignancy.⁴ There is only one case of Gastric gastrointestinal stromal tumor perforation have been reported in the literature. We present first Indian case report of Perforated Gastric intestinal stromal tumor and reviewed the available literature.

2. Case study

A 65 year old female presented with acute onset of pain in the epigastrium. There was history of decreased appetite & loss of weight. There was no history of vomiting, hematemesis, malaena, upper abdominal discomfort or heaviness after meals. Bowel & bladder habits were normal. Patient was afebrile. Vitals were stable. Pallor was present. There was no icterus, cyanosis, clubbing and lymphadenopathy. Abdomen examination revealed features of small epigastric hernia with diffuse peritonitis.

Erect X-ray abdomen was done which revealed Gas under right hemidiaphragm. Her blood investigation was normal except for Hemoglobin-8 gm/dl.

Patient was taken up for emergency exploratory laparotomy. Intraoperatively there was small epigastric hernia. There was collection of about 1.5-2 L intraperitoneal infected fluid. The stomach was contracted and there was growth involving almost whole of the stomach except for the fundus. There was perforation of size 0.5 × 0.5 cm in the stomach growth near the pylorus. The stomach was fixed posteriorly and was not mobile. There were features of liver and peritoneal secondaries. Biopsies were taken from stomach, Liver and peritoneum. Perforation was repaired with omental patch and through wash was given. Histopathology of the biopsies revealed features likely of gastrointestinal stromal tumor. Patient recovered well. She got discharged for oncologist opinion for chemotherapy and Special examination for Histopathology slides but lost to follow up.

Figure 1- Erect X-ray abdomen - Gas under Right hemidiaphragm

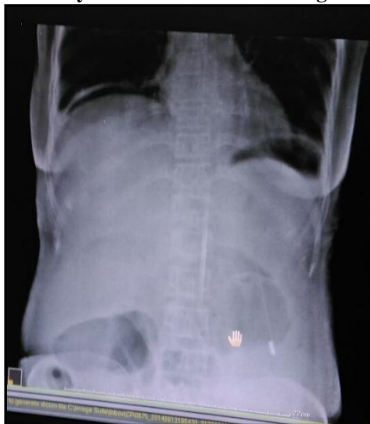

Figure 2- Epigastric hernia

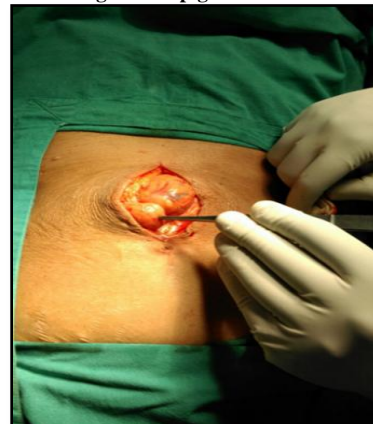
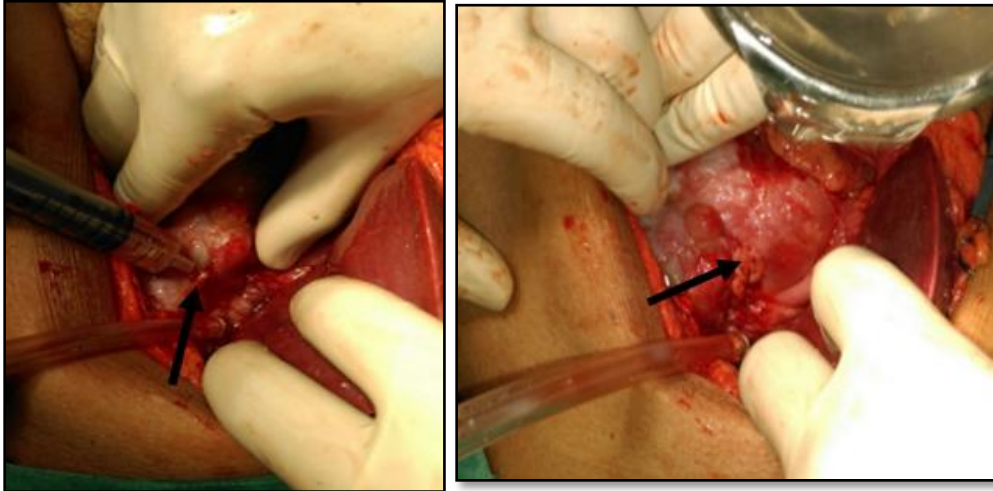


Figure 3 & 4- Site of Perforation and Stomach growth



3. Discussion

In 1983, Mazur and Clark first described GIST.⁶ If we go through the literature there are cases reported on perforation of jejunal GIST.⁷ Skipworth, J.R et al described first gastric GIST perforation and given review on the literature available till now. (Table 1)⁸

Table 1: Summary of case reports describing perforated gastrointestinal stromal tumours

Case Report	Age/ Sex	Past medical history	Presentation	Operative management	Diagnosis/ Anatomic site	Malignant potential	Outcome
Skipworth 2014	51F	Reflux symptoms	Abdominal pain → ultrasonography showed → inflammation CT → perforated mass in gastric antrum	Laparotomy: distal gastrectomy with Roux-en-Y retrocolic gastrojejunostomy	Perforated 5cm GIST arising from gastric antrum	Low	Well (6 months following surgery); treated with imatinib
Mitura, 2012	63F	Nil	Hypogastric abdominal pain and fever → outpatient ultrasonography → hypogastric tumour	Laparotomy: segmental ileal resection	Perforated 14cm GIST arising from ileal Meckel's diverticulum	High	Well with no disease recurrence (6 months following surgery); no chemotherapy given
Chou, 2011	76F	Nil	Lower abdominal cramping pain CT → intraperitoneal free air and distended diverticulum	Laparoscopy: segmental ileal resection	Perforated 3.2cm GIST arising from ileal Meckel's diverticulum	High	Unknown
Dogrul, 2010	86F	Hypertension, coronary artery disease, cholecystectomy, total hip replacement, TAH and BSO	Abdominal pain, nausea and vomiting. CT → ileal perforation, with dilation and oedema of proximal ileum	Laparotomy: 20cm small bowel resection with end-to-end anastomosis; re-exploration on day 7 due to anastomotic leak	Perforated 8cm GIST arising from ileal Meckel's diverticulum	High	Died 2 months following surgery from sepsis / multiorgan failure
Hur, 2008	70M	Previous high risk gastric GIST (1993), recurrence in gastrohepatic ligament (2001), hepatic recurrence (2002)	Patient on chemotherapy (sunitinib) at time of presentation with diffuse abdominal pain. CT → necrosis of recurrent hepatic mass and perforation of invaded transverse colon	Hepatic recurrence not resected due to poor patient baseline; percutaneous drainage of intraperitoneal pus, with antibiotic treatment	Perforated hepatic / colonic recurrence	High	Well on chemotherapy, with stable disease (after completion of second cycle of sunitinib)
Efremidou 2006	66M	Two previous episodes of upper gastrointestinal haemorrhage (managed conservatively)	Diffuse abdominal pain, vomiting and abdominal distension (no abnormalities on CXR, AXR or ultrasonography)	Laparotomy: 13cm ileal resection and regional lymph node excision	Perforated 7cm GIST arising from ileum	Intermediate	Well with no disease recurrence (44 months following surgery); chemotherapy (imatinib) given for first 20 months
Szentpáli, 2004	70M	Type 2 diabetes mellitus, cerebrovascular disease, myocardial infarction, hypertension	Right lower abdominal pain. ultrasonography → thick and hyper vascularised bowel wall	Laparotomy: 15cm small bowel resection with side-to-side anastomosis	Perforated 1.5cm GIST arising from small bowel Meckel's diverticulum	'Borderline' (small tumour size, low mitotic index but mucosal invasion)	Well with no disease recurrence (3 years following surgery)

Our case was 65 year old female presented with pain abdomen with features of peritonitis. X-ray abdomen revealed features of perforation peritonitis. Intraoperatively there was perforated gastric GIST in advanced stage. So perforation closure was done with omental patch. Planning was to give chemotherapy and palliation. But patient lost to follow up.

4. Conclusion

Though perforation of Gastric gastrointestinal stromal tumor is extremely rare but should be kept in mind while dealing with GIST stomach or Perforation peritonitis.

References

1. Heinrich MC, Rubin BP, Longley BJ, Fletcher JA: Biology and genetics aspects of gastrointestinal stromal tumors: KIT activation and cytogenetic alterations. *Hum Pathol* 2002; 33: 484-495.
2. Hirota S, Isozaki K, Moriyama Y, Hashimoto K, Nishida T, Ishiguro S, Kawano K, Hanada M, Kurata A, Takeda M, Tunio GM, Matsuzawa Y, Kanakura Y, Shinomura Y, Kitamura Y: Gain-of-function mutations of c-kit in human gastrointestinal stromal tumors. *Science* 1998; 279:577-580.
3. Miettinen M, Majidi M, Lasota J: Pathology and diagnostic criteria of gastrointestinal stromal tumors (GISTs): A review. *Eur J Cancer* 2002; 38^{sup}: S39-S51.
4. Kumar, A., et al. The Etiology of Pneumoperitoneum in the 21st Century. *Journal of Trauma and Acute Care Surgery* 2012; 73: 542-548.
5. Sornmayura, P. Gastrointestinal Stromal Tumors (GISTs): A Pathology View Point. *Journal of the Medical Association of Thailand*, 2009; 92: 124-135.
6. Mazur, M.T. and Clark, H.B. Gastric Stromal Tumors. Reappraisal of Histogenesis. *American Journal of Surgical Pathology*, 1983; 7: 507-519.
7. Roy, S.D., Khan, D., De, K.K. and De, U. Spontaneous Perforation of Jejunal Gastrointestinal Stromal Tumor. Case Report and Review of Literature. *World Journal of Emergency Surgery* 2012; 7: 37.
8. Skipworth, J.R., Fanshawe, A.E., West, M.J. and Al-Bahrani, A. Perforation as a Rare Presentation of Gastric Gastrointestinal Stromal Tumors: A Case Report and Review of the Literature. *Annals of the Royal College of Surgeons of England*, 2014; 96: 96E-100E.