

Review Article

Ultrasonography; A boon as a diagnostic & therapeutic aid in dentistry: A review

Dharti N¹, Neerjesh P.², Richa Wadhawan^{*3}, Kaushal Luthra⁴, Yehoshuva Reddy⁵ and Gaurav Solanki⁶

¹Post graduate, Oral Medicine & Radiology, Pacific dental college, Udaipur, India

²Senior Lecturer, Moti Lal Nehru Medical College, Allahabad, India

³Senior Lecturer, Institute of Dental Education & Advance Studies, Gwalior, India

⁴Professor & HOD, Department of Periodontics & Oral Implantology, Institute of Dental Education & Advance studies, Gwalior, India

⁵Professor & HOD, Department of Oral Medicine & Radiology, Institute of Dental Education & Advance studies, Gwalior, India

⁶Post graduate, Oral Medicine & Radiology, Jodhpur Dental College General Hospital, Jodhpur, India

*Correspondence Info:

Richa Wadhawan,

Senior Lecturer,

Institute of Dental Education & Advance Studies,

Gwalior, Madhya Pradesh, India

E-mail- richawadhawan@gmail.com

Abstract

Dentistry in the modern era is emerging with the use of advanced imaging techniques such as Computed tomography, Magnetic Resonance Imaging, Nuclear Medicine and Ultrasound imaging, of which MRI and Ultrasound imaging are the only imaging technique, which operate without causing radiation hazards to the patients. Ultrasound imaging is one of the advanced imaging techniques which use sound waves for viewing the normal and pathological conditions involving bone and soft tissue of the oral and maxillofacial region. In dentistry for detecting a bony or soft tissue mass, patients are exposed to multiple radiographs which might cause radiation effects at the tissue and organ level. In dentistry for every case this modality cannot be used and it is more diagnostic for soft tissue lesions than hard tissue lesions. This paper reviews diagnostic applications of ultrasound imaging to dentistry, or dental ultrasonography, in all fields beginning present up through present lines of research.

Keywords: Ultrasound imaging, High Frequency Transducer, Hyperechoic, Hypoechoic

1. Introduction

The technology for producing ultrasound imaging and the characteristics of sonic waves has been known for many years. Though the first attempt of practical application of ultrasound imaging was to search the sunken titanic in 1912 and the medical application being used after World War II in late 1940s and early 1950s. The imaging techniques were not sufficiently developed those days. As technology improved, Computed tomography (CT) has been used occasionally to aid in diagnosis of conditions in the bone. However, routine use of CT is associated with high radiation doses. Even though dose reduction methods have been established, Low dose cone beam CT has been developed specifically for use in the dental and maxillofacial regions. MRI is another specialized imaging modality that does not involve the use of ionizing radiation and is important in imaging intracranial and soft tissue lesions. However, expensive equipment, increased scanning time, claustrophobia, contraindication of MRI in patients having surgical clips, cardiac pacemakers and cochlear implants in the body¹ have made the use of ultrasound imaging technology, a safe and minimally invasive procedure. Sonography was introduced in the medical field in early 1950's with steady development and requirement of Ultrasound imaging equipment for diagnosis has improved the medical field & now in dentistry. In diagnostic Ultrasound imaging high frequency sound waves are transmitted in to the body by a transducer and echoes from tissue interface are detected and displayed on a screen. The transducers are designed to produce longitudinal waves hence only those waves can pass through tissues get reflected, audio-frequency of a sound wave is 20 KHz. Anything below this is called infrasonic and above this Ultrasound imaging. Medical Ultrasound imaging uses the frequency of 1-15 MHz (2.5, 3.5, 7.5 and 10 MHz). The transducer has a special property called piezoelectric effect i.e. they can convert sound waves in to electrical waves and vice versa.²

As like X-ray, sound beam from Ultrasound imaging are waves transmitting energy, X-ray passes readily in vacuum, whereas sound requires medium for its transmission. Sound waves travel slowest in gases, at intermediate velocity in liquids and most rapidly in solids. All body tissues except bone behave like liquids and therefore, they all transmit sound at about same velocity. Ultrasonography (US) is one method of imaging which lacks radiation hazards, this imaging technique can be used for bone and soft tissue examination, either normal or pathological lesions, detection of calculi in major salivary glands, TMJ imaging, detection of fractures & vascular lesions. Proper application of this method can be of great importance in dentistry.³

The following Modes are in use:

- **A Mode:** Amplitude mode – Difference in Amplitude & depth. Used for measuring boundaries of tissues of different acoustic properties. E.g. difference between solid & cystic lesions.
- **B Mode:** Brightness Mode – Producing different echogenicity

In ultrasound imaging images, the B mode shows the anatomical surface structures of soft tissues and is commonly applied for the detection of various kinds of diseases in oral and maxillofacial regions. The ultrasound imaging image indicates the surface structures of CT and MR images. Recently, Doppler ultrasound imaging using the Doppler effect of flow in blood vessels have also been applied to evaluate the presence or absence of vascular flow in normal tissues and in diseases of the oral and maxillofacial regions. Therefore, Doppler images associated

with the B-mode can provide vascular information associated with the morphology of soft tissues. Thus, US play an important role in analyzing normal and abnormal anatomical structures.⁴

2. Application of Ultrasonography

2.1 Application of US in Dentistry

In particular, in the oral and maxillofacial regions, US may be clinically applied to evaluate salivary gland-related diseases, lymph node-related diseases, subcutaneous diseases and tongue related diseases. However, most dentists do not know the utilities of US for the diagnosis of various kinds of oral diseases and it is very disadvantageous for patients with any of the diseases mentioned above.⁵

2.2 Ultrasonography in Salivary Gland Tumors

They are rare and approximately 1 to 3% of all neoplasm's about 80% of salivary gland tumors arise from parotid gland, 60 to 80% of which are benign. In the small salivary gland, the ratio of benign to malignant tumors is higher. When the patient is presented with a palpable mass in the salivary gland or mass is suspected, diagnostic ultrasonography can be employed to:

2.3 Confirm the Presence of Mass

Ultrasound imaging can successfully detect any salivary gland mass. Detection of even small lesions was easy, especially in the parotid where its sensitivity approaches 100%.

2.4 Differentiate between Intra-And Extra glandular Lesions

Correct localization of masses is not a problem with US, and an accuracy of 98% has been reported. However, this might be difficult in the cervical part of the parotid gland (deep lobe).

2.5 Suggests Nature of the Mass Benign Vs Malignant

Identification of the mass is more difficult. Almost all of the salivary gland tumors (benign and malignant) have been reported as hypoechoic, thus an absolute differentiation is impossible.

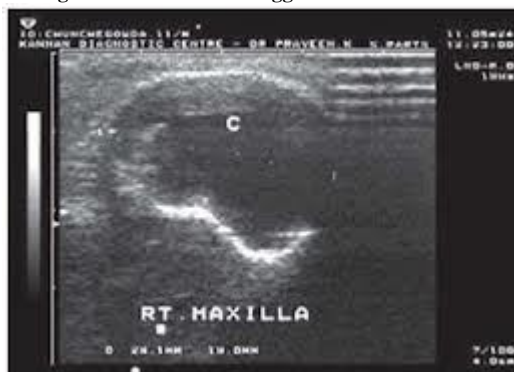Differentiation is possible to some extent based on additional findings for lesion being benign in nature, like the presence of sharp borders. Well-circumscribed tumors are more often benign. The nature of salivary gland tumors assessed by US using the sharpness of the border as the sole indicator of benignity, on the contrary, a markedly heterogeneous structure and presence of fluid-filled cystic spaces (necrosis) frequently indicate a malignant tumor. Higher vascularity seen in color Doppler has also been suggested as an indicator for malignancy but in some occasions, malignant tumors demonstrate benign features.

Table 1: Nature of the Mass Benign Vs Malignant

Benign lesions	Well defined, homogeneous and hypoechoic
Malignant lesions	Ill-defined and hypoechoic with heterogeneous internal architecture & enlarged cervical lymph node may be visible and reactive intra parotid lymph nodes

Ultrasound imaging can be used to detect parotid lesions, where solid and cystic lesions are reliably differentiated and diffuse enlargement of the parotid gland (or) focal disease is readily shown by ultrasound imaging. It can also be used for detecting sialoliths in parotid, submandibular and sublingual salivary glands, which appear as echo-dense spots with a characteristic acoustic shadow.⁶

Fig 1: Ultrasonographic picture of the swelling showing lobular shaped lesion with hypoechoic to focal hyperechogenic intenal echo pattern and posterior shadowing. These features are suggestive of a submandibular sialadenitis with calculus



Courtesy: Journal of Indian Academy of Oral Medicine and Radiology, January-March 2010; 22(1):18-26

2.6 Fine Needle Aspiration Biopsy (Fnab) or Cytology (Fnac) With US

Ultra sound can also be used during FNAC or FNAB; central sampling of solid lesions is more reliable than peripheral sampling. So, Ultra sound guidance circumvents this problem by ensuring that the lesion itself is sampled. This technique offers the ability to sample non palpable diseases gives access to different regions of the lesion and approaches the lesion from different angles. The use of spring – loaded device such as Biopty or Magnum gun to discharge the needle also offers the advantage of precise and co-ordinated cutting action. This combined with Ultrasound imaging ensures that the needle is within the lesion and does not exit the lesion. The value of US well recognized in inflammatory soft tissue conditions of the head and neck region and superficial tissue disorders of the maxillofacial region.

Ultra sound can provide the content of the lesion before any surgical procedure; both solid and cystic contents could be identified in ultrasound imaging. The mixed lesions should be considered neoplastic and should be biopsied before surgical procedure.⁷ Therefore; US examination can readily detect and diagnose salivary gland- and lymph node-related diseases and is a very useful tool for FNA biopsy (FNAB). Since Martin and Ellis first used the technique in 1930, FNAB has been clinically applied for the histologic evaluation of cervical masses. FNAB is an inexpensive, rapid, and relatively accurate diagnostic method for many kinds of diseases in the oral and maxillofacial regions. At the same time, various imaging modalities such as US, CT, and MR may also be used for the detection of lesions and for examinations that safely avoid disturbing important blood vessels and organs. Of these modalities, US imaging is the easiest to use, the least expensive, and the least invasive.⁸ In addition, the accuracy of US-guided FNAB has been shown to be relatively high despite being noninvasive. Al-Khafaji *et al.* reported that needle aspiration of parotid masses at a major referral cancer center had a sensitivity of 82%, a specificity of 86%, and an overall diagnostic accuracy of 84% using 154 parotid gland masses.⁹ Like any other noninvasive technique to assess metastatic lymph nodes, US has got its own limitations. Even though the sensitivity, specificity and accuracy of detecting metastatic lymph nodes by US are better, it is not yet proved to be 100% accurate. These drawbacks can be overcome with the application of US-fine needle aspiration cytology (FNAC).

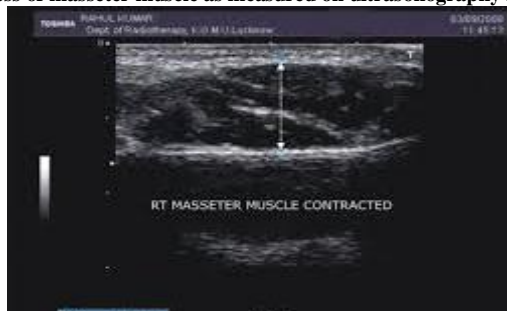
In the literature, the accuracy of US-FNAC varies from 89-97%. In addition to the good results; found that US is useful in detecting metastatic neck nodes. The advantages of US over other imaging modalities are its low cost, noninvasiveness and patient's compliance for followup.¹⁰

Also ultrasonography guided needle biopsy is a safe and efficient diagnostic procedure. It is quite difficult to compare or even combine their outcomes in a scientifically meaningful manner. Because of insufficient research data, there is a need for high-quality randomized, controlled trials in this area of medicine. Finally ultrasonography is a noninvasive, low cost procedure, and recommended as a complimentary imaging modality. US imaging is also used to guide Fine-Needle Aspiration Biopsy (FNAB) in the neck with the advantage of low cost, ease of usage and radiation safety and during biopsy of parotid gland there is chance of injuring the facial nerve or seeding neoplastic cells, under ultrasound imaging guidance these can be avoided.¹¹

2.7 US in Detection of Muscular Pathology

Ultrasound imaging with aid of high resolution transducer can demonstrate the internal muscle structures more clearly than CT. Hyper echoic bands, which correspond to the internal fascia, are usually observed on US image of normal muscles and are sometimes referred to as septa. These bands diminish or disappear with inflammation; hence this is an important structural index of masseteric infection. Ultrasound imaging is also an accurate modality for measuring the thickness of muscles, data regarding thickness may provide information useful in diagnosis and treatment especially in follow up examination.¹²

Fig 2: Thickness of masseter muscle as measured on ultrasonography in relaxed state



Core Curriculum, The: Ultrasound imaging 1st Edition. 2001 Lippincott Williams & Wilkins

2.8 US in Periapical Lesions

Because clinical examination and radiographs alone are not able to differentiate between cystic and noncystic periapical lesions, ultrasound imaging is among a number of newer imaging techniques being studied for this application. In 2006 a study compared ultrasound imaging and conventional and digital radiography in diagnosing periapical lesions in 15 patients and concluded that ultrasound imaging provided accurate information on the pathological nature of the lesions. Another study compared computed tomography scans with ultrasound imaging using power Doppler flowmetry. In all 12 cases included in the study, the researchers found that the diagnosis with computed tomography and ultrasound imaging coincided with the histopathological diagnosis of the lesion. However, the authors noted, ultrasound imaging is still considered a supporting technique and may not substitute histopathology at this point. Similarly, a 2010 study compared the effectiveness of ultrasound imaging, color Doppler imaging, and conventional radiography in monitoring postoperative healing of periapical lesions of endodontic origin and this study showed that at six months, ultrasound imaging and color Doppler imaging were significantly better than conventional radiography in detecting changes in the healing of hard tissue at the surgical site.¹³

2.9 Fracture Detection by Ultra Sound¹⁴:

Ultrasound imaging in dentistry is used for detection of fractures of the maxillofacial region.

- ✓ Nasal bone fractures,
- ✓ Orbital rim fractures,
- ✓ Maxillary fractures,
- ✓ Mandibular fractures,
- ✓ Zygomatic arch fractures
- ✓ For locating the position of Mandibular condyles &
- ✓ Postoperative view can be done instantly to view the reduction & healing of fractures.

2.10 US in Vascular Lesions

In Ultrasound imaging, color Doppler sonography has been developed to identify vasculatures and to enable. Evaluation of the blood flow, velocity and vessel resistance together with surrounding morphology. It can be used for detecting the course of the facial artery and for detecting hemangioma. So the use of ultrasound imaging is unlimited, so proper application of this imaging can be of use in detecting various normal & pathological lesions in the maxillofacial region. Non enhanced MRI with ultrasound imaging /color Doppler can be substituted for enhanced MRI to provide the best diagnostic information and at reduced cost. Ultrasound imaging /color Doppler is an important adjuvant to CT and MRI in the diagnosis of vascular or suspected vascular anomalies and visualization of vessels of the neck including the carotid for atherosclerotic plaques. More recently, development of three-dimensional US imaging allowed multi planar reformatting, volume rendering and Color Power Doppler.¹⁵

2.11 Hemostasis and Vascular Occlusion

Experimental evidence that USG can seal blood vessels and halt flow in vessels has been demonstrated by a number of investigators. The range of intensities used is 400–6500W/cm². Selective occlusion of blood vessels may be useful in the treatment of cancer where it might be useful to cut off feeder vessels to the tumor. The mechanism by which hemostasis is achieved is a combination of disruption, release of coagulation induction factors and platelet activation.¹⁶

2.12 US In Endodontics & Implantology

Ultrasound imaging is now used in endodontics for improving root canal access (e.g. removal of pulp stones); irrigating root canals; removal of posts, broken instruments and other obstructions from the root canal; distribution of sealer around the root canal walls; condensing gutta-percha root fillings; periapical surgery; enhancing dentine permeability during bleaching. Root canal treatment aims to clean, shape and fill the entire root canal of a tooth. The design of the ultrasonic endodontic device is special made for treating the root canal by cleaning; introducing the medication through an irrigation instrument through ultrasonically vibrated endodontic files. For root canal treatment to be effective, all the canals within the tooth must be cleaned with an antiseptic solution, which helps to treat the source of the infection. The basic aim of the root canal is to clean the root and eliminate tissue debris and microorganisms with an ultrasonic endodontic apparatus. Ultrasonic endodontic device works

by converting electromagnetic energy to mechanical energy. A stack of magnetostrictive metal strips in a handpiece is subjected to a standing and alternating magnetic field, as a result of which vibrations are produced.

During passive ultrasonic irrigation, a small ultrasonically oscillating file or smooth wire is placed in the centre of the root canal, following canal shaping, to transmit the energy of the file as efficiently as possible to the irrigant. As a result, acoustic micro-streaming and/or cavitation can occur. Passive ultrasonic irrigation with sodium hypochlorite (NaOCl) as irrigant, removes more dentine debris, planktonic bacteria and pulp tissue from the root canal than manual syringe irrigation. NaOCl is very effective in combination with passive ultrasonic irrigation and more effective than water. Ultrasonic activation canals enhance the antibacterial and organic tissue dissolving potential of NaOCl through temperature increment.

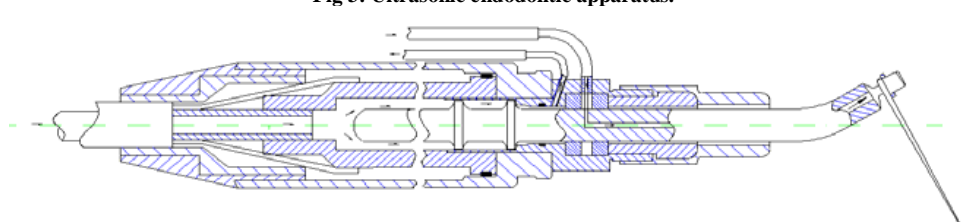
Ultrasonically activated spreaders have been used to thermoplasticize gutta-percha in a warm lateral condensation technique. Initial placement of a gutta-percha cone to the working length is followed by lateral condensation of two or three accessory cones using a finger spreader. The ultrasonic spreader is then placed into the center of the gutta-percha mass 1 mm short of the working length and activated at intermediate power.¹⁷

2.13 Operating Mode of the Ultrasonic Endodontic Device

An ultrasonic endodontic dental handpiece has an elongated housing supporting a coil connected for establishing an alternating magnetic field, the housing having a cooling fluid inlet at one end and being open at the other for receiving and supporting a removable insert. The insert includes an elongated hollow body having one end adapted to be insertably mounted in the open end of the housing in fluid communication with the interior of the handpiece, and an elongated tool support assembly telescoping received in the body.

The tool support assembly includes an elongated shaft member having a vibrator rigidly mounted on one end in position to be vibrated by the electromagnetic field and a seal located between the body and shank outboard of the housing to prevent the flow of cooling liquid through the body past the seal. A cooling fluid outlet is provided in the body between the housing in the seal to permit cooling fluid to flow through the handpiece, and an irrigation fluid passage is provided in the shaft outboard of the housing to permit the flow of irrigation fluid along the shaft to the terminal end of the insert assembly. A mounting head on the end of the shaft supports an endodontic instrument to be vibrated by the vibrator, with the head including a fluid flow passage for discharging irrigation fluid longitudinally of the endodontic instrument.

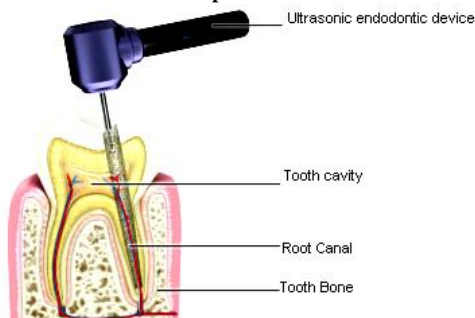
Fig 3: Ultrasonic endodontic apparatus.



Courtesy: Ultrasonic treatment endodontice. *Fiability & Durability*. 2010 2(6):58-66

In endodontics, Color power doppler is used in the evaluation of periapical lesions and follow up of periapical bone healing and for differentiation between vital and root filled teeth. US imaging of teeth revealed promising results for early caries detection and for the evaluation of the periodontal pocket depth and to determine gingival thickness for implantology.¹⁸

Fig 4: Root canal treatment performed with ultrasonic endodontic device.



Courtesy: Ultrasonic treatment endodontice. *Fiability & Durability*. 2010 2(6):58-66

2.14 US in Oral Submucous Fibrosis (OSMF)

It demonstrates the number, length, thickness of the fibrotic bands and pattern of overall vascularity in the affected area. Vascularity of mucosa overlying the bands was found to be decreased with reduced flow velocity and in between bands the flow was found to be normal. OSMF showed increased hyperechoic areas representing fibrous bands or diffuse fibrosis with normal/decreased vascularity and peak systolic velocity. US demonstration of fibrosis and vascularity status during & post treatment period helps to monitor the efficacy of the treatment instituted. Patients with poor vascularity in the affected area and poor response to treatment imply that the treatment schedule should be altered. US monitoring during treatment helps to alter and assess the efficacy of treatment schedule instituted. It is a valuable, radiation free and non-invasive diagnostic tool for the evaluation of OSMF. In some OSMF cases, it evaluates feeble fibrotic bands in clinically appearing normal buccal mucosa. US helps monitoring the progress or otherwise of the lesion. It helps in alteration of the treatment schedule in selected cases & allows for post treatment follow-ups and assessment. It provides a more accurate evaluation of fibrous bands and vascularity in OSMF cases. So, it could be a better diagnostic tool compared to clinical and histopathological examination. Li *et al* used ultrasonography for monitoring localized scleroderma. US detected several abnormalities in active lesions including decreased blood flow, increased echogenicity and loss of subcutaneous fat and reduction in lesion size during treatment.¹⁹ Hesselstrand *et al* used high frequency ultrasonography for assessment of systemic sclerosis.²⁰

2.15 US in Odontogenic Cysts of Maxillofacial Region

US can also be used for diagnosis of many other cysts in the head and neck regions both hard and soft tissue cyst extending to hard tissues or soft tissues or vice versa. It can provide accurate information on the pathological nature of the lesion, content of lesion, inflammatory process, and capsular thickness of lesions. It can also differentiate between simple and complex cyst, and on nature of the content differentiate into solid and semisolid cysts.

- Simple cysts appear totally anechoic lesions with limited or without internal echoes, e.g. radicular cyst.
- Complex cysts appear with dense internal echoes or high echo, e.g. OKC.

- Semisolid cysts when cystic and solid areas are combined in the same lesions.
- Solid lesions have no liquid components and posterior enhancement and have a moderate echo.

By using color and power Doppler ultrasound imaging allows to detected blood flow with in or around the lesion.²¹

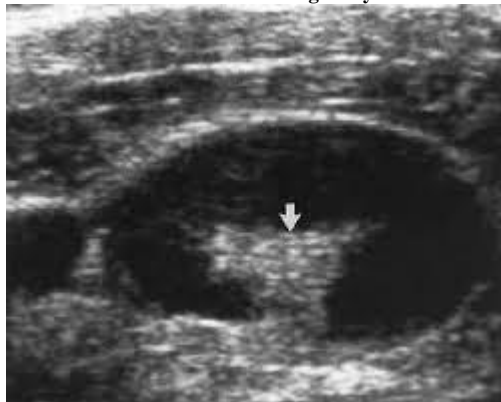2.16 US to Evaluate and Assess the Tumor Thickness and Metastasis

Malignant tumors of deep head and neck structures can invade skin, but the tumor periphery is difficult to assess clinically. High-resolution diagnostic ultrasound imaging demonstrated the periphery of the tumor. The tumor can be distinguished from surrounding edema by its lower echogenicity and homogeneous echo texture, the maximum contour of the tumor can be marked with ink under ultrasound imaging guidance which aids in excision and reconstruction planning.²²

2.17 US in Neck and Cervical Lymph Nodes

High-resolution sonography has become a first line imaging modality for the evaluation of cervical space-occupying lesions including lymph nodes. The thyroid gland, parathyroid gland and the major blood vessel tumors of the neck can be easily assessed. The high resolution US images currently available can detect neck nodes, reveal changes in the architecture of cervical lymph nodes, and assess their characteristics and the degree of vascular invasion.

Fig 5: Benign Lymph Node. This enlarged cervical lymph node is markedly hypochoic. Fat infiltrating the node from the hilum (arrow) is indicative of benignancy.



Core Curriculum, The: Ultrasound imaging 1st Edition. 2001 Lippincott Williams & Wilkins

CT and MRI are based on the size criteria to detect malignant nodes but USG can detect shape, echogenic pattern, peripheral vascularity and calcification of lymph nodes which is important to differentiate malignant nodes from benign nodes. The detection of nodes in the submental and submandibular regions is found to be superior with US whereas CT and MRI studies have occasionally been impaired by artefacts from bones and dental amalgam restorations. Being less invasive than CT, US is particularly indicated for follow-up studies aimed at assessing the efficacy of chemotherapy or radiotherapy.²³

2.18 US in Soft Tissue Infections

It is a valuable diagnostic as well as therapeutic help in the management of superficial fascial space infections. Sometimes clinical diagnosis alone is difficult to differentiate between cellulitis and abscess; in such cases US provides accurate imaging of the superficial structures of head and neck region, delimited medially by a bony skeleton. Compared to clinical examination, ultrasound imaging is much superior in defining the exact location of abscess because of its real-time processing. US guided needle aspiration is a safe and effective procedure & appeared to be a reliable alternative to surgical incision and drainage in few cases.²⁴

With proper case selection, traditional open surgical incision and drainage can be avoided. B-scan sonography is an inexpensive and noninvasive diagnostic technique with relative high sensitivity and specificity that should be used to supplement clinical examination in patients with inflammatory soft tissue swellings of many regions in head and neck. It can be used to help locate abscess cavities and thereby give hints for the surgical approach. It can be used to follow the course of the disease and its response to the nonsurgical treatment. Though USG cannot differentiate an abscess from surrounding blood vessels, but combination of colour doppler ultrasonography with grey scale has solved this problem. The target of colour doppler imaging is the moving blood cells within the blood vessel. The vessels of the inflammatory tissue which has a higher blood volume due to increased permeability of the vessel wall are depicted as a colour flow signal. Blood flowing towards the US transducer is displayed as red and that moving away from transducer as blue.²⁵ In contrast the retained pus which does not contain flowing blood cells is delineated as no colour flow signal.

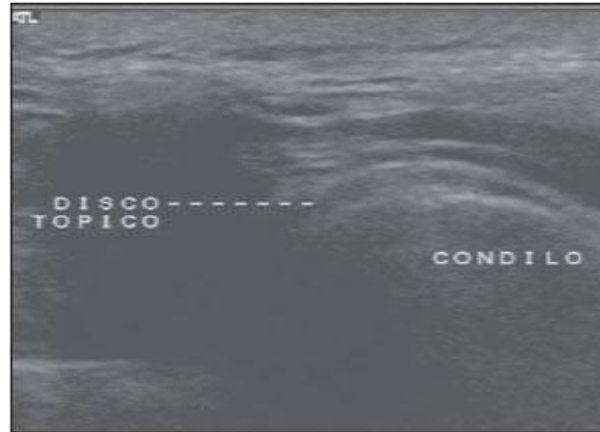
This property of doppler ultrasonography allows it to differentiate blood vessels from static regions of images. Radiographs and other imaging studies can be used to diagnose the spreading infections in the head and neck area but plain radiographs do not often provide a good definition of soft tissues. CT and MRI are effective in diagnosing inflammatory conditions and choice between these two techniques usually depends on the area involved. However, both techniques are expensive. CT exposes the patient to large doses of radiation especially if repeated follow-up examinations are to be performed. Artefact produced by bone and metal degrade images around the face. Another significant disadvantage is the poor contrast between the various soft tissues.

The major disadvantage of MRI is the prolonged time for image acquisition, and also the image may suffer from the effects of the patient motion. The high static magnetic field also poses a danger to those individuals with cardiac pacemakers, neurostimulator units and intraocular therapeutic devices. For many years, USG has played a major role as a diagnostic tool in various medical conditions. In maxillofacial surgery, it is relatively a new diagnostic aid.²⁶

2.19 US in Tmj Disorders

It could be a useful first level diagnostic instrument in the study of TMJ disc displacement. This is mostly valid while considering the value of US for the study of TMJ effusion. US have proved to be accurate in the detection of joints with effusion and to study clinically painful joints. Therefore, its potential advantages over MRI could be extended to the study of effusion and its complex relationship with articular pain. US at high intensities caused thermal damage in bone and lower intensity doses lead to new periosteal bone formation. The therapeutic efficacy of US alone in the temporomandibular disorders is lacking and it is always used in the combination of electrical stimulation. The therapeutic effect of US is reported to be due to its thermal properties.²⁷

Fig 6: The articular disc presents intermediate and homogeneous echogenicity at US, allowing the visualization of the posterior 2/3 of the disc with the patient at rest.



Courtesy: Mello Jr CF, Saito OC, Guimarães Filho HA. Sonographic evaluation of temporomandibular joint internal disorders. *Radiol Bras.* 2011; 44(6):355–359.

2.20 US in Healing

The effects of ultrasound imaging on bone tissue repair are caused by a multiple mechanisms. Physical effects are due to the vibrations generated in all tissue components, including intracellular and extracellular fluids and cell membranes, which produce a micro massage effect in tissues, causing mechanical stimulation. It has also been shown that US application increases synthesis of angiogenesis related cytokines such as interleukin, fibroblast growth factor, and vascular endothelial growth factor. The rate of angiogenesis is one of the basic elements in the bone healing process. In soft tissue wound healing thermal US has been used in the late stages (remodeling phase) to improve scar and wound outcome.²⁸

2.21 US for Treatment of Microbial Disease

The science of photodynamic antimicrobial chemotherapy utilizes photo sensitizers and light of appropriate wavelength to produce highly reactive free radical species, which then destroy the microbial pathogens. It has been shown to be ineffective against some microbial because of the limited tissue penetration of visible light.

Recently, some photo sensitizers have been discovered which produce free radicals on irradiation with US. These photo sensitizers are termed sonosensitizers. Focused US can penetrate into tissue more deeply than light and can be focused into a small region to activate sonosensitizers, which was termed sonodynamic therapy whose mechanism is similar to photodynamic therapy which has promising antimicrobial strategy against bacteria, yeasts, viruses and parasites. While in the cases of abscess, the edges were well defined with the homogenous pattern and hypoechoic intensity, with posterior acoustic enhancement suggestive of some collection.²⁹

2.22 US for Treatment of Recurrent Aphthous Stomatitis

The use of low intensity US in the form of an ultrasonic tooth brush has been shown to provide a therapeutic benefit in a number of clinical settings, primarily by accelerating the wound healing using low intensity. US avoids excessive tissue heating and the physiologic responses noted in tissue exposed to these ultrasonic waves are the result of non-thermal effects. One such response is a change in cellular membrane permeability. Other effects include stimulation of fibroblasts and macrophages, increased angiogenesis, promotion of granulation tissue formation, and alteration of oral microflora. It was demonstrated the use of ultrasonic tooth brush twice daily decreased the number of lesions existing as well as decreased the number of lesions that develop.³⁰

2.23 US & Periodontium

In 2010, researchers from West Virginia University and Cairo University investigated the feasibility of using a custom-designed ultrasound imaging system to reconstruct 3D surface images of periodontal defects.

Using this system, they were able to identify and describe in 3D all anatomical landmarks while 2D radiographic images yielded poor contrast. There is great potential for using high-resolution ultrasound imaging as a noninvasive, nonionizing imaging technique for the early diagnosis of the more severe form of periodontal disease. And a literature review in *The Journal of Periodontology* found that ultrasound imaging is fast, noninvasive, and is able to visualize periodontal and oral tissues *in vivo* or *ex vivo* without the need for complicated processing, fixing, or staining. Another example of ultrasound imaging use is dental professionals using it to clean both teeth and dental tools.³¹

Ultrasonic dental sealers are used to remove the hardened plaque and calculus from the tooth surface. They operate by direct contact of an ultrasonically activated probe tip to the tooth surface. As the probe tip vibrates, it mechanically dislodges plaque from the tooth surface. Also, when subjected to the mechanical action of the tip, fluid delivered by the sealer "cavitates". It seemed plausible to the authors that ultrasound imaging also could be used to aid in the removal of dental plaque bacteria as part of a regular oral hygiene regimen. Normal brushing of the tooth surface using a toothbrush and dentifrice produces quiescent bubbles within those bubbles, producing additional cleaning. To do so effectively in the oral cavity required the second idea: create an ultrasound imaging waveguide to efficiently channel the ultrasound imaging from the transducer to the bubbles within the fluid at and near the bristle tips. To demonstrate its merit, basic laboratory testing was performed at the University of Washington, Seattle, using methods available from the scientific literature.

The goal of this early work was to show that sonic bristle motion and ultrasound imaging provided a synergistic cleaning effect on plaque bacteria. Single-species biofilm, similar to that used to test other power toothbrushes, was used to model dental plaque. These experiments supported the theory that the combination of sonic brush head motion and ultrasound imaging could synergistically remove biofilm.³²

2.24 Ultrasound Imaging in Sterilization

Ultrasound imaging waves are routinely used to clean surfaces (eg, integrated circuits and surgical tools) and achieve therapeutic benefits (eg, gene therapy). In many of those applications, ultrasound imaging creates its enhanced cleaning or therapeutic effects from its interaction with bubbles. Bubbles (microspheres of air stabilized by a thin film on their exterior), when subjected to the rhythmic pulsations of pressure created by ultrasound imaging waves, expand and contract, generating local fluid motion around the bubble called acoustic microstreaming. This acoustic microstreaming can generate sufficient shear on the surrounding surfaces or tissue to mechanically alter those surfaces, achieving the desired effect. Another example of ultrasound imaging use is dental professionals using it to clean both teeth and dental tools. Ultrasonic dental sealers are used to remove the hardened plaque and calculus from the tooth surface. They operate by direct contact of an

ultrasonically activated probe tip to the tooth surface. As the probe tip vibrates, it mechanically dislodges plaque from the tooth surface. Also, when subjected to the mechanical action of the tip, fluid delivered by the sealer "cavitates" (produces and/or stimulates bubbles, which are, in turn, activated by the ultrasound imaging to assist in cleaning). Also, ultrasound imaging water baths are used to decontaminate dental tools. Ultrasound imaging transducers surrounding the tank of these baths channel ultrasound imaging waves into the fluid surrounding the dental tools.

The waves within the fluid generate or activate minute bubbles within the fluid and on the surface of the tools. This activation causes the bubbles to pulsate, creating acoustic microstreaming capable of cleaning surfaces.³³

2.25 US in Detection of Foreign Bodies

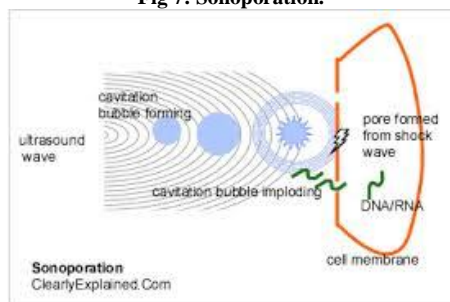
Foreign bodies in maxillofacial region are frequently encountered in RTA, missile injuries, interpersonal assaults or by accidental self fall. These are mostly radio opaque, e.g., bullets, metal fragments, broken needles, etc., and they can be easily diagnosed with plain radiograph and CT. Radiolucent foreign body like wood, wood splinters, bamboo twig, thorn, fish bone etc., pose a diagnostic challenge. Ultrasound imaging is an excellent diagnostic aid in diagnosing and locating wooden foreign body. Wood is a highly echogenic material. A high frequency linear transducer ultrasound imaging from 7.5MHZ can detect even smallest wooden foreign body of 3mm and the specificity is 95%. Wood is seen as hyperechoic foci with accompanying acoustic shadows.³⁴

The shadows may be complete or incomplete due to the angulations of insonation or the composition of the foreign body. The hypoechoic halo is sometimes due to the presence of abscess, edema or granulation tissue. It not only aids in diagnosis, its intra operative use is highly recommended for the localization of the encapsulated wooden foreign body too. Ultrasound imaging when used intra operatively prevents time consuming tedious explorations and reduces morbidity of the surgical site. Every physician in emergency medicine is trained to perform ultrasound imaging on all punctured wounds. This is based on focused assessment of the sonographic examination for trauma patients for emergency physicians. This should be incorporated for head and neck wounds also.³⁵

2.26 Sonoporation

Sonoporation or cellular sonication, is the use of US for modifying the permeability of the cell plasma membrane. This technique is performed with a commercially available sonoprotator. It is used in the delivery of therapeutic agents including genetic material, proteins, and chemotherapeutic agents into the cell, in a cell disruption process called transfection or transformation. It employs the acoustic cavitations of micro bubbles to enhance delivery of these large molecules. This technique is similar to, and in some cases found superior to, electroporation. Thus, sonoporation is a promising drug delivery and gene therapy technique, which unlike other methods of transfection or chemotherapy, combines the capability of enhancing gene and drug transfer with the possibility of restricting this effect to the desired area and the desired time.³⁶

Fig 7: Sonoporation.



Courtesy: Douglas L. Miller. *Somatic Cell and Molecular Genetics*. 2002; 27 (1-6): 115-134

3. Conclusion

Ultrasonography is an innovative and evolving imaging technology with plenty of research continuing to be done in medical & dental field. As a diagnostic tool ultrasonography imaging stands as a non-invasive, cost effective, readily available and repeatable technique. It is relatively easy to use. The additional use of color and power Doppler ultrasound imaging allows to detected blood flow with in or around the lesion. There has been a great deal of interest in the imaging of salivary gland, floor of mouth, tongue and palatal tumors, metastasis, for assessment of lymph nodal involvement, tumor thickness and in differentiating benign and malignant lesion for some extent, in an attempt to make a diagnosis before biopsy as the surgical management of these tumors may vary. Further studies should be directed towards clinical applications of the system in the dentomaxillofacial region.

References

1. Senthil KB, Nazargi MM. Ultrasound imaging in dentistry- a review. *JIADS* 2010; 1:44-45.
2. Cotti E. Advanced techniques for detecting lesions in bone. *Dent Clin North Am*.2010; 54: 215-235.
3. Yoon MJ, Kim E, Lee SJ, Bae YM, Kim S, et al. Pulpal blood flow measurement with ultrasound imaging doppler imaging. *J Endod*. 2010; 36: 419-422.
4. Boruah LC, Bhuyan AC. Ultrasonography and color doppler as a diagnostic aid in differentiation of periapical lesions of endodontic origin: report of two cases. *World J of Dentistry*. 2010; 1: 117-119.
5. Jonas JT. A surgeon looks at cervical lymph nodes. *Radiology*. 1990; 175:607-10.
6. Ghorayeb SR, Bertoncini CA, Hinders MK. Ultrasonography in dentistry. *IEEE Trans Ultrason Ferroelectr Freq Control* 2008.55: 1256-1266.
7. McKenna J., Pabbies A., Friesen J. R., Sowa M. G., Hayakawa T., and Kerr P. D. Assessing flap perfusion: optical spectroscopy versus venous Doppler ultrasonography. *Journal of Otolaryngology*. 2009. 38(5): 587-594.
8. Akizuki H, Yoshida H, Michi K. Ultrasonographic evaluation during reduction of zygomatic arch fractures. *J Craniomaxillofac Surg*. 1990; 18(6):263-6.
9. Coatney RW. Ultrasound imaging Imaging: Principles and Applications in Rodent Research. *ILAR J*. 2001; 42: 233-247.
10. Eger T, Muller HP, Heinecke A. Ultrasonic determination of gingival thickness. Subject variation and influence of tooth type and clinical features. *J Clin Periodontol*. 1996; 23: 839-845.
11. Arijji Y., Kimura Y., Hayashi N. Power Doppler sonography of cervical lymph nodes in patients with head and neck cancer. *American Journal of Neuroradiology*. 1998.19 (2): 303-307.
12. Wu-Yuan GD, Anderson RD, McInnes C. Ability of the Soni care electronic toothbrush to generate dynamic fluid activity that removes bacteria. *J Clin Dem*. 1994; 5:89-93.
13. Mesiwala AH, Tarrell L, Wenzel HJ, et al. High-intensity focused Ultrasound imaging selectively disrupts the blood-brain barrier *in vivo*. *Ultrasound imaging Med Biol*. 2002; 28:389-400.

14. Hansen JE, Gudeman SK, Holgate RC, Saunders RA. Penetrating intracranial wood wounds: clinical limitations of computed tomography. *J Neurosurg* 1988; 68:752-756.
15. McKenna J., Pabbies A., Friesen J. R., Sowa M. G., Hayakawa T., and Kerr P. D.. Assessing flap perfusion: optical spectroscopy versus venous Doppler ultrasonography. *Journal of Otolaryngology*. 2009. 38(5): 587–594.
16. Ying M, Ahuja A, Brook F. Accuracy of sonographic vascular features in differentiating different causes of cervical lymphadenopathy. *Ultrasound imaging Med Bio* 2004; 30:441-7.
17. Tikku AP, Kumar S, Loomba K, Chandra A, Verma P. Use of ultrasound imaging, color doppler imaging and radiography to monitor periapical healing after endodontic surgery. *J Oral Sci*. 2010; 52: 411-416.
18. Ahmad M, Pitt Ford TR, Crum LA. Ultrasonic debridement of root canals: acoustic streaming and its possible role. *J Endod* 1987; 1:490-499.
19. Knappe M, Louw M, Gregor RT. Ultrasonography –guided fine –needle aspiration for the assessment of cervical metastases. *Arch Otolaryngol Head Neck Surg* 2000; 126:1091-6.
20. Anand N, Chaudhary N. Comparison of the efficacy of clinical examination, ultrasound imaging neck and computed tomography in detection and staging of cervical lymph node metastasis in head and neck cancers. *Indian J Otolaryngol Head Neck Surg*. 2007; 59:19-23.
21. Som PM. Lymph Nodes of the Neck. *Radiology* 1987; 165:593-600.
22. Ewh TO, Tsang WM, Cheng J, Lai E, Pang P, Ahuja AT, et al. Is neck ultrasound imaging necessary for early stage oral tongue carcinoma with clinically N0 neck? *Dentomaxillofac Radiol* 2003; 32:156-9.
23. Ahuja A, Ying M, Yang WT, Evans R, King W, Metreweli C. The use of sonography in differentiating cervical lymphomatous lymph nodes from cervical metastatic Lymph Nodes. *Clin Radiol* 1996; 51:186-90.
24. Szmaja Z, Wierzbicka M, Kordylewska M. The value of ultrasound imaging examination in preoperative neck assessment and in early diagnosis of nodal recurrences in the follow-up of patients operated for laryngeal cancer. *Eur Arch Otorhinolaryngol* 1999; 256:415-7.
25. Atula TS, Varpula MJ, Kurki TJ, Klemi PJ, Grénman R. Assessment of cervical lymph node status in head and neck cancer patients: palpation, computed tomography and low field magnetic resonance imaging compared with ultrasound imaging -guided fine-needle aspiration cytology. *Eur J Radiol* 1997; 25:152-61.
26. Haberal I, Celik H, Göçmen H, Akmansu H, Yörük M, Ozeri C. Which is important in the evaluation of metastatic Lymph Nodes in Head and Neck cancer: Palpation, Ultrasonography, or computed tomography. *Otolaryngol Head Neck Surg* 2004; 130:197-201.
27. Esen G. Ultrasound imaging of Superficial Lymph Nodes. *Eur J Radiol* 2006; 58:345-59.
28. Navarro M. Imaging of benign pediatric soft tissue tumors. *Seminars in Musculoskeletal Radiology*. 2009; 13 (3): 196–209.
29. Liu F.-H., Hsueh C., Chao T.-C. and Lin J.-D.. Neck nodule and thyroid cancer in young without radiation exposure history. *Pediatric Surgery International*, 2009; 25(9): 785–788.
30. Mashkevich G., Wang J., Rawnsley J., and Keller G. S. The utility of ultrasound imaging in the evaluation of submental fullness in aging necks. *Archives of Facial Plastic Surgery*. 2009.11 (4): 240–245.
31. Adams H, Winston MT, Heersink J, et al. Development of a laboratory model to assess the removal of biofilm from interproximal spaces by powered tooth bombing. *Am j Dent*. 2002; 15:12B-17B.
32. Heersink J, Costenon W), Stoodley P Influence of the Sonicare toothbrush on the structure and thickness of laboratory grown *Streptococcus mutans* biofilms. *Am j Dent*. 2003:16:79-83.
33. Morimoto Y., Tanaka T., Yoshioka I. New diagnostic imaging modalities for oral cancers (Chapter 5). in *Oral Cancer Research Advances*, pp. 125–153, Nova Science, Hauppauge, NY, USA, 2007.
34. Oikarinen KS, Nieminen TM, Makarainen H, Pyhtinen J. Visibility of foreign bodies in soft tissue in plain radiographs, computed tomography, magnetic resonance imaging, and ultrasound imaging. An in vitro study. *Int J Oral Maxillofac Surg*.1993; 22: 119–124.
35. Shres Haa D, Sharma UK, Mohamed R, Dhoju D. The role of ultrasonography in detection and localisation of radiolucent foreign body in soft tissues of extremities. *J Nepal Med Assoc*. 2009; 48 (173):5-9.
36. Ahuja A, Ying M. Sonography of neck Lymph Nodes, Part II: abnormal lymph Nodes. *Clin Radiol*. 2003; 58:359-66.