

Research Article

Histopathological study of hepatobiliary malignancies and its correlation with clinical features

Ragini Thapa* and K. Pushpalatha Pai

Department of Pathology, Yenepoya Medical College, Yenepoya University, Deralakatte, Mangalore, India

***Correspondence Info:**

Dr. Ragini Thapa,
Room no.205, Gardeynia PG hostel
Yenepoya Medical College, Lakshmigudde
Deralakatte, Mangalore -575018, Karnataka.
E-mail: ragpiyu2010@yahoo.com

Abstract

Objectives: The aim of the study is to analyze hepatobiliary malignant tumors histologically, histochemically, immunohistochemically wherever possible and compare with the clinical features and review the literature.

Methods: It is a retrospective clinicopathologic study using routine and special histopathological methods with information from clinical records

Results: The age of the patients ranged from 32 to 72 years with male predominance. There were 5 cases of metastatic tumours and 2 cases of primary tumours of liver without cirrhosis both being hepatocellular carcinomas (HCC) where one was fibrolamellar type with amyloid deposition. There were 4 cases of primary and one case of secondaries in the gall bladder with majority associated with cholelithiasis. Extrahepatic biliary system had one case of adenocarcinoma.

Conclusions: The liver is the most common site of malignancy of hepatobiliary system where secondaries are dominating followed by gall bladder with the primary being most common. Fibrolamellar type of hepatocellular carcinoma is not uncommon but amyloid in the tumor tissue has not been reported in the literature. Least common site of hepatobiliary system cancer is extra hepatic bile duct.

Keywords: Carcinoma, hepatobiliary system

1. Introduction

Hepatobiliary malignancies comprise a diverse group of tumors including hepatocellular carcinoma, variants such as fibrolamellar HCC and cholangiocellular carcinoma, carcinoma of the gallbladder, carcinoma of extrahepatic bile ducts, cancers such as sarcoma, angiosarcoma, hepatoblastoma and metastatic tumours mainly in the liver. Hepatocellular carcinoma is a malignancy of worldwide significance and has become increasingly important. HCC is the most common primary liver malignancy. Liver cirrhosis is acknowledged as a premalignant condition for developing HCC. Hepatitis B and hepatitis C virus, alcohol use, and nonalcoholic fatty liver disease (NAFLD) are the most common causes of cirrhosis. Gallbladder cancer is a relatively uncommon cancer thought to be related to gall stones and more common in women in 6th and 7th decade. Extrahepatic bile duct cancer is very rare. Here we are reporting study on 13 cases of hepatobiliary malignancies.

2. Materials and Methods

13 cases of hepatobiliary carcinomas were studied over a period from June 2012 to December 2013 using routine histopathological, histochemical and immunohistochemical methods wherever indicated and possible. Paraffin blocks and haematoxylin and eosin stained slides from archives were reviewed for histopathological examination. Clinical details with results of imaging studies were collected and results were correlated with the pathological findings. Histochemistry and immunohistochemistry were performed as per the manufacturer's protocol (Novocastra™ ready to use mouse monoclonal antibody) in cases where they were necessary.

3. Results

Liver was found to be the most common site of malignancy in hepatobiliary system (7 cases-53.8%). Out of 7 patients 5(71.4%) were males. Rest 2 (28.5%) were females. The age ranged from 41 years to 59 years for liver carcinomas (Table 1). Most of the patients (2/ 4 cases of secondaries were from malignant gastric Gastrointestinal tumours (2 cases - 40%, CD 117 positive) (figure 1, 2, 3, 4), as shown in Table-1.

Figure (1, 2) - 2480/12 secondaries from malignant GIST (Gastrointestinal stromal tumour) of stomach. Central hepatectomy



Figure (3)-Gist secondaries in liver H&E 2480/12.

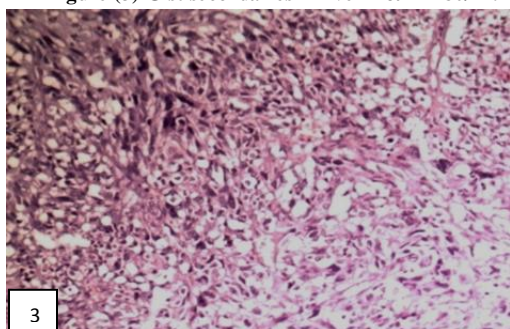


Figure (4) - CD117 POSITIVITY

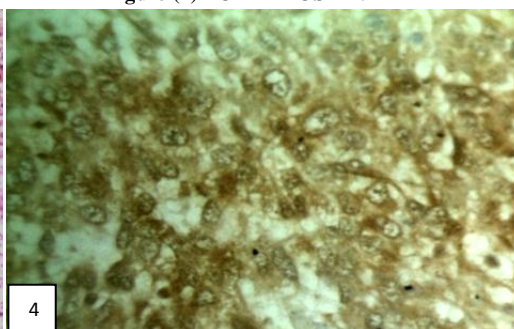
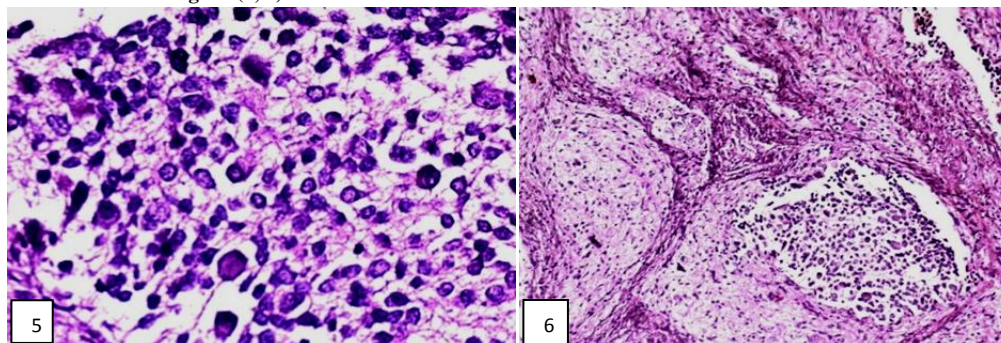


Table 1-Neoplasms of Liver with clinical presentation

HPNO	Age	Sex	Site of Tumour	Common Clinical Presentation
4480/12	45	F	Secodaries from known case of gastric gist ,CD117 positive tumour cells	History of jaundice and weight loss raised SGOT/SGPT, increased bilirubin.
1355/12	50	F	Secondaries from carcinoma gastro esophageal junction.	History of weight loss, anorexia, upper abdominal pain
2765/09	53	M	Secondaries from gastric Gist, CD 117 positive	Presented with mass per abdomen, gradually progressive with history of jaundice and weight loss, raised serum levels of bilirubin, alpha-fetoproteins, SGOT, SGPT and alkaline phosphatase.
2738/09	41	M	Leukemic infiltration	Presented with history of pain in the abdomen, abdominal distension,\nausea , weight loss and hepatosplenomegaly.
1635/10	52	M	HCC-fibrolamellar type with Amyloid in the tumour tissue proved by Congo -red stain with polarizing microscopic examination(positive) also by immunohistochemical stain for kappa and lambda chains	Presented with fever since 3 weeks, increased bilirubin, SGOT and SGPT levels ,I and alkaline phosphatase levels in the serum
3219/07	59	M	HCC	Presented with fever, jaundice, abdominal distension and pain with history of chronic alcohol intake and increased serum levels of bilirubin and SGOT and SGPT
308/07	1 month	M	Secondaries from neuroblastoma. Neuron specific enolase positive tumour cells	A known case of adrenal neuroblastoma

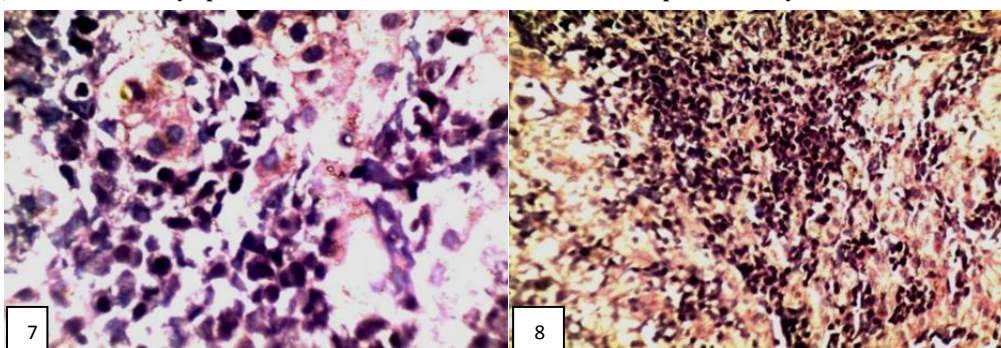
One case (14.2%) was an infant one month old who had adrenal neuroblastoma metastasizing to the liver (figure 5 and 6).

Figure (5, 6) Secondaries in the liver from adrenal neuroblastoma: 308/07



Poorly differentiated adenocarcinoma of gastroesophageal junction and leukemia (20% each) (figure 7, 8). (85%) presented with pain in the abdomen, weight loss and deranged liver function tests. (As shown in Table-1).

Figure (7, 8)-Acute leukaemic/lymphoma infiltration of liver-2738/09. Infiltration of portal triad by monotonous leukaemic blast cells.



Both cases of HCC occurred in 52 and 59 year old males without cirrhosis. Out of two cases of HCC, one was fibrolamellar type with amyloid deposits in the tumour stroma proved by histochemistry –Congo red staining with polarizing light microscopic examination. Immunohistochemistry for kappa and lambda light chains was negative (figure -9, 10, 11, 12). Second case of HCC was of moderately differentiated hepatocellular carcinoma.

Figure (9)-Microscopy of fibrolamellar HCC with amyloid deposits-1635/10.Neoplastic oncocyctic hepatocytes with pleomorphic nuclei with prominent nucleoli. Stroma shows homogenous pale pink amyloid

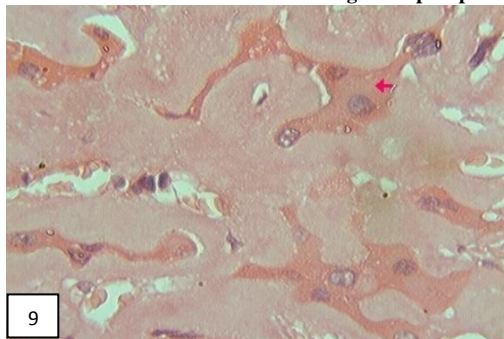


Figure (10, 11)-Fibrolamellar type HCC with Congo red stain with apple green birefringence under polarizing microscope

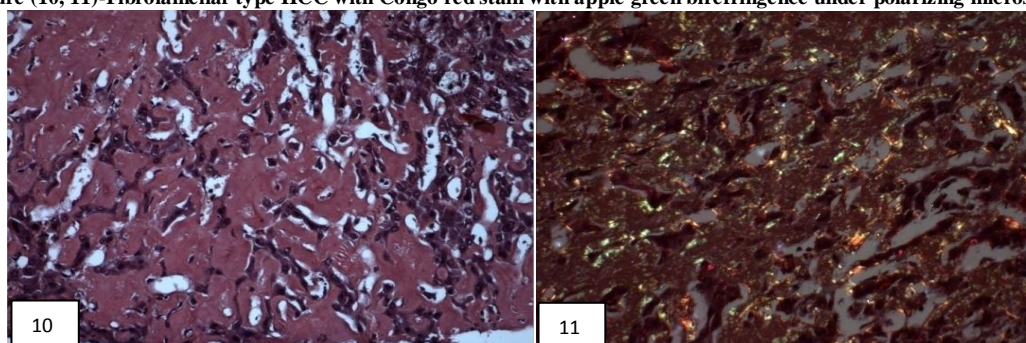
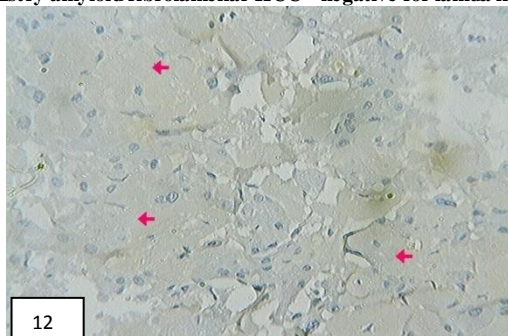


Figure (12)-Immunohistochemistry amyloid fibrolamellar HCC - negative for lamda light chain and kappa light chain



Next common site of hepatobiliary tumor was gall bladder (38.5%) where primary tumor was dominating (4/5-80.0%) and all were well differentiated adenocarcinomas with one case showing papillary pattern (Table 2). Male to female ratio in gall bladder cancer including secondaries was 3:2. One of the cases of gall bladder adenocarcinomas was secondaries in the gall bladder in a calculous cholecystitis where tumor was seen as tumor emboli in the blood vessels (figure-13, 14). Age range of primary carcinoma of gall bladder was 51 to 72 years with male to female ratio 3:1.Two cases had presented with chronic cholecystitis with cholelithiasis. All cases had increase in serum bilirubin and aminotransferases (AST and ALT) levels.

Table 2: Neoplasms of Gall Bladder

NO.	HPNO.	Age	Clinical Features	Histopathological Type of Tumour
1	243/ 10	51y/M	Presented with features of acute cholecystitis. Cholecystectomy specimen	Moderately to poorly differentiated adenocarcinoma gall bladder
2	89/ 09	72y/M	Known case of calculous chronic Cholecystitis cholecystectomy specimen	Calculous chronic cholecystitis with moderately differentiated adenocarcinoma of gall bladder
3	3504 /08	53y/F	Known case of calculous cholecystitis .cholecystectomy specimen	Calculous chronic cholecystitis with papillary adenocarcinoma gall bladder
4	2219/11	45y/F	A known case of calculous cholecystitis. cholecystectomy specimen	calculous chronic cholecystitis with adenocarcinomatous emboli in the blood vessels –secondaries in the gall bladder.
5	2905/06	64y/M	1)gall bladder2) hemicolecotomy Presented with pain in the right hypochondrium, weight loss and anorexia	Papillary adenocarcinoma of the gall bladder with secondary deposits in caecum, colon, ileum and mesenteric lymph nodes. Gall bladder was acalculous

Figure-13- Secondaries in the gall bladder showing adenocarcinoma thrombi in the blood vessels in the serosa.

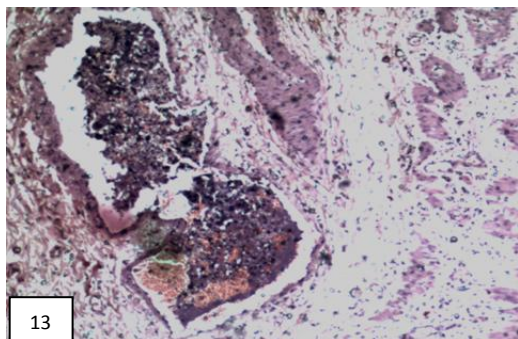
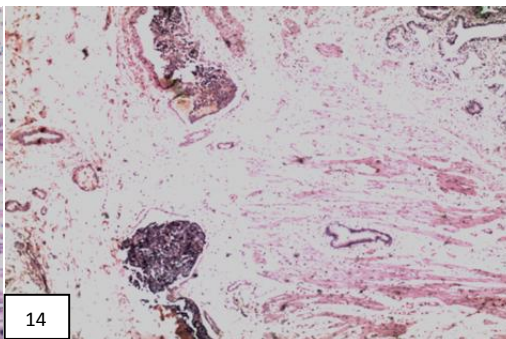


Figure 14-Low power view of figure 13 with muscle layer showing Rokitansky Aschoff sinuses in the muscle layer



There was one case of adenocarcinoma arising from common hepatic duct (Klatskin tumour) (Table 3) which is the least common site of cancer in this series (7.6%) which occurred in a young, 32 years old female. This patient presented with history of pain and fever with obstructive jaundice.

Table 3: Neoplasms of Common Hepatic Duct:

No.	HPNO	Age, Sex	Clinical Features	Histopathological Type of Tumour
1	1812 / 10	32 y/ f	Tumor at confluence of left and right hepatic ducts presented with fever and pain in abdomen since 2 months. She had raised levels of serum bilirubin, SGPT, SGOT, alkaline phosphatase and alpha-fetoproteins.	Klatskin tumor showing moderately differentiated adenocarcinoma with desmoplastic stroma.

4. Discussion

The liver, gallbladder, bile ducts, and pancreas have a common embryologic origin. Cancers that arise from these sites share a similar spectrum of histologic types.¹ On the whole males are affected more than females in the ratio 8:5. In all four sites, greater than 95% are carcinomas.² Primary cancers of the liver are uncommon in United States but are common in other parts of the world, especially in Africa and southeast Asia.³ In the present study of total 13 cases of hepatobiliary malignancies 53.8% were those of liver with metastases constituting (71.4%). Cholangiocarcinoma is much less common than HCC compared to other sites of hepatobiliary system as found in our study.

It is increasingly recognized that morphologic subtypes of liver carcinoma exist beyond the obvious broad distinctions of hepatocellular and cholangiocarcinoma. Commonly accepted subtypes are fibrolamellar HCC (FL HCC), scirrhous HCC, sarcomatoid HCC, and the so-called inflammatory HCC.⁴ In our study we have reported one case of fibrolamellar type of HCC with amyloid stroma.

Gallbladder Carcinoma (GBC) is a rare but highly lethal disease. In many patients, the disease is not suspected clinically and is found at an advanced stage, often during surgery for cholelithiasis. The associated survival rates are very low, similar to those seen for pancreatic and lung cancer.^{5, 6, 7} The mean age of patients is 65 years. In the present study most of the patients were males (60%), and had cholelithiasis. Gallbladder carcinomas are associated with gallstones in 80%, porcelain gallbladder 10-20%, and abnormal choledochopancreatic duct junction. Gallbladder carcinoma usually produces asymmetric thickening of the gallbladder wall with infiltration to surrounding structures. As described by Campbell *et al*⁸ most cancers originate in the gallbladder fundus. As the tumour progresses, the gallbladder may fill with tumour or may contain pus, mucus, or stones. Early carcinomas can appear as a mucosal plaque, a polypoid or papillary outgrowth, or discrete thickening of the wall. There are papillary and nodular forms of GBC. Papillary tumours are less likely to invade the liver directly and have lower incidence of lymph-node metastasis.⁹⁻¹² In our study one case (20%) showed papillary pattern of adenocarcinoma. Most carcinomas of the gallbladder are adenocarcinomas (80-95%) as in the present study, and can be papillary, tubular, mucinous, or signet cell type. Less common types of GBC are undifferentiated or anaplastic carcinoma (2-7%), squamous cell carcinoma (1-6%), and adenosquamous carcinoma (1-4%). Clear cell adenocarcinoma of the gallbladder is composed of cords, sheets, nests, and trabeculae of clear cells with well-defined cytoplasmic borders and may be confused histologically with metastatic renal cell carcinoma. In our study 66.6% (2 cases of primaries and one case of secondaries) patients had cholelithiasis. Size of the gallstones may also be a risk factor, as patients with stones larger than 3 cm have a significantly greater risk of developing carcinoma.¹³ Recently, clinical and epidemiological studies have suggested a link between gallstone disease GBC as well as other hepatobiliary diseases and previous infection with *Helicobacter* species.^{14,15}

Cholangiocarcinoma intrahepatic or extrahepatic are less common. They are slightly more common in males, not associated with lithiasis and have poor outcome because of low rate of resectability, and occurrence in older age group. Cancers of the extrahepatic bile ducts are less common than those of the gallbladder. The same major histologic types can be found in both sites, but slight differences are seen in the frequency of certain subtypes. 99% of cases were carcinomas, and the most frequently reported subtype was adenocarcinoma not otherwise specified (NOS). Papillary carcinomas accounted for a higher percentage of carcinomas in the extrahepatic bile ducts than in the gallbladder.^{16,17} In our study we had one case of common hepatic duct adenocarcinoma which was moderately differentiated. Bile duct carcinomas are often small and have not metastasized when detected but patient outcome remains poor. An important factor in the prognosis is the location of the tumor within the biliary tree.¹⁸ Tumors in the lower third of the bile duct can be resected more successfully than those from other location but the majority of tumors are located within the upper third of the bile duct system as in the present study -at the confluence of the hepatic ducts at the hilum as a single mass (MRI). Bile duct tumors can be diffusely infiltrative or multifocal also.¹⁷⁻²²

5. Conclusion

The liver is the most common site of malignancy of hepatobiliary system where secondaries are dominating. Fibrolamellar type of hepatocellular carcinoma which is not uncommon but amyloid in the tumor tissue is not reported in the literature. Primary carcinoma of Gall bladder is more common than secondary in the gall bladder and found to be more common in older age with male predominance. Least common site of hepatobiliary system cancer is extra hepatic bile duct cancer and is seen in younger age. Secondaries can be seen only as tumor emboli in the vessels as in the gall bladder secondaries in the present study which has not been reported in the literature.

References

1. Rosai J. Liver. In: Rosai and Ackerman's Surgical Pathology. 10th ed. Missouri: Elsevier Mosby; 2011.
2. Carriaga MT, Henson DE. Liver, Gallbladder, Extrahepatic Bile Ducts, and Pancreas. *Cancer Supplement* 1995; 75: 171-187.
3. American Cancer Society. Cancer facts and figures. Atlanta, (GA): The American Cancer Society, 1991.
4. Ries LG, Hankey BF, Miller BA, Hartman AM, Edwards BK. Cancer statistics review 1973-1988. Bethesda (MD): National Cancer Institute, 1991.
5. Craig JR, Peters RL, Edmondson HA. Tumors of the liver and extrahepatic bile ducts. In: Atlas of tumor pathology. 2nd series, fascicle 26. Washington (DC): Armed Forces Institute of Pathology, 1989.
6. Mori W, Nagasako K. Cholangiocarcinoma and related lesions. In: Okuda K, Peters RL, editors. Hepatocellular carcinoma. New York: John Wiley and Sons, 197.
7. Theise ND, Curado MP, Franceschi S, Hytioglou P, Kudo M, Park YN, *et al.* Hepatocellular carcinoma. In: Bosman FT, Carneiro F, Hruban RH, Theise ND, eds. WHO Classification of Tumours of the Digestive System. 4th ed. Lyon, France: International Agency for Research on Cancer; 2010:205-21.
8. Fraumeni JF Jr. Cancers of the pancreas and biliary tract: epidemiological considerations. *Cancer Res* 1975; 35:3437-46.
9. Morris DL, Buechley RW, Key CR, Morgan MV. Gallbladder disease and gallbladder cancer among American Indians in tricultural New Mexico. *Cancer* 1978; 42:2472-7.
10. Black WC, Key CR, Carmany TB, Herman D. Carcinoma of the gallbladder in a population of Southwestern American Indians. *Cancer* 1977; 39:1269-79.
11. Campbell WL, Ferris JV, Holbert BL, Thaete FL, Baron RL. Biliary tract carcinoma complicating primary sclerosing cholangitis: evaluation with CT, cholangiography, US, and MR imaging. *Radiology* 1998; 207: 41-50.
12. Joffe N, Antonioli DA. Primary carcinoma of the gallbladder associated with chronic inflammatory bowel disease. *Clin Radiology* 1981; 32:319-324.
13. Vardaman C, Albores SJ. Clear cell carcinomas of the gallbladder and extra hepatic bile ducts. *Am J Surg Pathol* 1995; 19:91-99.
14. Albores SJ, Chable MF, Angeles AD, Schwartz A, Klimstra DS, Henson DE. Early gallbladder carcinoma: a clinicopathologic study of 13 cases of intramucosal carcinoma. *Am J Clin Pathol* 2011; 135(4):637-642.
15. Fukuda K, Kuroki T, Tajima Y. Comparative analysis of Helicobacter DNAs and biliary pathology in patients with and without hepatobiliary cancer. *Carcinogenesis* 2002; 23: 1927-1931.
16. Albores SJ, Henson DE. Tumors of the gallbladder and extrahepatic bile ducts. In: Atlas of tumor pathology. Washington, DC: Armed Forces Institute of Pathology, 1986;2:22.
17. White K, Kraybill WG, Lopez MJ. Primary carcinoma of the gallbladder: TNM staging and prognosis. *J Surg Oncol* 1988; 39:251-254.
18. Henson DE, Albores-Saavedra J, Cork D. Carcinoma of the extrahepatic bile ducts. *Cancer* 1992; 70:1498-50.
19. Chao TC, Greager A. Carcinoma of the extrahepatic bile ducts. *J Surg Oncol* 1991; 46:145-50.
20. Fortner JG, Vitelli CE, Maclean BJ. Proximal extrahepatic bile duct tumors: analysis of a series of 52 consecutive patients treated over a period of 13 years. *Arch Surg* 1989; 124:1275-9.
21. Tsuzuki T, Ueda M, Kuramochi S, Iida S, Takahashi S, Iri H. Carcinoma of the main hepatic duct junction: indications, operative morbidity and mortality, and long-term survival. *Surgery* 1990; 108:495-501.
22. Tompkins RK, Thomas D, Wile A, Longmire WP Jr. Prognostic factors in bile duct carcinoma: analysis of 96 cases. *Ann Surg* 1981; 194:447-457.