

Case Report

Placenta Praevia with placenta accreta: A true maternal near miss

Surekha Tayade^{*}, Naina Kumar and Ritu Singh

Department of Obstetrics and Gynecology, Mahatma Gandhi Institute of Medical Sciences, Sewagram, Wardha, Maharashtra, India

***Correspondence Info:**

Dr. Surekha Tayade
Professor,
Department of Obstetrics and Gynecology,
Mahatma Gandhi Institute of Medical Sciences,
Sewagram, Wardha, Maharashtra, India
E-mail: surekhatayademgims@yahoo.co.in

Abstract

Placenta accreta is an uncommon but a potentially life-threatening obstetric condition that requires a multidisciplinary approach to management. The incidence of placenta accreta has increased and seems to parallel the increasing cesarean delivery rate. We present a case of term pregnancy with placenta praevia and placenta accreta referred to a rural tertiary institute of central India in emergency hours with profuse bleeding per-vaginum. This case report is an example of a true near miss as the patient went into cardiac arrest at the time of caesarean section, but could be revived by sustained effort with timely resuscitation, caesarean hysterectomy and internal iliac artery ligation. It is an example of team effort by Obstetricians and Anesthetists to save a maternal life.

Keywords: Caesarean section, Hysterectomy, Maternal Near miss, Placenta accreta

1. Introduction

Placenta accreta refers to a placenta that is abnormally adherent to the uterus¹. There are three main entities (accreta, increta, and percreta), which are defined by histological degree of placental invasion into the myometrium¹. It is a serious complication of pregnancy that can be life-threatening for both mother and fetus and can be considered as maternal near miss for the woman who survives after bleeding profusely during delivery. Near-miss events are defined as acute obstetric complications during pregnancy, labor or within 6 weeks after termination of pregnancy or delivery that immediately threatens a woman's survival but do not result in her death, either by chance or because of hospital care she receives². Placenta accreta is frequently associated with severe obstetric hemorrhage, usually necessitating hysterectomy if medical therapies have failed. We present a case of placenta praevia with accreta referred with profuse bleeding per vaginum who had massive intrapartum hemorrhage requiring caesarean hysterectomy with bilateral internal iliac artery ligation and multiple blood transfusions. It was a true maternal near miss for the woman as she survived.

2. Case Report

A 30-year-old woman, third gravid with 2 live issues with previous history of one caesarean section was referred to Department of Obstetrics and Gynecology of a rural medical college of central India in emergency hours at 38+4 weeks of gestation with chief complaints of pain in abdomen and bleeding per vaginum since 4-5 hours. She was a diagnosed case of central placenta praevia on ultrasonography. On general examination patient was conscious and oriented, afebrile, however she had moderate degree of pallor. She had tachycardia with pulse 120 beats per minute and a blood pressure of 90/60 mm of Hg. The uterine height was less than the period of gestation, 34 weeks, but flanks were full and the foetus was in transverse lie. There was fetal bradycardia with fetal heart sounds dropping to 90 beats per minute. Mild uterine activity was present. Her underclothes were soaked with blood and she had active fresh per vaginal bleeding. With a diagnosis of third gra vida with placenta praevia, transverse lie, fetal bradycardia and previous cesarean section delivery, initial management was done by setting up of intravenous line with wide bore cannula and blood samples were taken for investigation as well as for cross-matching. Blood bank was intimated and arrangement for adequate blood was made, relatives of patient were counseled about the seriousness of the condition. The patient was shifted immediately to Operation theatre for emergency caesarean section. Under all aseptic precautions the abdomen was opened by transverse incision and uterus by lower segment transverse incision.

Multiple large torturous vessels were present on the anterior surface of uterus. Placenta was anterior covering the os. Baby was extracted out as breech by access through the placenta. Baby cried immediately and cord was clamped and cut. When an attempt was made to remove the placenta there was profuse bleeding from the lower segment as the placenta was firmly adherent to anterior lower segment at the site of previous scar. Large bleeding vessels could be seen and within few minutes of extraction of the baby the patient went into cardiac arrest. The woman was immediately intubated and Cardio-pulmonary resuscitation done by anesthetist, inotropic drugs were started. Blood transfusion was started and further transfusions arranged. Taking into consideration the excessive blood loss and adherent placenta decision was taken to do peripartum hysterectomy. Consent was taken from relatives after explaining the situation in local language.

Total hysterectomy with careful bladder dissection was done as the placenta was attached to lower segment and blood was pooling continuously. After clamping, cutting and ligating of uterine arteries bleeding was significantly controlled. Care was taken to do complete hysterectomy however there was bleeding from vault and from vessels coursing over the superior surface of bladder inspite of taking hemostatic sutures. Thus finally decision of bilateral internal iliac artery ligation was taken and with all precautions internal iliac artery ligation was done after which bleeding got controlled. The effect could be seen in the form of steadily stabilizing blood pressure. Additionally blood loss was replaced by whole blood which also contributed to stabilizing the woman.

After assuring hemostasis the abdomen was closed in layers. The estimated total blood loss at that time was around 2.5 – 3.0 L. Postoperatively she relieved 3 more blood transfusions making a total of 10 units of blood. Dopamine drip of patient was tapered done with

continuous monitoring of vital and intensive care in high dependency unit. The histopathology report of the uterine specimen came out to be placenta accreta with chorionic villi invading the myometrium. With good care, postoperative course was uneventful, and the patient was discharged on 10th day with good maternal and neonatal condition. The woman had no residual disorders. This was a case of true maternal near miss for the patient as she went into cardiac arrest intraoperatively but could be saved by team of obstetricians and anesthetists and adequate care in intensive care unit.

Fig 1: Microphotograph showing chorionic villi invading the myometrium

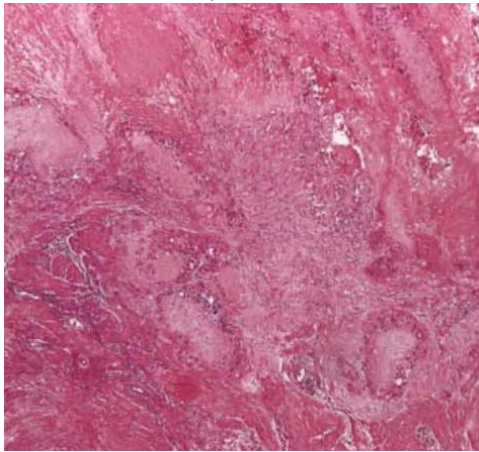
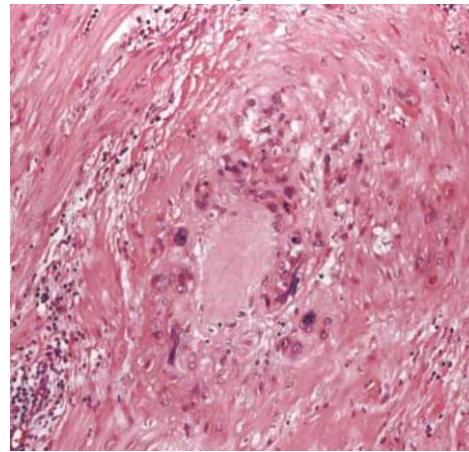


Fig 2: showing clumps of villi in the myometrium (100 X magnification)



3. Discussion

Placenta accreta is a general term used to describe the clinical condition when part of the placenta, or the entire placenta, invades and is inseparable from the uterine wall³. When the chorionic villi invade only the myometrium, the term *placenta increta* is appropriate; whereas *placenta percreta* describes invasion through the myometrium and serosa, and occasionally into adjacent organs, such as the bladder. Researchers have reported the incidence of placenta accreta as 1 in 533 pregnancies for the period of 1982–2002⁴.

Clinically, placenta accreta becomes problematic during delivery when the placenta does not completely separate from the uterus and is followed by massive obstetric hemorrhage. The average blood loss at delivery is 3,000–5,000 mL⁵. As many as 90% of patients with placenta accreta require blood transfusion, and 40% require more than 10 units of packed red blood cells. Maternal mortality has been reported to be as high as 7%⁶. Maternal death may occur despite optimal planning, transfusion management, and surgical care. In a study described by Shellhas, from a cohort of 39,244 women who underwent cesarean delivery, researchers identified 186 who had a cesarean hysterectomy. The most common indication was placenta accreta (38%)⁷.

Women at greatest risk of placenta accreta are those who have myometrial damage caused by a previous cesarean delivery with either anterior or posterior placenta praevia overlying the uterine scar. The authors of one study found that in the presence of a placenta praevia, the risk of placenta accreta was 3%, 11%, 40%, 61%, and 67% for the first, second, third, fourth, and fifth or greater repeat cesarean deliveries, respectively⁸. Placenta praevia without previous uterine surgery is associated with a 1–5% risk of placenta accreta. Besides advanced maternal age and multiparity, reported risk factors include any condition resulting in myometrial tissue damage followed by a secondary collagen repair, such as previous myomectomy, endometrial defects due to vigorous curettage resulting in Asherman syndrome⁹, submucous leiomyomas, thermal ablation¹⁰, and uterine artery embolization¹¹.

The diagnosis is usually established by ultrasonography and occasionally supplemented by magnetic resonance imaging (MRI). Transvaginal and transabdominal ultrasonography are complementary diagnostic techniques and should be used as needed. Transvaginal ultrasound is safe for patients with placenta previa and allows a more complete examination of the lower uterine segment. A normal placental attachment site is characterized by a hypoechoic boundary between the placenta and the bladder. The ultrasonographic features suggestive of placenta accreta include irregularly shaped placental lacunae (vascular spaces) within the placenta, thinning of the myometrium overlying the placenta, loss of the retroplacental “clear space,” protrusion of the placenta into the bladder, increased vascularity of the uterine serosa–bladder interface, and turbulent blood flow through the lacunae on Doppler ultrasonography^{12,13}. The presence and increasing number of lacunae within the placenta at 15–20 weeks of gestation have been shown to be the most predictive ultrasonographic signs of placenta accreta, with a sensitivity of 79% and a positive predictive value of 92%¹⁴. These lacunae may result in the placenta having a “moth-eaten” or “Swiss cheese” appearance. Overall, grayscale ultrasonography is sufficient to diagnose placenta accreta, with a sensitivity of 77–87%, specificity of 96–98%, a positive predictive value of 65–93%, and a negative predictive value of 98 (13, 14). The use of power Doppler, color Doppler, or three-dimensional imaging does not significantly improve the diagnostic sensitivity compared with that achieved by grayscale ultrasonography at one¹⁵. Magnetic resonance imaging can also be used, but is more costly than ultrasonography and requires both experience and expertise in the evaluation of abnormal placental invasion.

Management consists of a multidisciplinary approach. If diagnosed in antenatal period the delivery planning should involve an anesthesiologist, obstetrician, pelvic surgeon such as a gynecologic oncologist, intensivist, maternal–fetal medicine specialist, neonatologist, urologist, hematologist, and interventional radiologist to optimize the patient’s outcome¹⁶. To enhance patient safety, it is important that the delivery be performed by an experienced obstetric team. Because of the risk of massive blood loss, attention should be paid to maternal hemoglobin levels in advance of surgery, if possible¹⁷. The timing of delivery in cases of suspected placenta accreta must be individualized. This decision should be made jointly with the patient, obstetrician, and neonatologist. Patient counseling should include discussion of the potential need for hysterectomy, the risks of profuse hemorrhage, and possible maternal death. A guiding principle in management is to achieve a planned delivery because data suggest greater blood loss and complications in emergent cesarean hysterectomy versus planned cesarean hysterectomy¹⁸. Although a planned delivery is the goal, a contingency plan for emergency delivery should be developed for each patient.

Preoperatively, the blood bank should be placed on alert for a potential massive hemorrhage. Current recommendations for blood replacement suggest a 1:1 ratio of packed cells to fresh frozen plasma. Additional units of blood and coagulation factors should be infused quickly and as necessitated by the patient’s vital signs and hemodynamic stability.

Generally, the recommended management of suspected placenta accreta is planned term cesarean hysterectomy with the placenta left in situ because removal of the placenta is associated with significant hemorrhagic morbidity. Occasionally, a subtotal hysterectomy can be safely performed, but persistent bleeding from the cervix may preclude this approach and make total hysterectomy necessary. However, this approach

might not be considered first-line treatment for women who have a strong desire for future fertility. Therefore, surgical management of placenta accreta may be individualized.

Various studies have shown that bilateral internal iliac artery ligation is also an effective method of controlling bleeding in patients with placenta accreta, especially in those who are young and want to retain their reproductive functions¹⁹.

Despite the early and accurate prenatal diagnosis, hysterectomy remains the most common surgical procedure in cases of PPH for placenta praevia accreta²⁰. Nowadays, conservative interventions are recommended before radical procedure in order to minimize surgical complications and preserve fertility. The conservative options for PPH included uterotonic drugs, external compression with uterine sutures (B-Lynch, Hayman, Cho), intrauterine packing (Bakri balloon), and selective devascularization by ligation or embolization of the uterine artery²¹. However in placenta accreta per se many of these options may not work except for embolisation which has a great advantage in saving lives but requires a proper setup.

4. Conclusion

Placenta accreta is an uncommon but potentially lethal complication of pregnancy requiring intensive management. Although hysterectomy traditionally has been the definitive treatment for placenta accreta, clinicians should consider conservative management like bilateral internal iliac artery ligation for patients who wish to preserve fertility. Adequate transfusion facilities; sensitive ultrasound examination and rapidly responding, highly skilled surgical and anesthesia teams should be available nonetheless. In the present case multidisciplinary team approach and prompt surgical management saved the life of a woman.

References

- Oyelese Y, and Smulian J. C., "Placenta previa, placenta accreta, and vasa previa," *Obstetrics and Gynecology*, 2006. 107 (4): 927–941.
- Ronsmans C, Filippi V. Reviewing severe maternal morbidity: learning from survivors from life-threatening complications. In *Beyond the Numbers: Reviewing Deaths and Complications to Make Pregnancy Safer*. Geneva: World Health Organization; 2004.P.103-24.
- Hughes EC, editor. *Obstetric-gynecologic terminology: with section on neonatology and glossary on congenital anomalies*. Philadelphia (PA): F.A. Davis; 1972.
- Wu S, Kocherginsky M, Hibbard JU. Abnormal placentation: twenty-year analysis. *Am J Obstet Gynecol* 2005; 192:1458–61.
- Hudon L, Belfort MA, Broome DR. Diagnosis and management of placenta percreta: a review. *Obstet Gynecol Surv* 1998; 53:509–17.
- O'Brien JM, Barton JR, Donaldson ES. The management of placenta percreta: conservative and operative strategies. *Am J Obstet Gynecol* 1996; 175:1632–8.
- Shellhaas CS, Gilbert S, Landon MB, Varner MW, Leveno KJ, Hauth JC, et al. The frequency and complication rates of hysterectomy accompanying cesarean delivery. Eunice Kennedy Shriver National Institutes of Health and Human Development Maternal-Fetal Medicine Units Network. *Obstet Gynecol* 2009; 114:224–9.
- Silver RM, Landon MB, Rouse DJ, Leveno KJ, Spong CY, Thom EA, et al. Maternal morbidity associated with multiple repeat cesarean deliveries. National Institute of Child Health and Human Development Maternal-Fetal Medicine Units Network. *Obstet Gynecol* 2006; 107:1226–32.
- Al-Serehi A, Mhoyan A, Brown M, Benirschke K, Hull A, Pretorius DH. Placenta accreta: an association with fibroids and Asherman syndrome. *J Ultrasound Med* 2008; 27:1623–8.
- Hamar BD, Wolff EF, Kodaman PH, Marcovici I. Premature rupture of membranes, placenta increta, and hysterectomy in a pregnancy following endometrial ablation. *J Perinatol* 2006; 26:135–7.
- Pron G, Mocarski E, Bennett J, Vilos G, Common A, Vanderburgh L. Pregnancy after uterine artery embolization for leiomyomata: the Ontario multicenter trial. Ontario UFE Collaborative Group. *Obstet Gynecol* 2005; 105:67–76.
- Comstock CH. Antenatal diagnosis of placenta accreta: a review. *Ultrasound Obstet Gynecol* 2005; 26:89–96.
- Warshak CR, Eskander R, Hull AD, Scioscia AL, Mattrey RF, Benirschke K, et al. Accuracy of ultrasonography and magnetic resonance imaging in the diagnosis of placenta accreta. *Obstet Gynecol* 2006; 108:573–81.
- Comstock CH, Love JJ Jr, Bronsteen RA, Lee W, Vettrano IM, Huang RR, et al. Sonographic detection of placenta accreta in the second and third trimesters of pregnancy. *Am J Obstet Gynecol* 2004; 190:1135–40.
- Chou MM, Ho ES, Lee YH. Prenatal diagnosis of placenta previa accreta by transabdominal color Doppler ultrasound. *Ultrasound Obstet Gynecol* 2000; 15:28–35.
- Eller AG, Bennett MA, Sharshiner M, Masheter C, Soisson AP, Dodson M, et al. Maternal morbidity in cases of placenta accreta managed by a multidisciplinary care team compared with standard obstetric care. *Obstet Gynecol* 2011; 117:331–7.
- Anemia in pregnancy. ACOG Practice Bulletin No. 95. American College of Obstetricians and Gynecologists. *Obstet Gynecol* 2008; 112:201–7.
- Chestnut DH, Dewan DM, Redick LF, Caton D, Spielman FJ. Anesthetic management for obstetric hysterectomy: a multi-institutional study. *Anesthesiology* 1989; 70:607–10.
- Moili P, Sabeti S, Zaré F. Ligation of the internal iliac arteries in cases of placenta accrete. *J Gynecol Obstet Biol Reprod*.1976; 5(5):697-702.
- Mousa H. A. and Alfirevic Z., "Major postpartum hemorrhage: survey of maternity units in the United Kingdom," *Acta Obstetrica et Gynecologica Scandinavica*, 2002; 81(8): 727–730.
- Hayman R. G., Arulkumaran S., and Steer P. J., "Uterine compression sutures: surgical management of postpartum hemorrhage," *Obstetrics and Gynecology*, 2002; 99(3): 502–506.