

# Surgical Management of Sub-Axial Cervical Spinal Injuries - A Short Term Study

Pavitra Patnaik<sup>1</sup> and Mohit Patnaik<sup>2\*</sup>

<sup>1</sup>Associate Professor, Neurosurgery, Head-Neurotrauma, Government Medical College and trauma care centre, Nagpur, Maharashtra, India

<sup>2</sup>Assistant Professor, Department of Pharmacology, Mulayam Singh Yadav Medical College and Hospital, Meerut, Uttar Pradesh, India

## Abstract

**Background:** Acute sub-axial cervical spine injuries following trauma remain a common problem. The management of injuries is either conservative or surgical. The present study was carried out with an objective to assess the clinical and functional outcome of anterior cervical decompression and fusion (ACDF) with stabilization using locking titanium anterior cervical plate.

**Method:** Total 20 patients of spinal cord injury were selected for the study. Preoperatively, all the patients were evaluated by ASIA grading and radiologically by X- ray, CT and MRI. ACDF for dislocations (14 cases) and anterior corpectomy and fusion (6 cases) for fractures was done by using tricortical iliac graft with stabilization by locking anterior cervical plate.

**Results:** The majority of patients (14; 70%) had incomplete spinal cord injuries including ASIA grade B and C while only 6 (30%) patients had complete cord injury. The most common level of injury was C<sub>5</sub>-C<sub>6</sub> (30%) followed by C<sub>4</sub>-C<sub>5</sub> and C<sub>6</sub>-C<sub>7</sub> (25%). There was no recovery and one death observed in the complete (ASIA – A) lesion. In incomplete lesion, 20% of grade B patient were recovered to C level and remaining 15% recovered to D level. In those 7(35%) patients of ASIA grade C, 3(15%) patients recovered to D level and remaining 4 (20%) patients were recovered to E level. The correlation between the timing of surgery and Post-operative neurological improvement was not statistically significant.

**Conclusion:** The anterior cervical decompression and fusion using tricortical iliac graft is a safe procedure with high rate of pain relief, neurological recovery, and functional improvement in acute sub axial cervical spinal injuries.

**Keywords:** Sub-axial, Cervical, Trauma, Decompression, Fusion, Titanium, Anterior, Corpectomy, Tricortical.

### \*Correspondence Info:

Dr. Mohit Patnaik,  
Assistant Professor,  
Department of Pharmacology,  
Mulayam Singh Yadav Medical College and  
Hospital, Meerut, Uttar Pradesh, India

### \*Article History:

**Received:** 08/07/2019

**Revised:** 28/07/2019

**Accepted:** 29/07/2019

**DOI:** <https://doi.org/10.7439/ijbar.v10i7.5250>

### QR Code



**How to cite:** Patnaik P. and Patnaik M. Surgical Management of Sub-Axial Cervical Spinal Injuries - A Short Term Study. *International Journal of Biomedical and Advance Research* 2019; 10(7): e5250. Doi: 10.7439/ijbar.v10i7.5250 Available from: <https://ssjournals.com/index.php/ijbar/article/view/5250>

Copyright (c) 2019 International Journal of Biomedical and Advance Research. This work is licensed under a [Creative Commons Attribution 4.0 International License](https://creativecommons.org/licenses/by/4.0/)

## 1. Introduction

Spinal cord injury (SCI) is a devastating condition that can lead to significant neurological impairment and reduced quality of life [1]. SCI without radiographic abnormality has been found to occur in 0.08% of adults with blunt cervical spine trauma. When injuries are missed on initial assessment, a delay in diagnosis occurs that puts the patient at risk for progressive instability and neurologic deterioration [2]. More than 40 million people worldwide suffer from SCI every year; most of them are young men [3]. Developed countries [4,5] have higher incidence of SCI

as compared to developing countries [6,7]. Such variation may be due to the lack of incomplete data entry regarding prehospital data and less research on this topic.

Approximately two-third of all fractures and three-fourth of all dislocations involve the sub axial cervical spine. The sixth and seventh cervical vertebra together account for 39% of all cervical spine fractures. The C<sub>5</sub>-C<sub>7</sub> region contributes to 60% of all SCI in patients with cervical spine trauma. The management of patients with cervical spine injuries involves three phases – pre-hospital

care, emergency in hospital care, and definitive treatment [8]. The objective of surgical treatment is to stabilize the injured motion elements securely, in conjunction with restoring normal anatomy in order to preserve function and prevent secondary neurological damage [9].

Although decompression of spinal cord either anteriorly or posteriorly depending upon the site of compression is straight forward, there is no consensus regarding the approach for stabilization of spine either anterior or posterior or both, after decompression of spinal cord [10]. An anterior cervical decompression is often performed in patient with symptomatic anterior neural compression. Anterior interbody grafts alone are prone to displacement and deformity, if there is associated posterior instability. Anterior decompression even after 1 year has resulted in neurological recovery. Anterior and Posterior plating are equally effective in cervical trauma [11]. Imaging studies particularly MRI scan has shown that 20 to 60 % of dislocations are associated with disc prolapse, and the literature confirms that iatrogenic neurological injuries have occurred in patients in whom reduction and posterior stabilization were carried before anterior decompression. Thus, anterior discectomy, interbody fusion with internal fixation would be the optimal treatment in such instances. Anterior plating provides immediate and rigid stabilization even with posterior ligament injury [12,13]. Hence the present study was undertaken to assess the clinical and functional outcome of anterior cervical decompression and fusion with stabilization using locking titanium anterior cervical plating for sub axial cervical spinal injuries.

## 2. Materials and Methods

After obtaining Institutional Ethical Committee approval and written informed consent from all the patients, this prospective study was conducted in the Department of Neurosurgery at Superspeciality Hospital, Government Medical College, Nagpur, Maharashtra during the period of two years from August 2012 to August 2014. All patients with subaxial cervical fracture and fracture dislocation were included in the study. Patients with spinal cord injury without radiological abnormality and with multiple spine injury were excluded from the study. Total 20 patients were selected for the study, among them six were complete and remaining fourteen cases were incomplete spinal cord injuries.

Out of 20 patients, three got admitted within eight hours of injury and only these three patients received the methylprednisolone therapy (30 mg /kg as IV bolus and 5.4 mg / kg / 23 hours). All patients were treated in intensive care unit with strict monitoring of vitals like pulse rate, blood pressure, oxygen saturation, respiration. While resuscitation, patients were evaluated neurologically on the

basis of ASIA impairment scale. Patients were classified into complete or incomplete lesion based on the preservation of motor or sensory function distal to the level of lesion.

Once the patient was stabilized radiological evaluation was done by X -- ray of cervical spine --- anteroposterior and lateral view with traction to the shoulder. CT scan was done to see the bony details especially in retropulsed fragments in unstable burst fractures. MRI evaluation was done as early as possible to know the status of disc, ligament injury and more importantly to know the status of the spinal cord. If there is unifaceal or bifacetal dislocation and there is no evidence of posttraumatic disc prolapse in MRI, then the reduction is attempted by rapid traction method in which serial weights are added to the skull traction under close monitoring of neurological status. All patients with posttraumatic disc prolapse were immobilized with hard cervical collar followed by surgical decompression planned at the earliest possible.

Induction of aesthesia was done and axial traction of cervical spine was maintained by skull tongs throughout the procedure. Either a transverse or vertical incision was used. The incision was centered 3-5 finger breaths above the clavicle for C3 – C5 and 2-3 finger breaths above the clavicle for C6 and C7. Skin and platysma were incised. The superficial layer of deep cervical fascia was incised. The anterior border of sternomastoid muscle was identified and retracted laterally. Then the middle layer of deep cervical fascia was incised. The carotid sheath and sternomastoid was retracted laterally. The oesophagus, trachea, thyroid gland was identified and retracted medially. The deep layers of deep cervical fascia consisting of pretracheal and prevertebral overlying the longuscolli muscle were bluntly divided. The level of injury was identified clinically and fluoroscopically. Then the longuscolli muscle was retracted subperiosteally up to the level of uncovertebral joints. The anterior longitudinal ligament and annulus was incised and the disc material was removed with curettes. The disc material was removed till the posterior longitudinal ligament was visualized. Corpectomy if indicated can be done using power burrs till the posterior part of vertebral body was reached. Then the posterior cortical wall was removed using pituitary rongeurs. The retropulsed bone and disc fragments were removed completely.

After completion of discectomy or corpectomy, reduction was done using manual traction or by using vertebral body spreaders or by using Casper pins. Then the superior and inferior end plates are prepared. Tricortical iliac graft was taken and fitted in the gap and traction was released. Bone graft and disc space distraction was checked

with image intensifier. If adequate reduction and distraction was achieved anterior cervical locking plating applied with four locking screws and two head locking screws with imaging control. We were not applied the screws into the graft for the fear of graft breakage and collapse. Wound was closed in layers after perfect hemostasis.

On the 2<sup>nd</sup> day of surgery patients were encouraged to sit in the bed with or without support depending on their neurological status. On 10th days suture was removed depending on their improvement in neurological status patient were mobilized from bed. On 6th and 12th week after surgery radiological evaluation done for assessing the fusion by flexion and extension X- rays and if solid fusion was seen, the collar was removed and neck movements were progressively started. Subsequently the patients were followed at every month till 6 months and then every 2 months during the next 6 months and thereafter every 6 months. The results were evaluated on the basis of ASIA impairment scale. Neurological evaluation was done preoperatively and at the end of 6 months postoperatively. Statistical analysis was done using Paired sample T test, Chisquare test, descriptive and Analytical statistics.

### 3. Observations and Results

Among the 20 patients were studied, 15 (75%) were males and 05 (25%) were females. Most of the patients (9; 45%) were in the age group of 21-30 years followed by 31-40 years (30%) and others are shown in table 1. The mean age of patients was 42.29 years, ranged from 21-75 years. The most common mode of injury was road traffic accident (14; 70%) followed by accidental fall (6; 30%).

**Table 1: Age distribution of patients**

Age group	No. of Patients	Percentage
21-30	09	45%
31-40	06	30%
41-50	01	05%
51-60	03	15%
61-70	00	00%
71-80	01	05%
Total	20	100%

The presenting neurological status was graded as per the American Spine Injury Association (ASIA) grading system. In the present study, majority of patients i.e. 14 (70%) had incomplete spinal cord injuries including ASIA grade B and C while only 6 (30%) patients had complete cord injury, (Table 2).

**Table 2: Type of lesions**

Type of lesions	No. of Patients	Percentage
ASIA Grade A	06	30%
ASIA Grade B	07	35%
ASIA Grade C	07	35%

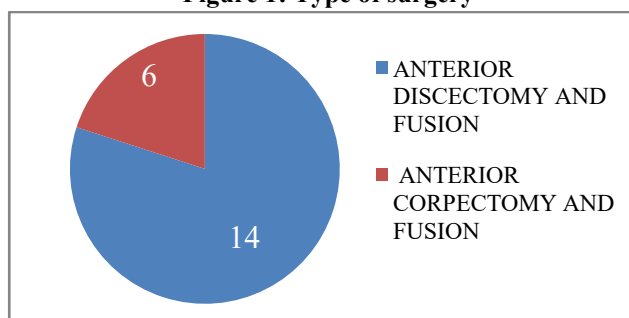
The most common level of injury was C<sub>5</sub>-C<sub>6</sub> (30%) followed by C<sub>4</sub>-C<sub>5</sub> and C<sub>6</sub>-C<sub>7</sub> (25%) and the other level of lesions is shown in table 3.

**Table 3: Distribution of patients according to level of lesions**

Level of lesion	No. of Patients	Percentage
C <sub>3</sub> -C <sub>4</sub>	02	10%
C <sub>4</sub> -C <sub>5</sub>	05	25%
C <sub>5</sub> -C <sub>6</sub>	06	30%
C <sub>6</sub> -C <sub>7</sub>	05	25%
C <sub>5</sub>	01	05%
C <sub>6</sub>	01	05%

Figure 1 show the type of surgery to be done. We done 14 (70%) anterior cervical discectomy and fusion using tricortical iliac graft with stabilization by locking anterior cervical plate for dislocations and 6 (30%) anterior corpectomy and fusion using tricortical iliac graft with stabilization by locking anterior cervical plate for fractures. We used the tricortical iliac graft for all cases of cervical fusion with height range from 6 mm to 18 mm (Average of 8.97 mm). Height of the graft was small in discectomies and large in carpectomies.

**Figure 1: Type of surgery**



There was no recovery and one death observed in the complete (ASIA – A) lesion. In incomplete lesion, 20% of grade B patient were recovered to C level and reaming 15% recovered to D level. In those 7(35%) patients of ASIA grade C, 3(15%) patients recovered to D level and reaming 4 (20%) patients were recovered to E level, (Table 4).

**Table 4: Neurological Status**

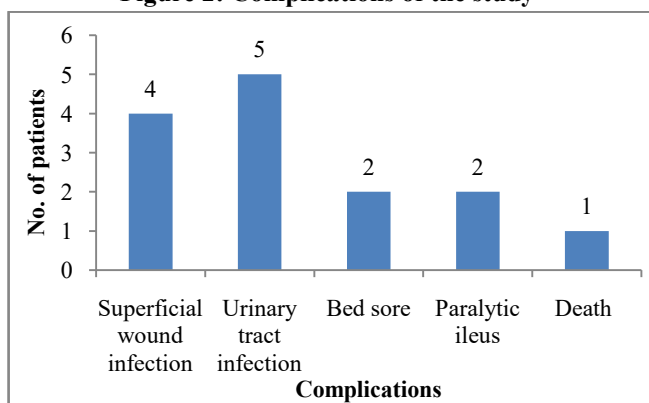
Preoperative Neurology	Postoperative Neurology
ASIA Grade A- 6 (30%)	5 (25%) (1- death)
ASIA Grade B- 7 (35%)	C- 4 (20%)
	D- 3 (15%)
ASIA Grade C- 7 (35%)	D- 3 (15%)
	E- 4 (20%)

When comparing the neurological status of the patients in the pre-operative and postoperative status an increase of 1.29±0.87 was observed. This observed increase in the postoperative status was found to be statistically significant by using Paired T sample test (P < 0.0005 ± - 5.264) and 95 % confidence interval was -1.60 to - 0.67).

We had 14 cases of dislocation out of that five (35.71%) were reduced within twenty four hours by closed manipulation without anesthesia and 9 (64.28%) dislocations were not reduced in that five (35.71%) having bilateral facet locking which was reduced by skull traction. In closed manipulation cases there were no further neurological deterioration was noted. In Chi square test correlation between times from injury and postoperative neurological status were analyzed in which P value came to be 0.312. This P value is statistically not significant.

Various complications observed in the study are depicted in figure 2. In the majority of patients (9; 45%) fusion was attained at six weeks, in 5 (25%) patients fusion attain at 12 weeks. In 3 (15%) cases fusion attain at 16 weeks, in 2 (10%) at 20 weeks and 1 (5%) at 24 weeks.

**Figure 2: Complications of the study**



#### 4. Discussion

The surgical management of fracture dislocation of the sub axial cervical spine is based on decompression of the impaired neural elements and restoration of the normal spinal arch with stabilization [14, 15]. Thin sections of CT and MR imaging are show with clarity the relationship between bony injuries and spinal cord damage. Bohlman *et al* [16] mentioned that anterior decompression may allow for maximal neurological recovery in patients with incomplete neurological deficits and radiographic evidence of persistent spinal cord compromise. In present study also anterior decompression and fusion with stabilization improve the neurological recovery especially in incomplete cord lesions. Male patients were predominant in this study as similar to the previous studies [6,17,18]. Higher incidence in males may be because of male gender being exposed to most of the outdoor activities. Most commonly affected age group was between 21-30 years with the mean age of 42.29 years whereas in developed countries average age was 30.7 to 48.5 years and it was <30 years in developing countries [19]. The most common mode of violence is Road traffic accident and C<sub>5</sub>-C<sub>6</sub> level was the commonest involved site which is similar to the earlier studies [3, 20].

Out of 20 cases all incomplete lesions (14 cases) were recovered well, this result is compared with results by Bohlman *et al* [16] and Cloward *et al* [21]. Only three patients came within eight hours since injury and they received the methylprednisolone infusion. None of them have gastrointestinal haemorrhage. Regarding reduction Robert *et al* [22] stated that when dislocation is complete, reduction must be attempted only under anesthesia and the administration of anesthesia is not a dangerous procedure. But in current study all reductions were done without anesthesia. Two patients (10%) was underwent open reduction. The most important factor responsible for prognosis of neurological recovery was age of the patient and neurological status at the time of injury. This is also confirmed in present study, in which 75% of the patients under the age of 40 years and who were having incomplete lesion have better neurological recovery. Patients whose MRI showing features of cord contusion have poor recovery.

Early surgery, patient had earlier and better outcome and rehabilitation. Mortality rate in late surgery cases is significantly higher probably these patients are recumbent for a longer duration which may be detrimental to their cardiorespiratory status. But in current series the correlation between the timing of surgery and post-operative neurological improvement was not statistically significant. The limitation of study is that the sample size was small and follow up period was also short to comment largely.

#### 5. Conclusion

The anterior cervical decompression and fusion using tricortical iliac graft is a safe procedure with high rate of pain relief, neurological recovery, and functional improvement in acute sub axial cervical spinal injuries. Grafting complications like graft failure, kyphotic deformity were reduced and fusion rate was improved by using the locking anterior cervical plating. We had no plate and screw, graft failure in this series.

#### References

- [1]. Hachem LD, Ahuja CS, Fehlings MG. Assessment and management of acute spinal cord injury: From point of injury to rehabilitation. *The Journal of Spinal Cord Medicine* 2017; 40(6): 665-675.
- [2]. Torretti JA, Sengupta DK. Cervical spine trauma. *Indian J Orthop.* 2007; 41(4):255-267.
- [3]. Kafle P, Khanal B, Yadav DK, Poudel D and Cherian L. Spinal cord injury, Clinical Profile and its Management at Tertiary Care Center in Nepal, *JoNMC* 2019; 8(1):16-21.

- [4]. Dahlberg A, Kotila M, Leppänen P, Kautiainen H, Alaranta H. Prevalence of spine cord injury in Helsinki, *Spine Cord*. 2005; 43: 47-50.
- [5]. Albert T, Ravaud JF. Rehabilitation of spine cord injury in France: a nationwide multicenter study of incidence and regional disparities, *Spine Cord*. 2005; 43: 357-65.
- [6]. Birua GJ, Munda VS, Murmu NN, Epidemiology of spine injury in north east India: a retrospective study, *Asian Journal of Neurosurgery* 2018; 13(4):1084.
- [7]. Hoque MF, Grangeon C, Reed K. Spine cord lesions in Bangladesh: an epidemiological study 1994-1995, *Spine Cord*. 37 (1999) 858-61.
- [8]. Zaveri G, Das G. Management of sub-axial cervical spine injuries. *Indian J Orthop* 2017; 51:633-52.
- [9]. Manoj Kumar CV and Ravikumar V. Functional outcome of cervical spine locking plate fixation in traumatic quadriplegics. *International Journal of Orthopaedics Sciences* 2018; 4(1): 1035-1042.
- [10]. T S Vasan M Ch. Circumferential fusion for sub-axial cervical spine fracture – subluxations. *Indian Journal of Neurotrauma (IJNT)* 2007; 4(1):65-70.
- [11]. Cheung JP, Luk KD. Complications of Anterior and Posterior Cervical Spine Surgery. *Asian Spine J*. 2016; 10(2):385–400.
- [12]. Botolin S, VanderHeiden TF, Moore EE, Fried H, Stahel PF. The role of pre-reduction MRI in the management of complex cervical spine fracture-dislocations: an ongoing controversy?. *Patient Saf Surg*. 2017; 11:23.
- [13]. Wimberley DW, Vaccaro AR, Goyal N *et al*. Acute quadriplegia following closed traction reduction of a cervical facet dislocation in the setting of ossification of the posterior longitudinal ligament: case report. *Spine (Phila Pa 1976)*. 2005; 30(15):E433-8.
- [14]. Cooper PR, Operative management of cervical spine injuries. *Clin Neurosurg* 1988; 34: 650-74.
- [15]. McAfee PC, Bohlman HH: One stage anterior cervical decompression and posterior stabilization with circumferential arthrodesis: A study of twenty-four patients who had a traumatic or neoplastic lesion. *J Bone Joint Surg (Am)* 1989; 71 A: 78-88.
- [16]. Bohlman HH, Anderson PA. Anterior decompression and arthrodesis of the cervical spine: long term motor improvement. Part-I- improvement in incomplete traumatic quadriplegia. *J Bone and Joint Surg (Am)* 1992; 74A: 671-82.
- [17]. Hoque MF, Grangeon C, Reed K. Spine cord lesions in Bangladesh: an epidemiological study 1994–1995, *Spine cord*. 1999; 37: 12: 858.
- [18]. Masood Z, Wardug GM, Ashraf J. Spine injuries: experience of a local neurosurgical centre, *Pakistan Journal of Medical Sciences*. 2008; 24: 3: 368.
- [19]. Chiu WT, Lin HC, Lam C, Chu SF, Chiang YH, Tsai SH. Epidemiology of traumatic spine cord injury: comparisons between developed and developing countries, *Asia Pacific Journal of Public Health* 2010; 22(1): 9-18.
- [20]. Ali MI, Ahsan K, Awwal MA, Khan RH, Akhond S, Das KP. Treatment of cervical disc prolapsed by anterior cervical discectomy fusion and stabilization with plating. *Mymensingh Med J*. 2009; 18(2): 226-31.
- [21]. Cloward RB: Treatment of acute fractures and fracture-dislocations of the cervical spine by vertebral-body fusion. *J Neurosurg* 1961; 18: 201– 209.
- [22]. Robert *et al*. Neurological deterioration after Reduction of cervical subluxation. *J. Bone and Joint Surg., Br* 1992; 74; 224-227.