

Diagnostic utility of Ultrasonography in chronic salivary gland lesions

S. V. Bhise¹, P. M. Hippargekar^{*2}, Anuradha G. Mache³

¹Associate Professor, ²Professor and Head, ³3rd year Resident

Department of ENT, Swami Ramanand Teerth Rural Government Medical College, Ambajogai, Maharashtra, India-431517

Abstract

Background: Salivary gland lesions are quite common in people of all age groups. Clinical examination alone is not able to differentiate between them and pinpoint the exact cause. There are many salivary gland imaging can be used but the ultrasonography (USG) is a non-radiation, inexpensive, and readily available imaging technique that can be used to make diagnosis of salivary gland lesions. Hence the present study was undertaken to estimate the utility of ultrasonography in the diagnosis of chronic salivary gland lesions.

Method: In this study, total 42 cases of various salivary gland lesions were evaluated by detail history, clinical, USG and histopathological examination. Histopathological reports were compared with USG findings.

Results: Most of the salivary gland lesions were involving the parotid gland (59.5%), common in males (57.14%) and mostly in the age group of 31-40 years (23.81%). Based on ultrasonography, 15 cases (35.71%) were non-neoplastic and 27 cases (64.29%) were diagnosed as neoplastic lesions. Among the neoplastic lesions, 21 (77.78%) cases were of benign tumors, 05 (18.52%) of malignant tumors and 01 (3.7%) case was suspicious for malignancy. Based on histopathology, 14 cases (33.3%) were non-neoplastic and 28 (66.7%) were neoplastic. Among the neoplastic lesions, 23 (82.14%) cases were of benign tumors and 05 (17.85%) cases were of malignant tumors. Sensitivity, specificity and diagnostic accuracy of USG of salivary gland lesions were 89.29%, 85.71% and 88.09% respectively.

Conclusion: USG should be used for initial assessment of all salivary gland lesions preoperatively to avoid open biopsy. However accurate and confirmatory diagnosis is given by histopathology.

Keywords: Ultrasonography, Histopathology, Diagnosis, Parotid gland, Tumors, Sensitivity, Specificity.

*Correspondence Info:

Dr. P M Hippargekar,
Professor and Head,
Department of ENT,
Swami Ramanand Teerth Rural Government
Medical College, Ambajogai, MS, India-431517

*Article History:

Received: 17/04/2019

Revised: 28/04/2019

Accepted: 29/04/2019

DOI: <https://doi.org/10.7439/ijbar.v10i4.5160>

QR Code



How to cite: Bhise S. V., Hippargekar P. M., Mache A. G. Diagnostic utility of Ultrasonography in chronic salivary gland lesions. *International Journal of Biomedical and Advance Research* 2019; 10(4): e5160. Doi: 10.7439/ijbar.v10i4.5160

Available from: <https://ssjournals.com/index.php/ijbar/article/view/5160>

Copyright (c) 2019 International Journal of Biomedical and Advance Research. This work is licensed under a [Creative Commons Attribution 4.0 International License](https://creativecommons.org/licenses/by/4.0/)

1. Introduction

Diagnosis of salivary gland disorders is a challenge to any clinician, as they could be involved in a wide array of diseases. The salivary glands are commonly affected by inflammatory, infectious, obstructive, systemic, and neoplastic pathologies [1]. The lesions of salivary gland are quite common in people of all age groups. Preoperative assessment and diagnosis of these lesions include: anamnesis, clinical examination, imaging techniques (plain film, sialography, ultrasonography, CT – computer tomography, MRI – magnetic resonance imaging, and scintigraphy), fine-needle aspiration (FNA) biopsy, and core- biopsy [2]. In addition to localizing the lesion, imaging is essential in determining the extent of disease,

involvement of skull base, mandible, and neural spread in case of malignant lesions. Literature evidence states that USG is a superior imaging modality in many aspects as it offers non-invasive, cost-effective, concise, and broad-spectrum imaging of salivary glands [3].

An ultrasonography uses sound waves; the echoes of the sound waves create a picture of the inside of the body. The advantages of ultrasonography can be useful for parotid and submandibular gland disorders but has limited only for the superficial locations, but is best to differentiate between intra and extra glandular masses, as well as between cystic and solid lesions. Solid benign lesions present as well circumscribed hypo echoic intra glandular masses. Ultrasonography can also demonstrate the presence

of an abscess in an acute inflamed gland, as well as sialolithiasis with echogenic densities that shows acoustic shadowing [4].

Many authors have studied the lesions of salivary gland swellings, however data in rural population is still lacking. It becomes an interesting study because most of the patients are exclusively from the rural population. In view of above, the present study was undertaken to decide the feasibility and utility of ultrasonography in the diagnosis of patients with salivary gland swellings attending a rural based hospital and the study of distribution of various lesions occurring in this region. This study was also enable us to know the limitations if any, of sonographic and cytological findings in interpreting the lesions of the salivary gland.

2. Materials and Methods

After obtaining Institutional Ethical Committee approval, this prospective observational study was carried out in the Department of ENT at Tertiary Care Hospital during the period of two years from October 2016 to October 2018. The patients of all age group presenting with salivary glands welling/ inflammatory, cystic and neoplastic (both benign and malignant) lesions of the salivary gland with a history of 3 months or more and those attending the outpatient Department of ENT and admitted in ENT ward were included in the study. Total 42 cases of chronic salivary gland lesions were selected for the study. The patients with acute salivary gland swellings, lesions other than salivary gland swellings and patients who presented clinically as salivary gland swelling, but microscopically where not arising from salivary gland origin were excluded from the study.

A detailed history was taken, clinical examination was done and USG was carried out on OPD basis. After taking informed consent, patients underwent surgical procedure and histopathological reports were traced and compared with USG findings.

3. Observations and Results

Among the 42 cases studied, 24 cases (57.14%) were males and 18 cases (42.86%) were females. The male to female ratio was 1.3:1. The age of patients ranged from 16 years to 80 years. Chronic salivary gland lesions were more common in the age group of 31-40 years (23.81%) followed by 41-50years (21.43%), (Table 1).

Table 1: Age wise distribution pattern in salivary gland lesions

Age group (Years)	No. of Cases	Percentage (%)
11-20	05	11.91
21-30	08	19.04
31-40	10	23.81
41-50	09	21.43
51-60	05	11.91
61-70	04	9.52
71-80	01	2.38

The parotid gland was the commonest site involved in 25 (59.5%) cases, the submandibular gland and minor salivary glands were involved in 15 (35.7%) and 2(4.8%) cases respectively. Based on ultrasonography, 15 cases (35.71%) were non-neoplastic and 27 cases (64.29%) were diagnosed as neoplastic lesions. Among neoplastic lesions, 21 (77.78%) cases were of benign tumors, 05 (18.52%) cases were of malignant tumors and 01 (3.7%) case was suspicious for malignancy.

Ultrasonography diagnoses shows 19 (45.2%) cases of pleomorphic adenoma, 07 (16.7%) chronic sialadenitis, 05 cases each of chronic sialadenitis with sialolithiasis and malignant neoplastic lesion, 03 (7.1%) cases of cystic lesions and 01 (2.4%) case each of warthin’s tumor, benign neoplastic lesion and neoplastic lesion suspicious for malignancy, (Table 2).

Table 2: Ultrasonography diagnoses of salivary gland lesions

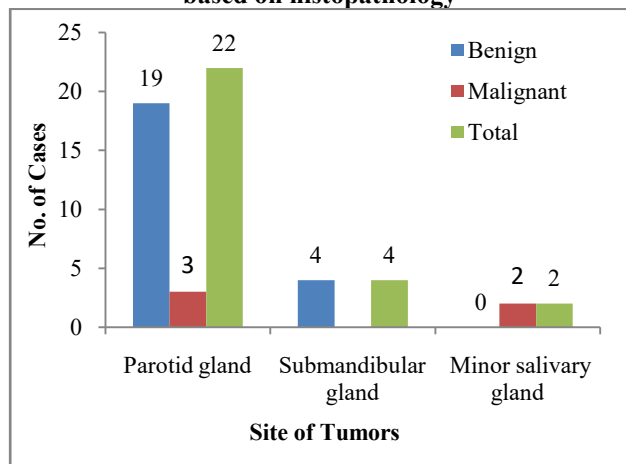
USG Diagnoses		No. of Cases	Percentage (%)
Non neoplastic	Chronic sialadenitis	07	16.7
	Cystic lesions	03	7.1
	Chronic Sialadenitis with sialolithiasis	05	11.9
Neoplastic	Pleomorphic adenoma	19	45.2
	Warthin’s tumor	01	2.4
	Benign neoplastic lesion	01	2.4
	Malignant neoplastic lesion	05	11.9
	Neoplastic lesion suspicious for malignancy	01	2.4

Table 3 shows the histopathological diagnoses of salivary gland lesions. Based on histopathology, the most common site of involvement of salivary gland tumor was the parotid gland (78.57%) and second most frequent site was the submandibular gland (14.29%), (Figure 1). Parotid gland was the most common site for benign tumors (67.85%) as well as malignant tumors (10.72%). Similarly, the most common site of involvement of pleomorphic adenoma was the parotid gland 14 (77.78%) and second most frequent site was the submandibular gland 4 (22.22%).

Table 3: Histopathological diagnoses of salivary gland lesions

Histopathological Diagnoses		No.	(%)	
Non neoplastic [14 (33.3%)]	Chronic sialadenitis	09	21.4	
	Lymphoepithelial cyst	03	7.1	
	Chronic Sialadenitis with sialolithiasis	02	4.8	
Neoplastic [28 (66.7%)]	Benign Lesion [23 (82.14%)]	Pleomorphic adenoma	18	42.9
		Warthin’s tumor	03	7.1
	Malignant lesion [05 (17.85%)]	Basal cell adenoma	02	4.8
		Mucoepidermoid carcinoma	03	7.1
		Adenoid cystic carcinoma	02	4.8

Figure 1: Site wise distribution of salivary gland tumors based on histopathology



Considering histopathology as gold standard, the overall diagnostic value of USG (whether neoplastic or non-neoplastic) was calculated, (Table 4). Sensitivity, specificity and diagnostic accuracy of USG of salivary gland lesions were 89.29%, 85.71% and 88.09% respectively.

Table 4: Ultrasonography-Histopathology correlation of salivary gland lesions

USG	HPE		Total
	Non-Neoplastic	Neoplastic	
Non-Neoplastic	12 (TN)	3 (FN)	15
Neoplastic	2 (FP)	25 (TP)	27
Total	14	28	42

TP- true positive, TN- true negative, FP- false positive, FN- false negative

4. Discussion

Salivary gland lesions are diverse ranging from inflammatory conditions to benign and malignant neoplasms. In case of acute inflammation, the salivary glands are enlarged and hypoechoic with increased blood flow. These may contain multiple, small, oval and hypoechoic areas [5]. When abscesses are present, the echo structure is usually cystic or hypoechoic lesion with reactive vascularity of surrounding parenchyma [6, 7]. The aim of sonographic investigation in acute inflammation is to rule out sialectasia, which is due to sialolithiasis.

However chronic inflammatory conditions of salivary glands like chronic sialadenitis present as intermittent painful swelling of the gland. Sonographic changes are usually more moderate [8] and including features are normal sized or smaller salivary glands. The structure of the gland becomes inhomogeneous and sometimes a few hypoechoic lesions up to 1 cm in diameter can be visualized and do not have increased blood flow [9]. These lesions usually have an eccentric, echogenic hilum and are assumed to be reactive lymph nodes. However, in chronic inflammation, a normal sonogram does not rule out subtle pathologic changes [7, 9,10].

In the present study, most common age group for presenting chronic salivary gland lesions was 31-40 years and the incidence of chronic salivary gland lesions was more in males as compared to females which are comparable with the study done by Gandhi *et al* [11]. The parotid gland was the most frequently involved followed by submandibular and minor salivary glands. Similar results were observed by Singh *et al* [12] and Ashraf *et al* (2009) [13]. Ultrasonography diagnosed 27 (64.29%) cases as neoplastic and 15 (35.71%) cases as non-neoplastic. Thus neoplastic salivary gland lesions were more common in present study, this is concordance with the study done by Petrovan *et al* [2] they reported more neoplastic [20 (60.6%)] lesions than non-neoplastic [13(39.4%)]. Benign tumors were more common than malignant tumors which are correlated with the findings reported by previous studies [2, 14, and 15]. Chronic sialadenitis was the commonest non neoplastic lesion whereas pleomorphic adenoma was the commonest neoplastic lesion.

Out of the 27 cases which were diagnosed as neoplastic on ultrasound, 25 cases were confirmed on histopathology. False positive results occurred in 2 cases, which were confirmed as non-neoplastic on histology. Among the 2 false positive cases, 1 case reported as benign neoplastic lesion on ultrasound, turned out to be chronic sialadenitis on histology while 1 case reported as pleomorphic adenoma on ultrasound, turned out to be lymphoepithelial cyst on histology. Out of the 15 cases which were diagnosed as non-neoplastic on ultrasound, 12 cases were confirmed on histology. False negative results occurred in 3 cases, which were confirmed to be neoplastic on histology. Among the false negative cases, 2 cases reported as chronic sialadenitis on ultrasound turned out to be pleomorphic adenoma and warthin’s tumor (1 case each) on histology while 1 case reported as cystic lesion on ultrasound turned out to be basal cell adenoma on histology. The overall sensitivity, specificity and diagnostic accuracy of ultrasonography for salivary gland lesions in the present study was 89.29 %, 85.71% and 88.09% respectively. This efficacy of USG for salivary gland lesions were compared with the various studies [2, 16-18].

Gandage *et al* [16] reported that high resolution ultrasonography could satisfactorily diagnose all the salivary gland lesions. However, it could not differentiate between various types of malignant lesions. Enlarged lymphnodes with loss of internal architecture and benign neoplasm could also not be differentiated satisfactorily.

Sridhar *et al* [19] concluded that though slight variation is seen with reference to ultrasonographic observation of benign and malignant neoplasms, it gives good results to confirm malignancy because of the fact of unclear borders. However, ultrasonography could not replace histopathological examination for final diagnosis.

5. Conclusion

USG is simple methods of diagnosis of salivary gland lesions. It can be performed as outpatient department procedures, acceptable to most of the patients, do not require anaesthesia and instant results are available. The sensitivity, specificity and diagnostic accuracy of USG for salivary gland lesions was reasonably good in present study and comparable with most of the other studies. Although limitations are encountered while predicting specific lesions, USG of salivary gland lesions in conjunction with thorough clinical history and physical examination provide very useful information to surgeon to reach the correct diagnosis and to plan further line of management.

Hence the USG should be used for initial assessment of all salivary gland lesions preoperatively to avoid open biopsy. However accurate and confirmatory diagnosis is given by histopathology.

The potential limitations of this study were that, the sample size was not large enough; USG reports used were from various radiologists and pathologists with different levels of experience.

References

- [1]. Paulose S, Rangdhol V, Kavya L, Dhanraj T. An insight into ultrasonography of salivary glands: A review. *J Med Radiol Pathol Surg* 2018; 5:1-6
- [2]. Petrovan C, Nekula DM, Mocan SL, Voidazan TS Ac. Ultrasonography – histopathology correlation in major salivary glands lesions. *Rom J Morphol Embryol* 2015; 56(2): 491–7.
- [3]. Shenoy AS, Dinkar AD, Khorate M, Satoskar S. Role of ultrasonography in salivary gland health and disease - A review. *IOSR J Dent Med Sci* 2016; 15: 43-6.
- [4]. Nanan Nur'aeny and Riani Setiadhi. "Ultrasonography as a Diagnostic Tool for Salivary Gland Disorders". *Oral Health and Dentistry* 2018; 2(3): 393-397.
- [5]. Shenoy AS, Dinkar AD, Khorate M, Satoskar S. Role of Ultrasonography in Salivary Gland Health and Disease – A Review. *IOSR Journal of Dental and Medical Sciences (IOSR-JDMS)* 2016; 15(1); 43-46.
- [6]. Thiede O, Stoll W, Schmal F. Clinical aspects of abscess development in parotitis [in German]. *HNO*. 2002; 50: 332-38.
- [7]. Traxler M, Schurawitzki H, Ulm C, et al. Sonography of nonneoplastic disorders of salivary glands. *Int J Oral Maxillofac Surg*. 1992; 21: 360-63.
- [8]. Yousem DM, Kraut MA, Chalian AA. Major salivary gland imaging. *Radiology*. 2000; 216: 19-29.
- [9]. Ching AS, Ahuja AT, King AD, Tse GM, Metreveli C. Comparison of the sonographic features of acalculous and calculous submandibular sialadenitis. *J Clin Ultrasound* 2001; 29:332–338.
- [10]. Gritzmann N, Rettenbacher T, Hollerweger A, Macheiner P, Hubner E. Sonography of the salivary glands. *Eur Radiol*. 2003; 13: 964-75.
- [11]. Gandhi SH, Purohit TM, Purohit MB, Jethwani D VM. FNAC Diagnosis of Salivary Gland Lesions With Histopathological Correlation. *Natl J Integr Res Med*. 2013; (4(3)):70–7.
- [12]. Singh Nanda KD, Mehta A NJ. Fine-needle aspiration cytology: a reliable tool in the diagnosis of salivary gland lesions. *J Oral Pathol Med*. 2012; 41(1):106–12.
- [13]. Ashraf A, Shaikh AS, Kamal F, Sarfraz R BM. Diagnostic reliability of FNAC for salivary gland swellings: A comparative study. *Diagn Cytopathol*. 2009; (38): 499–504.
- [14]. Kovacević DO FI. Sonographic diagnosis of parotid gland lesions: correlation with the results of sonographically guided fine-needle aspiration biopsy. *J Clin Ultrasound*. 2010; 38(6):294–8.
- [15]. Li ZHANG ZYZ. Evaluation of the ultrasonographic features of salivary gland tumors. *Chinese J Dent Res*. 2010; 13(2).
- [16]. Ganda Ge SG, Kachewa R SG. An imaging panorama of salivary gland lesions as seen on high resolution ultrasound. *Journal of clinical and diagnostic research: JCDR*. 2014 Oct; 8(10): RC01.
- [17]. Wan Y-L, Chan S-C, Chen Y-L et al. Ultrasonography-guided core-needle biopsy of parotid gland masses. *AJNR Am J Neuroradiol*. 2004; 25:1608–12.
- [18]. Taki S, Yamamoto T, Kawai A et al. Sonographically guided core biopsy of the salivary gland masses: safety and efficacy. *Clin Imaging*. 2005; 29:189–94.
- [19]. Sridhar T, Gnanasundaram N. Ultrasonographic Evaluation of Salivary Gland Enlargements: A Pilot Study. *International Journal of Dental Science and Research* 2013; 1(2):28-35.