

International Journal of Biomedical and Advance Research

ISSN: 2229-3809 (Online); 2455-0558 (Print)

Journal DOI: <https://doi.org/10.7439/ijbar>

CODEN: IJBABN

Case Report

Effectiveness of Lung Flute Device on Miliary Tuberculosis in Intensive Care Unit - A Case ReportSadaf Shaikh^{*1} and Maria Lamuvel²¹MPT in Cardio-Respiratory Physiotherapy, Dr. A. P. J. Abdul Kalam College of Physiotherapy, Loni, Maharashtra 413736, India²Assistant Professor, Dr. A. P. J. Abdul Kalam College of Physiotherapy, Loni, Maharashtra 413736, India**Abstract**

Pulmonary Tuberculosis (TB) is one of the top 10 causes of death worldwide. It is one of the oldest diseases known to man and remains one of the rifest diseases in the world. Miliary Tuberculosis, a type of Extrapulmonary TB is an illness produced by acute diffuse dissemination of tubercle bacilli into the blood stream. A 40 year old female housewife by occupation was admitted to Intensive Care Unit (ICU) of Pravara Rural Hospital 6 months back. Her chief complaints were breathlessness associated with cough. As per the investigations, patient was diagnosed with Miliary Tuberculosis and on examination, patient had excessive secretions. A new small OPEP device-Lung Flute was given as an intervention to the patient for mucus clearance. The intervention was given twice a day/3 days in a week for a period of 2 weeks. Pulmonary Function Test and sputum volume were the outcome measures of the study. After 2 weeks of intervention, there was significant improvement in the Pulmonary components and secretions were expectorated easily. This case report established the evidence for the use of Lung Flute Device in Miliary TB and other respiratory conditions which can be included in the Bronchial hygiene therapy regime.

Keywords: Lung Flute Device, Miliary Tuberculosis, PFT, Sputum Volume.***Correspondence Info:**

Dr. Sadaf Shaikh,
MPT in Cardio-Respiratory Physiotherapy,
Dr. A. P. J. Abdul Kalam College of
Physiotherapy, Loni, Maharashtra 413736, India

***Article History:**

Received: 03/10/2019
Revised: 26/11/2019
Accepted: 29/11/2019
DOI: <https://doi.org/10.7439/ijbar.v10i11.5118>

QR Code

How to cite: Shaikh S and Lamuvel M. Effectiveness of Lung Flute Device on Miliary Tuberculosis in Intensive Care Unit - A Case Report. *International Journal of Biomedical and Advance Research* 2019; 10(11): e5118. Doi: 10.7439/ijbar.v10i11.5118 Available from: <https://ssjournals.com/index.php/ijbar/article/view/5118>

Copyright (c) 2019 International Journal of Biomedical and Advance Research. This work is licensed under a [Creative Commons Attribution 4.0 International License](https://creativecommons.org/licenses/by/4.0/)**1. Introduction**

Pulmonary Tuberculosis (TB) is the oldest disease known to man and remains one of the most widespread diseases in the world. [1] Miliary tuberculosis, a type of Extrapulmonary Tuberculosis is an illness produced by acute diffuse dissemination of tubercle bacilli via the blood stream. Miliary tuberculosis was first described in 1700 by John Jacob Manget, who likened the tiny, disseminated caseous lesions to millet seeds. It can occur in both primary and post primary TB and is commonly seen in the elderly, children under 2 years old and in immunocompromised patients. It came to be recognized as a rare but fatal form of disseminated tuberculosis most frequently affecting the young. In the lung this process is manifested by the appearance of tiny discrete foci uniformly distributed. The

word “miliary” is from the Latin miliarius which means the size of a millet seed. TB presents with symptoms like fever, malaise and weight loss that are often attributed to related processes such as HIV infection, alcoholism or malnutrition [2-4]. Miliary mottling in the chest radiograph, an important clue to the diagnosis of disseminated tuberculosis. The difficulty of reaching a diagnosis of disseminated tuberculosis in the elderly in the absence of classical features is complicated further by the high incidence of concomitant disease processes.[5] Tuberculosis is a restrictive disease which affects the lung functions and aids in accumulation of secretion in the lungs.¹Ever thought much about coughing? It is one of those bother some things in life that no one likes and that you try to get rid of as soon

as possible when it occurs. Taking a closer look, though, coughing is a therapeutic tool that serves a definite purpose, for those who need to use it, rather than an inconvenience, coughing is an essential mechanism for airway clearance. [6]

The Lung Flute developed by Medical Acoustics, Buffalo, NY, USA is a new small self-powered audio device that belongs to the family of Oscillatory Positive Expiratory Pressure (OPEP) devices, which includes the Flutter and the Acapella. The device consists of a mouth piece and a replaceable reed inside a 36.8cm rectangular hardened plastic tube. This device generates sound with a frequency of 18–22 Hz. This sound wave, when generated at the mouth by mild exhalation, travels back down the tracheobronchial tree and vibrates in tracheobronchial secretions and loosens and mobilizes them. The Lung Flute supplements the natural mucus clearing system by artificially vibrating the airways and cilia, hence this functionality of the Lung Flute has been applied to sputum induction for diagnostic testing, for which it is currently a Food and Drug Administration (FDA) approved device. [7,8]

This case study describes the effectiveness of the Lung Flute Device that plays an important role in removal of secretions thus improving the pulmonary function of the patient.

Figure 1.1 Lung Flute Device



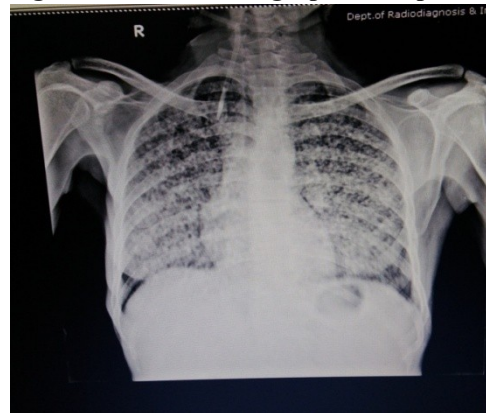
2. Case description

A 40 year old female housewife by occupation was admitted to Intensive Care Unit (ICU) of Pravara Rural Hospital 6 months back. The patient presented in the hospital with chief complaints of breathlessness which was associated with cough since 6 months. As per the investigations done in the hospital, the patient was diagnosed with Miliary Tuberculosis. The further assessment showed that the patient had excessive cough which was difficult to expectorate.

2.1 Investigations

A Chest Radiograph of the patient showed multiple tiny nodules scattered all over the lungs which is a classical sign of Miliary Tuberculosis.

Figure 1.2 Chest Radiograph of the patient



2.2 Outcome measures

- 1) Pulmonary Function Test (FVC, FEV₁, PEFr)
- 2) Sputum Volume

2.3 Intervention

Before starting the intervention, a brief procedure about the treatment and its benefit was explained to the patient. A short explanation about possible improvements and adverse effects of the treatment simultaneously explained. An informed written consent was also obtained from the patient. The study was carried out in the ICU as per the patient's admission and condition.

Outcome Measures i.e. PFT was assessed by Hand-Held Spirometry (RMS Helios 401) and Sputum Volume was collected in the funnel tube assessed on Day 1 and Day 14. The patient was taught how to perform the Lung Flute Device.

2.4 Procedure

While performing the Lung Flute Device, the patient was in a relaxed sitting position, head slightly tilted downwards. The patient was then asked to hold the Lung Flute pointing down, inhale a little deeper than normal, place the lips completely around the mouthpiece, and gently blow out through the Lung Flute. Next, the patient was asked to remove the mouthpiece from the mouth, quickly inhale again, put the mouthpiece back in the mouth and blow gently again. The patient was asked to perform the same cycle for 2-3 times and then the patient was asked to cough out. The intervention was given twice a day/3 days in a week for a period of 2 weeks for 15-30 mins.

2.5 Data analysis and results

After 2 weeks of intervention, there was a significant improvement in the pulmonary components and the sputum volume.

Table 1: Represents the Pulmonary Function Tests values

		PRE	POST
FVC	LITRES	1.4	1.7
	PRED %	58	64
FEV ₁	LITRES	1.38	1.68
	PRED %	60	66
PEFR	LITRES	3.42	3.50
	PRED %	48	56

After 2 weeks of intervention, sputum volume on Day 1 was 7.5 ml and that on Day 14 was 5 ml which shows significant improvement in the sputum volume.

3. Discussion

This is the first case report that highlights the use of Lung Flute Device in Miliary Tuberculosis patient to find out the efficacy of the easy use device in expectorating secretions in Tuberculosis. This is a new device and is not known because of few literature available on it.

A study was carried out in Tokyo, Japan by Akira Fujita, Kengo Murata and Mikio Takamori on Novel method for sputum induction using the lung flute in patients with suspected pulmonary tuberculosis which was a preliminary trial to evaluate the usefulness of the Lung Flute for sputum sampling in patients suspected of pulmonary tuberculosis. Thirty-four patients were enrolled in the study. The patients were taught to perform the Lung Flute Device as described above in the procedure. The patients in the study reported that device was user friendly and expectorated more sputum. Hence, the application of the Lung Flute may represent a promising technique for the rapid diagnosis of pulmonary TB.[7]

An eight-week, randomized, controlled, two arm parallel study on Comparison of the Lung Flute with the Acapella in the Treatment of COPD with Chronic Bronchitis was powered to demonstrate equivalency of the new device, the Lung Flute, to the predicate device, the Acapella by Sanjay Sethi *et al*, stated that the Lung Flute and Acapella were both well tolerated and demonstrates that OPEP devices are of potential benefit in COPD patients with mucus hypersecretion. The Lung Flute is a safe and effective OPEP treatment for mucus hypersecretion in COPD and is equivalent to the Acapella.[8]

4. Conclusion

In the present case report, the easy to use Lung Flute Device was found to be very effective in mucus clearance. In addition, this innovative device can also be used in other respiratory conditions for secretion clearance. Therefore, the study concludes that Lung Flute is efficient device for mucociliary clearance and should be added in the bronchial

hygiene therapy regime to prevent pulmonary complications and improve the Quality of life of the patient.

Limitation of study

- (1) It was difficult for the patient to perform Pulmonary Function Test.
- (2) Sterilization procedure for the Lung Flute Device was at times difficult.
- (3) It was difficult to make device available in India for the study.

Suggestion for future research

- (1) Further studies can be carried out in large sample size
- (2) To study the effect of Lung Flute Device in other mucus secreting conditions (Cardiac, Renal and Postoperative)

References

- [1]. Terry Des Jardins, George G. Burton. Clinical Manifestations and assessment of Respiratory Disease. Seventh Editon, pg no 273-282
- [2]. Sahn SA, Neff TA. Miliary tuberculosis. *The American Journal of Medicine*. 1974 Apr 1; 56(4):495-505.
- [3]. Kim JH, Langston AA, Gallis HA. Miliary tuberculosis: epidemiology, clinical manifestations, diagnosis, and outcome. *Reviews of infectious diseases*. 1990 Jul 1; 12(4):583-90.
- [4]. Andreu J, Caceres J, Pallisa E, Martinez-Rodriguez M. Radiological manifestations of pulmonary tuberculosis. *European Journal of Radiology*. 2004 Aug 1; 51(2): 139-49.
- [5]. Proudfoot AT, Akhtar AJ, Douglas AC, Horne NW. Miliary tuberculosis in adults. *Br Med J*. 1969 May 3; 2(5652):273-6.
- [6]. Michael Donahue. "Spare The Cough Spoil The Airways: Back To The Basics In Airway Clearance". *Pediatric Nursing/ March-April-2002/Vol.28/No 2*.pg no-107-111
- [7]. Fujita A, Murata K, Takamori M. Novel method for sputum induction using the Lung Flute in patients with suspected pulmonary tuberculosis. *Respirology*. 2009 Aug; 14(6):899-902.
- [8]. Sethi S, Maloney J, Grove L, Anderson P. Comparison of the lung flute with the acapella in the treatment of COPD with chronic bronchitis. Unpublished data. 2018.