

Case Report

Spontaneous rupture of a calculous pyonephrotic kidney into the retroperitoneal cavity presenting as psoas abscess - A Case Report

Vijaya Patil, Ravi Ichalakaranji*, S.B. Patil, Ravi Pattar and Ashrith I. M

B M Patil Medical College & Hospital, Bijapur, India

***Correspondence Info:**

Dr. Ravi Ichalkaranji
B M Patil Medical College & Hospital, Bijapur, India
E-mail: ravi.ichalkaranji@gmail.com

Abstract

Psoas abscess due to spontaneous rupture of Calculouspyonephrosis is an extremely rare complication of pyonephrosis. Renal stones and, much less commonly, neoplasms may also cause rupture¹. Here we are presenting a rare case of Calculouspyonephrosis rupturing into left psoas muscle & presenting as oliguria & left psoas abscess with a renal calculi in abscess cavity.

Keywords: Calculouspyonephrosis, Psoas abscess, hydroureteronephrosis.

1. Introduction

Psoas abscess due to spontaneous rupture of Calculouspyonephrosis is an extremely rare complication of pyonephrosis. Renal stones and, much less commonly, neoplasms may also cause rupture¹. We are presenting a rare case of Calculouspyonephrosis rupturing into left psoas muscle & presenting as oliguria & left psoas abscess with a renal calculi in abscess cavity.

2. Case Report

A 70 year old man presented with pain in the left loin radiating to left thigh, low back ache, limping, puffiness of face, swelling of both lower limbs for last 10 days, and oliguria. On examination, patient was febrile, had bilateral pedal oedema, with fullness and tenderness in left flank, fixed-flexion deformity of left lower limb. Investigations revealed leukocytosis and raised ESR. USG abdomen revealed Hypochoic lesion measuring 11.5 x 4.5 cms in the psoas muscle with calcification with mild left hydronephrosis.

CT scan of abdomen and pelvis (plain) (Fig : 1) revealed: Large soft tissue density collection (29 x 33 mm) along the left psoas muscle, extending from lower margin of D12 to S1 with large calcified focus (18 x 11 mm) within the collection -? Psoas abscess with Small communication between the collection & pelvis of the left kidney with moderate hydroureteronephrosis with perinephric fat stranding – ruptured pyonephrosis. The patient was explored with left lumbar incision which revealed a psoas abscess with calculus lying free in abscess cavity (fig: 2). The left kidney had abundance of pus which leaked through a small perforation in the lower pole (fig: 3). Drainage of left psoas abscess with removal of calculi and left nephrostomy with foley’s catheter was inserted (fig: 4). Unfortunately patient deteriorated & expired of renal insufficiency & septicemia on POD 14.

Fig 1 : Calculi which was lying in Abscess cavity

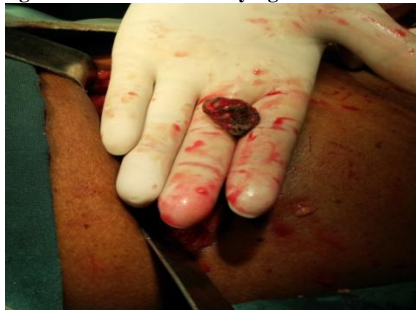

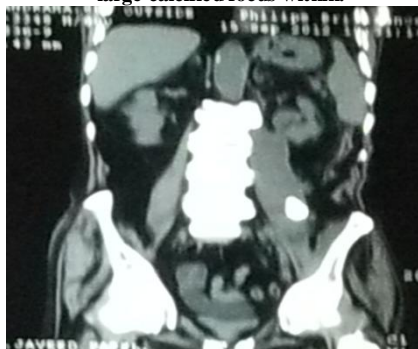
Fig 3: left nephrostomy with Foley’s catheter

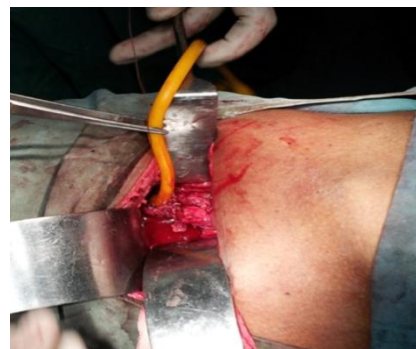

Fig 2: perforation in lower pole of kidney

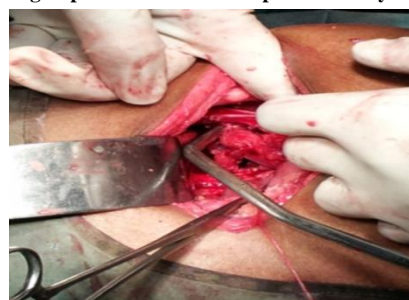

Fig 4: CT scan – collection along left psoas muscle with large calcified focus within.



3. Discussion

Iliopsoas abscess is a collection of pus in the iliopsoas compartment². Psoas abscess may be primary or secondary³. Incidence is about 12 cases per year⁴.

The classical clinical triad of fever, back pain & limp is present in only 30% of the patients. USG reveals psoas abscess in only 60 % cases as compared to 80 – 100 % for CT scan⁶. Management involves the use of appropriate antibiotics along with the drainage of the abscess through image guided percutaneous drainage or surgical drainage.. Till date, 7 cases of spontaneous rupture of pyonephrosis in patients with urolithiasis has been reported. 2 cases of xantho granulomatous pyonephrosis with psoas abscess have been reported. About 17 cases of peritonitis due to rupture of pyonephrosis has been reported. However, spontaneous rupture of a pyonephrotic kidney into the retro peritoneal cavity presenting as a psoas abscess with calculi lying in the abscess cavity has not been reported till date. And the treatment for ruptured pyonephrosis is nephrectomy or nephrostomy and drainage of psoas abscess.

4. Conclusion

Retroperitoneal rupture of a pyonephrosis is a rare event which requires immediate intervention. The abdominal symptoms sometimes mask the underlying renal cause. One should keep in mind about renal pathology though rare can present as psoas abscess. CT scan and subsequent definitive procedure for renal pathology along with psoas abscess drainage is required.

References

1. Glen ES. Spontaneous intraperitoneal rupture of hydronephrosis. *British Journal of Urology*.1969; 14:414-16.
2. Mynter H. Acute pyelitis. *Buffalo Med Surg J*.1881; 21:202-10.
3. L. DI Marco, V. Sciascia, R. Salmi, A. Manfredini, C. Cocuzza, M. Berghenti et al. Psoas abscess ten years after ipsilateral nephrectomy for pyonephrosis. *G Chir* 2007; 28(4): 139-141.
4. Garner J.P, Meiring P.D, Ravi K. Psoas abscess not as rare as we think? *Colorectal Dis*. 2007 Mar; 9(3):269-74.
5. Chern CH, Hu SC, Kao WF, et al. Psoas Abscess : making an early diagnosis in the ED. *Am J Emerg Med* 1997 : 15: 83-8
6. Mohammed Nabil, YM Riyad, Mohammed Al Salem, Ali Nur. Pyogenic Psoas Abscess: discussion of epidemiology, etiology, bacteriology, diagnosis, treatment and prognosis. *Kuwait Medical Journal* 2003, 35(1): 44-47