

## Unplanned complex suicide by Self-Cutting and Drowning: A Case Report

Sachin Chourasia<sup>1</sup>, Ravi Rautji<sup>2</sup>, Janender Baghel<sup>3</sup>, Sarala M<sup>1</sup> and K V Radhakrishna<sup>4</sup>

<sup>1</sup>Assistant Professor, Department of Forensic Medicine & Toxicology, AFMC, Pune, India

<sup>2</sup>Professor & Head of the Department, Department of Forensic Medicine & Toxicology, AFMC, Pune, India

<sup>3</sup>Postgraduate Resident, Department of Forensic Medicine & Toxicology, AFMC, Pune, India

<sup>4</sup>Associate Professor, Department of Forensic Medicine & Toxicology, AFMC, Pune, India

### Abstract

Many precious lives are lost every year by self-destruction or suicide making it a significant public health problem globally. Complex suicides are committed by using more than one method. In complex suicides, two or more methods are applied either simultaneously or one after the other. Usually two or more methods are applied simultaneously or one after the other in order to make sure that death will occur even if one method fails. There are a great number of complex suicides in the literature. It is so interesting to expand the list and to publish more cases of complex suicide which are examined by forensic worldwide. We present a case of a unplanned complex suicide by a man who used two methods not simultaneously but one after the other, first wrist cutting and then drowning for committing suicide. Drowning was probably used when the first method has failed after waiting for two hours. Forensic autopsy and death scene examination confirmed the circumstances of the case. In questionable suicides, the presence of different modes of traumatization or a combination of potentially fatal mechanisms may raise the suspicion of homicide. A careful inspection of the scene and a full autopsy are necessary to elucidate the correct manner and cause of death in such cases. This case illustrates an example of such a case.

**Keywords:** Complex suicide; Self-Cutting; Drowning; Autopsy; Death Scene examination.

#### \*Correspondence Info:

Dr. Janender Baghel  
Postgraduate Resident,  
Department of Forensic Medicine & Toxicology,  
AFMC, Pune, India

#### \*Article History:

**Received:** 26/01/2019

**Revised:** 09/02/2019

**Accepted:** 09/02/2019

**DOI:** <https://doi.org/10.7439/ijbar.v10i2.5061>

#### QR Code



**How to cite:** Chourasia S, Rautji R, Baghel J, Sarala M and Radhakrishna K V. Unplanned complex suicide by Self-Cutting and Drowning: A Case Report. *International Journal of Biomedical and Advance Research* 2019; 10(2): e5061. Doi: 10.7439/ijbar.v10i2.5061 Available from: <https://ssjournals.com/index.php/ijbar/article/view/5061>

Copyright (c) 2019 International Journal of Biomedical and Advance Research. This work is licensed under a [Creative Commons Attribution 4.0 International License](https://creativecommons.org/licenses/by/4.0/)

### 1. Introduction

Suicide is a major cause of death in the present world. According to Durham, the French biologist, suicide is death resulting directly or indirectly from a positive or negative act of the victim himself, which he knows will produce this result.[1] In 1974, Marcinkowski had proposed a general division of suicide.[2] In this classification, suicides are first divided into simple versus complex, the complex one referring to suicide by a combination of more than one method. Complex suicides are then further classified as planned or unplanned. The term “planned complex suicide” stands for the combination of more than one method of suicide previously planned to prevent failure of the first method and ensure a fatal outcome.[3-6] On the other hand, an unplanned complex suicide represents a case where the failure of the first method used brings the victim to subsequently come up with an alternative method of

inflicting death[7-8]. In the forensic literature, very few cases of unusual suicides have been reported as complex suicide.[9]

We present a case of a Unplanned complex suicide by a man who used two methods not simultaneously but one after the other, first wrist cutting and then drowning for committing suicide. Drowning was probably used after waiting for two hours when the first method has failed. Medico legal autopsy and death scene examination confirmed the circumstances of the case. In questionable suicides, the presence of different modes of traumatization or a combination of potentially fatal mechanisms may raise the suspicion of homicide. A careful inspection of the scene and a full autopsy helped in this case to elucidate the correct manner and cause of death and it goes a long way in assisting police in closing a case.

## 2. Case Report

The deceased was a 47-year-old married man who was unemployed and staying away from his family in a single rented room. He was a regular drinker, smoker and his financial condition was not good. As per his son he had borrowed money from many individuals and was unable to pay them on time. Also he use to be depressed, was not interacting much with family, friend and was staying alone. His body was discovered by a bystander submerged in a canal near his house who informed the police.

### 2.1 Scene Findings and Chain of Events

The house of the deceased was examined by the police once the body was recovered. The scene of investigation revealed three suicide notes found lying on the bed, describing about his poor financial situation and money borrowed from various sources. The suicide note also mentioned that his family members should not be troubled as they in no way are responsible for his death. As per the suicide note after cutting his wrist he waited for two after which he went out. A kitchen knife was present at the scene with blood stains on it and blood was splattered across the floor. Investigation in the nearby area of the canal lead to the recovery of a pair of sleepers and a scooter parked at the site of the canal. Blood stains were found on the left handle of scooter. The body was discovered with the clothing and his wallet which included his identity card and later it was identified by his wife and son. Blood grouping of the stains collected from the floor of the house, knife, handle of the scooter matched with that of the deceased. From the inquest papers, scene visit and autopsy finding it was clear that the deceased on the fateful day due to financial stress first tried to commit suicide by cutting his

wrist. However when he did not get the desired outcome after waiting for two hours in his room he took his scooter and went to a nearby canal and after parking the scooter near it jumped into the canal.

### 2.2 Autopsy Findings

#### 2.2.1 External Examination


The deceased was averagely built. The body was in advanced stage of decomposition however his facial features were intact which helped in identification. Blackish green discoloration was present over the face, neck, chest, abdomen and back, both upper and lower limbs with multiple blisters over shoulder and elbow joints. Frothy fluid was emerging out from the mouth and nostrils. Loosening of scalp, pubic and axillary hairs were noted. Skin slippage was present over both upper, lower limbs and over the chest and abdomen. Penis and scrotum were swollen. Both palms and soles were saddened and wrinkled. Mud and sand particles were present over the chest and both upper limbs. Multiple aquatic animal bites were seen over the face, ears, both upper and lower limbs.

A spindle shaped incised wound of size measuring 5cm X 2cm X muscle deep present over the flexor surface of left wrist. The margins were regular and surrounded with hematoma.

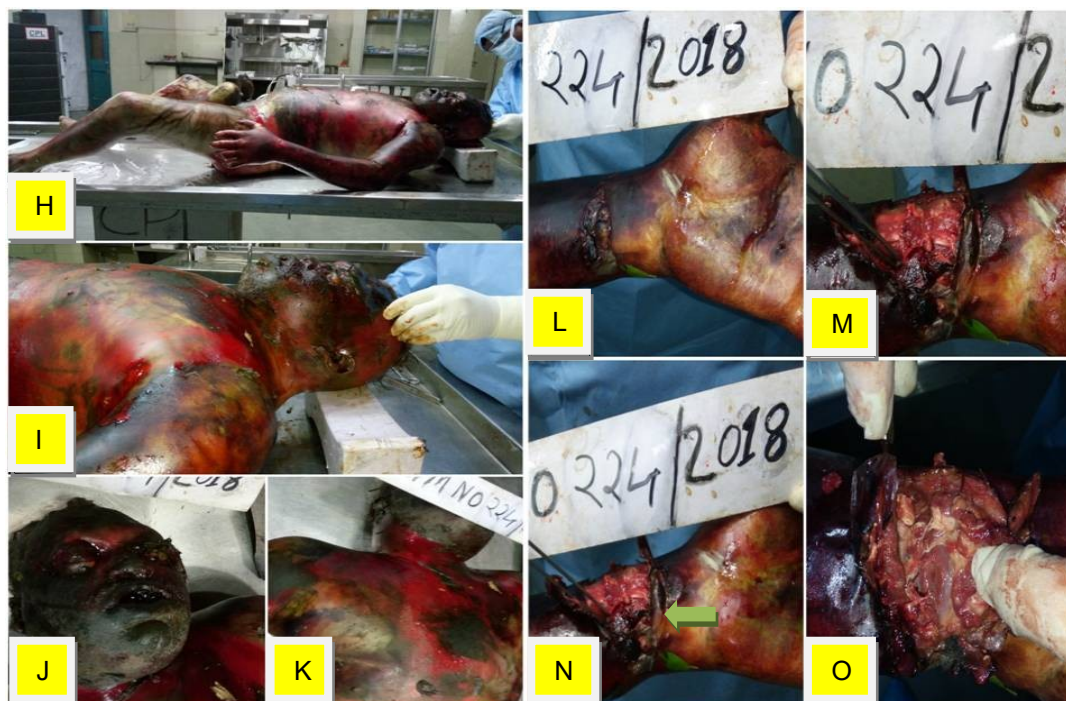
#### 2.2.2 Internal Examination

Findings of the internal examination were consistent with that of advance stage of decomposition and ante mortem drowning. There were no injuries to the other organs and major blood vessels. Toxicological analyses for alcohol and other poisons were negative. The direct cause of death was attributed to drowning.

Figures: A - O



**Figure A, B & C:** Three suicide notes recovered from his House; **D:** Kitchen knife which was lying at door step of the room.; **E:** Knife (Orange arrow), Blood stains over the floor (Red arrow), suicide note lying on the bed (Yellow arrow).; **F:** Sleepers found at the scene of crime near edge of the canal (Black arrow).; **G:** Blood stains found on the left handle of the scooter (Red arrow).



**H:** Body in advanced stage of decomposition; **I:** Aquatic animal bite marks were seen over the face, ear, both upper and lower limbs. **J:** Tongue protruded between the teeth and lips were swollen; **K:** Peeling of skin seen over the chest and abdomen. **L:** Spindle shaped Incised wound over the flexor aspect of left wrist. **M:** On dissection, hematoma seen present over flexor Muscles; **N:** Grass and leaves found above the incised wound (Green arrow); **O:** On dissection, No hematoma found beneath muscles. Artery, veins and components of carpal tunnel were intact

### 3. Discussion

Worldwide, about 2% of deaths are attributed to suicide.[10] According to the National Crime Report Bureau (NCRB) report, 2014, more than one lakh people die every year due to suicide in India.[11] The definition of complex suicide as the use of more than one method to induce death has been widely accepted in the forensic literature.[9] In the forensic literature, complex suicides have been reported to account for about 1.5–5.0% of all suicides.[12] Generally, there is a gradation in the use of the different method. In fact, the victim prefers to start with the least lethal and the less painful method before choosing a more serious approach to have less chance to escape death.[13]

In our case, the victim had cut his wrist following which he jumped into a canal to drown himself. The conversion from lesser to greater methods of lethality is most likely associated with pain, anguish, frustration experienced by the suicidal individual and in order to guarantee and/or accelerate death the second method is used.[14] Blanco-Pampin *et al* and Danto *et al* had reported cases of planned complex suicides employing multiple methods in a single episode with a progressive conversion from lesser to greater lethal method.[15-16]

Previous case presentations in the literature together with our case report suggest that the victims of Unplanned complex suicide were middle-aged and there is a male sex predominance.[17] In some victims, various types of psychiatric disorders such as personality change, schizophrenia and depression could be revealed in the IJBAR (2019) 10 (2)

histories as was evident from our case who was in depression as per history of his relatives.[18] The suicide notes commonly are found in suicidal cases but not always got along together. A study showed that the farewell notes to survivors were found in only 18% of all sharp force suicides.[19]

In the presented case, the scene investigation was one of the most important items to create the sequence of events and the weapon which was recovered was consistent with wounds morphology over the wrist of the deceased.

### 4. Conclusion

Suicide is a delicate medico legal situation. The case supports the literature that; although the cause of death may appear clear at autopsy in cases of self-destruction by multiple highly lethal methods during a single episode, scene investigations is important for the forensic pathologist to understand the whole story of the case and determine the manner and actual cause of death. Scene investigation and autopsy is emphasized as part of the whole postmortem investigation of death in cases of unusual suicide using multiple methods of self destruction.

**Declaration of conflicting interests:** None

### References

- [1]. Behera A, Balabantray JK, Nayak SR. Review of Suicidal cases, A Retrospective study. *J Ind Acad Forensic Med.* 2005; 27 (2): 100-102.

- [2]. Marcinkowski T, Pukacka-Sokolowska L, Wojciechowski T. Planned complex suicide. *Forensic Sci* 1974; 3(1): 95–100.
- [3]. Bohnert M. Complex suicides. In: Tsokos M, editor. *Forensic pathology reviews*, Vol. 2. Totowa, NJ: Humana Press Inc, 2005:127–43.
- [4]. Blanco-Pampin JM, Suarez-Penaranda JM, Rico-Boquete R, Concheiro- Carro L. Planned complex suicide. An unusual suicide by hanging and gunshot. *Am J Forensic Med Pathol* 1997; 18(1):104–6.
- [5]. Cingolani M, Tsakri D. Planned complex suicide: report of three cases. *Am J Forensic Med Pathol* 2000; 21(3):255–60.
- [6]. Padosch SA, Schmidt PH, Madea B. Planned complex suicide by self- poisoning and a manipulated blank revolver: remarkable findings due to multiple gunshot wounds and self-made wooden projectiles. *J Forensic Sci* 2003; 48(6):1371–8.
- [7]. Bohnert M, Pollak S. Kombinierte Suizide eine Literaturübersicht. *Arch Kriminol* 2004; 213(5–6):138–53.
- [8]. Turk EE, Anders S, Tsokos M. Planned complex suicide. Report of two autopsy cases of suicidal shot injury and subsequent self-immolation. *Forensic Sci Int* 2004; 139(1):35–8.
- [9]. Taff ML, Boglioli LR, Danto BL. Planned complex suicide. *Am J Forensic Med Pathol* 1998; 19(2):194.
- [10]. Meier RF, Clinard MB. *Sociology of Deviant Behaviour*. 14<sup>th</sup> ed. Belmont, CA: Wadsworth Cengage Learning; 2008. p. 169.
- [11]. National Crime Records Bureau. *Accidental Deaths and Suicides in India*. New Delhi: Ministry of Home Affairs, Government of India; 2014.
- [12]. Toro K, Pollak S. Complex suicide versus complicated suicide. *Forensic Sci Inter* 2009; 184: 6–9.
- [13]. Zribi M, Dhoub R, Benamar W, Jammeli K, Feki N, et al. Complex Suicide: Unusual Combination. *J Forensic Med* 2016; 1: 111.
- [14]. M.L. Taff, L.R. Boglioli, B.L. Danto, Planned complex suicide, *Am. J. Forensic Med. Pathol.* 1998; 19: 194.
- [15]. Blanco-Pampin JM, Suarez-Penaranda JM, Rico-Boquete R, Concheiro- Carro L. Planned complex.
- [16]. Steedman DJ. Severity of free-fall injury. *Injury* 1989; 20: 259–261
- [17]. M. Cingolani, D. Tsakri, Planned complex suicide: report of three cases, *Am. J. Forensic Med. Pathol.* 2000; 21: 255–260.
- [18]. E. Lignitz, H. Strauch, Kombiniertes Suizid durch Verbrennen und Sturz aus der Höhe, *Arch. Kriminol.* 1986; 178: 51–53.
- [19]. Karlsson T. Homicidal and suicidal sharp force fatalities in Stockholm, Sweden Orientation of entrance wounds in stabs gives information in the classification. *Forensic Sci Int* 1998; 93: 21–32.