

International Journal of Biomedical and Advance Research

ISSN: 2229-3809 (Online); 2455-0558 (Print)

Journal DOI: <https://doi.org/10.7439/ijbar>

CODEN: IJBABN

Original Research Article

Experience of surgical treatment of post-burn oral commissural contracture (Microstomia)

Sudhir S. Karmarkar and Kundankumar N. Dandekar*

SMBT Institute of Medical Sciences and Research Centre, Dhamangaon, Dist- Nashik, PIN 422403 Maharashtra, India

QR Code

***Correspondence Info:**

Dr. Kundankumar N. Dandekar

Professor,

Department of Surgery,

SMBT Institute of Medical Sciences and Research Centre,

Dhamangaon, Dist- Nashik, PIN 422403 Maharashtra, India

Article History:*Received:** 29/08/2017**Revised:** 11/09/2017**Accepted:** 13/09/2017**DOI:** <https://doi.org/10.7439/ijbar.v8i9.4362>**Abstract****Introduction:** One of the significant problems of facial burns is post burn oral commissural contracture (Microstomia) occurring as a result of circumferential scarring at the junction between the lips and cheek. It results in aesthetic disfigurement of face and functional impairments like feeding, speech and oral hygiene and difficulty of intubation.**Objective:** This study aims to share the experience of treatment of microstomia with various methods.**Methods:** This study comprised of 7 cases of microstomia of variable severity over a period of 10 years. Case number 1, 2 and 3, having severe microstomia, were treated with Converse' method of commissuroplasty without waiting for scar maturation. Case number 4 and 5 had moderate severity microstomia, in these patients the correction of the neck contracture was considered as priority and were treated with release of neck contracture and split skin grafting. Case number 6 and 7 had pressing priority of treatment of ectropion which was treated first but unfortunately further the treatment of microstomia was given back seat by the patients.**Results:** Case number 1 to 5 treated operatively showed significant improvement in mouth opening while case number 6 and 7 who rejected treatment, showed no improvement.**Conclusion:** Post burn microstomia is infrequent yet important functional condition causing difficulty for feeding and for intubation during anesthesia and hence its correction falls under essential procedure to be done earliest without waiting for scar maturation. Cases which were treated operatively showed significant improvement in mouth opening. In cases that rejected treatment, hence considered as conservatively treated, the results were inferior.**Keywords:** Microstomia, Oral Commissural Contracture, Post Burn Microstomia.**1. Introduction**

Deep facial burns of different etiology often affect patients' outcome and quality of life in a dramatic fashion because of the variety of the resultant deformities. One of the significant problems of facial burns is post burn oral commissural contracture (microstomia) which occurs as a result of circumferential scarring at the junction between the lips and cheek. It results in aesthetic disfigurement of face and functional impairments like feeding, speech and oral hygiene and difficulty of intubation during anesthesia. This study aims to share the experience of treatment of microstomia with various methods.

2. Material and methods

This study comprised of 7 treated cases of microstomia of variable severity over a period of 10 years. All these patients also had associated post burn facial deformities like neck contractures, ectropion etc. The primary information of age, sex, marital status, type of injury and intension, duration of injury at the time of presentation, treatment details and the other associated deformities were recorded. The vertical diameter and horizontal diameter of the initial mouth opening was

measured and the severity of microstomia was decided. According to severity of microstomia and associated facial deformity, priority the operative procedure of correction of microstomia or of other deformity was decided.

According to the severity of microstomia as decided by the initial measurements of mouth openings and the treatment given, these 7 patients were divided into three groups. A, B and C.

Group A [Case number 1, 2 and 3] had severe microstomia (mouth opening less than 24mm) with severe disability of feeding and oral hygiene. In these three cases, microstomia was treated with priority by Converse method of bilateral commissuroplasty without waiting for scar maturation.

Group B [Case number 4 and 5] of microstomia had moderate severity (mouth opening between 25 to 35 mm) as compared to the first three cases and the mouth opening was additionally compromised due to presence of severe neck contracture. The correction the neck contracture was considered as of top priority over microstomia and was treated with release of neck contracture and split skin grafting.

Group C [Case number 6 and 7] had of microstomia of less severe variety but had overwhelming primary problem of ectropion endangering their vision. Priority treatment was focused on ectropion correction by release and skin grafting initially and unfortunately later the treatment of microstomia was given back seat by the patient. Thus these two patients for records purpose were placed under heading of conservative treatment of microstomia.

The vertical diameter and horizontal diameter of the mouth opening was measured and was noted postoperatively during their follow-up visits.

Patients in this study had minimal follow-up for 6weeks and maximum follow-up of 10 yrs.

2.1 Case 1

Twenty four years, unmarried male patient with history of suicidal facial and neck deep dermal flame burns, was seen 6 weeks after burns with difficulty in feeding, facial expression, speech and oral hygiene. There was a bilateral perioral severe scar contracture in the region of both the oral commissures with normal mobility of the tongue. Intraoral examination was difficult to perform because of the limited mouth opening (22mm in vertical direction, 25 mm in horizontal). To overcome the difficulty of food intake, facial expression and speech along with problems of oral hygiene due to severe microstomia, its surgical correction was done on priority basis without waiting for scar maturation with Converse method of bilateral commissuroplasty under local anesthesia.

Post operative results after 6 weeks showed significant improvement in feeding, speech and mouth opening. (Post operative mouth opening of 54mm in the vertical direction and 54 mm in the horizontal direction). (Figure 1 and 2)

Figure 1: Case 1 preoperative photo

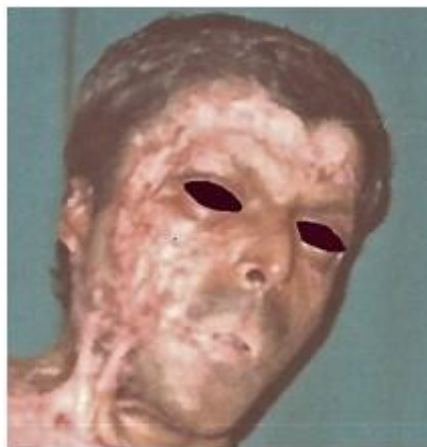
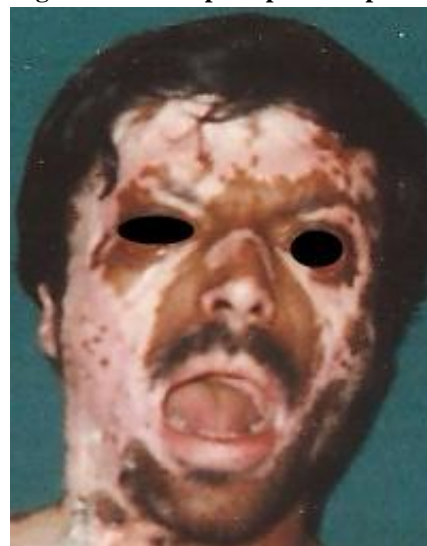
Figure 2: Case 1 postoperative photo



2.2 Case 2

Twenty six years old, married male patient with history of facial and neck suicidal deep dermal flame burns was seen 8weeks after burns. There was a microstomia with severe scar contracture in the region of both the oral commissures, with perioral bilateral fibrosis, difficulty of facial expression and feeding. He also had associated severe neck contracture and ectropion of both eyelids but not severe enough to endanger the vision. Mouth opening was 20 mm in vertical and 30 mm in horizontal direction. There was normal mobility of the tongue.

Surgical correction of microstomia with Converse bilateral commissuroplasty was done on priority, without waiting for scar maturation, under local anesthesia. Six

weeks later the results were recorded in the form of improvement in mouth opening of 54mm in the vertical direction and 60 mm in the horizontal direction. Patient also came for late follow up .Improvement in the mouth openings were consistent in the 10 years late follow up photos.

Figure 3: Case 2 preoperative photo

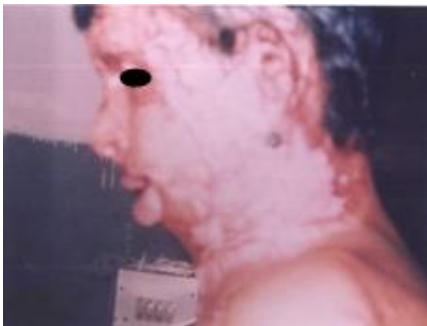
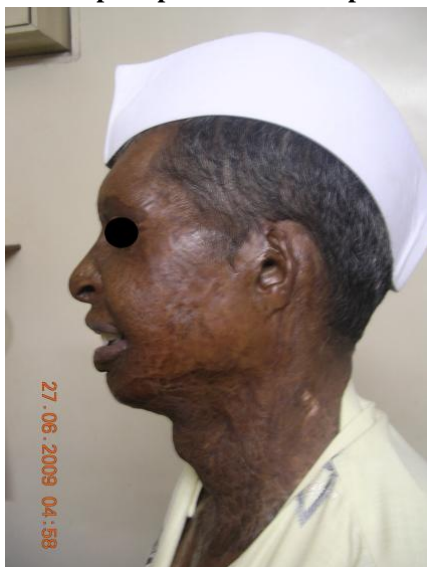
Figure 4: Case 2 postoperative follow up after 10 years



2.3 Case 3

Thirty years married male with history of deep third degree homicidal chemical burns due to concentrated sulfuric acid leading to severe contractures of face, neck, axilla and left upper extremity was seen 12 weeks after burns. Patient had developed severe microstomia and loss of vision. There was a severe scar contracture in the region of both the oral commissures, with perioral bilateral fibrosis. His whole jaw was sort of locked with limited mouth opening (18mm vertical direction and 90 mm in horizontal direction.) Since he had already lost vision, release of severe microstomia was treated with priority with Converse bilateral commussiroplasty under local anesthesia. Six weeks later he showed mouth opening of 50mm in the vertical direction and 97mm in horizontal direction. (Figure 5 and 6)

Figure 5: Case 3 preoperative photo

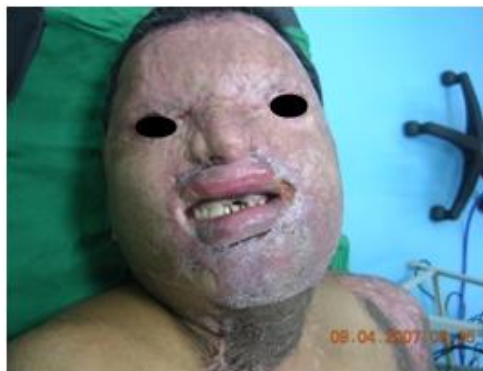
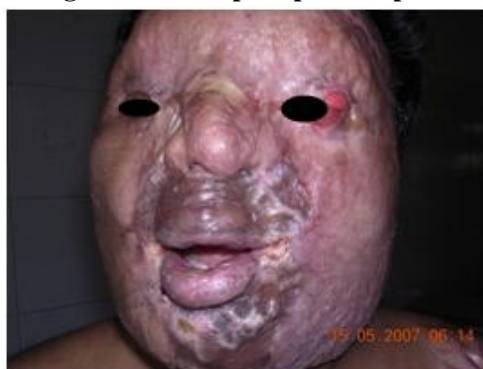
Figure 6: Case 3 postoperative photo

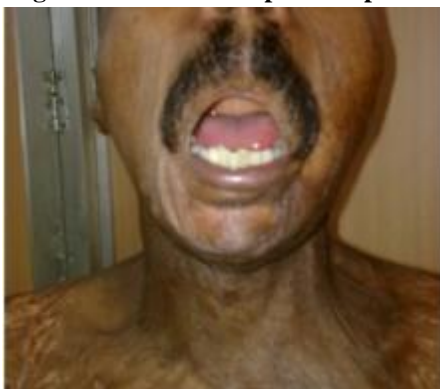


2.4 Case 4

Twenty years unmarried male with suicidal thermal burns was referred in the 6th post burn week with microstomia along with severe mentosternal neck contracture. His initial mouth opening was 32mm vertically and 78mm horizontally. Here the microstomia was aggravated by mentosternal neck contracture. He was operated with priority for mentosternal contracture release and grafting. He responded with vertical mouth opening of 53 mm and horizontal opening 82mm. (Fig 7 and 8)

Figure 7: Case 4 Preoperative photo

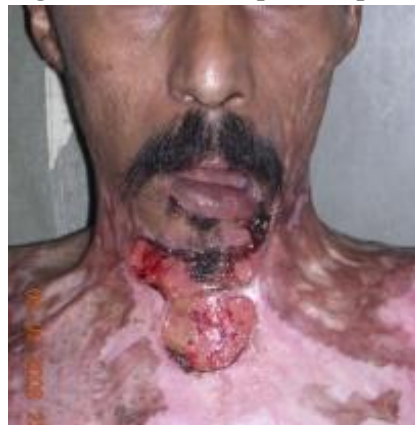

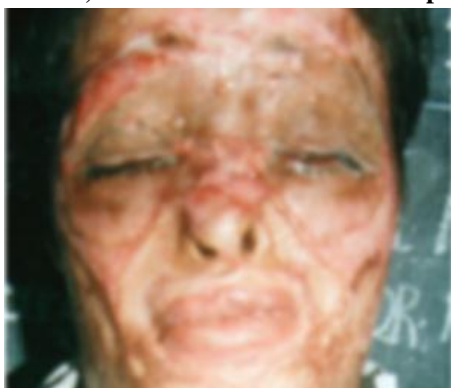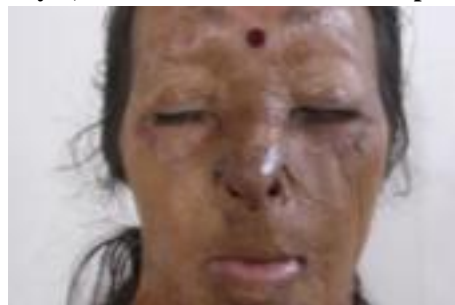Figure 8: Case 4 Postoperative photo**2.5 Case 5**

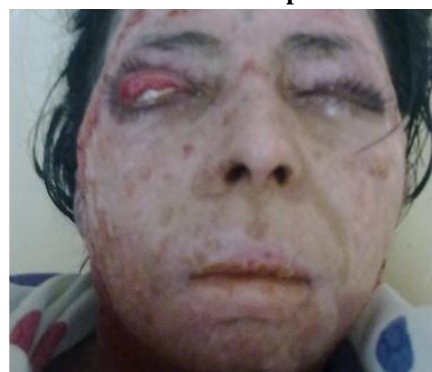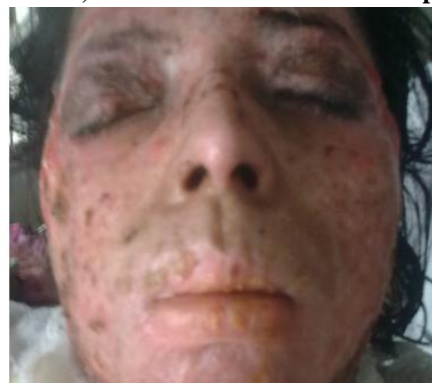Eighteen years, married male with history of suicidal thermal burns referred in the 6th post burn week, with microstomia and a severe post burn mentosternal neck contracture. Initial vertical mouth opening was 32mm and horizontally 50mm. He was operated for release of mentosternal contracture immediately. The post operative mouth opening was 36mm vertical and 54mm horizontal.

2.6 Case 6

Twenty four years old married female, suicidal thermal burns was referred in the second post burn week with microstomia (mouth opening was 30 mm vertically and 67 mm horizontally). She also had severe bilateral ectropion of both eyes exposing cornea with impending endangerment of vision. Her ectropion was operated as priority. Patient was offered correction of microstomia, but she did not avail the correction of microstomia. She incidentally reported some ten years later with mouth opening of 35 and 73 mm respectively with which she was satisfied or had compromised. (Figure 9 and 10)

Figure 9: Case 6 Ectropion corrected, immediate post operative, Microstomia treatment not opted**Figure 10: Case 6 Ectropion corrected, follow up after 10 yrs, Microstomia treatment not opted****2.7 Case 7**

Twenty five years married female, with history of suicidal thermal flame burns was referred in the second post burn week with microstomia. She had associated severe ectropion of upper eyelids endangering the vision which was operated in priority. Pre op mouth opening was 32mm vertically and 67mm horizontally. Patient was offered correction of microstomia but she did not comply. She continued her follow up and conservative management. Post operatively mouth opening was 34 and 83mm respectively. (Figure 11 and 12)

Figure 11: Case 7 Preoperative photo, Microstomia treatment not opted**Figure 12: Case 7 Post operative photo, Ectropion corrected, Microstomia treatment not opted**

3. Observations and Results

1) Sex distribution (5 Males to 2 females) 2) Age distribution -Average age of male patients was 23.20 yrs, Average Age of female was 24.5. 3) Mode of injury: Flame burns 6 cases, chemical burn 1 case. Intension wise i.e., suicidal etiology 6 cases, acid vitriolage 1 case. 4) Average time of surgical intervention after incidence of burns in group A = 8.6 weeks, group B =6 weeks, i.e. average time in A+B = 7.3 weeks. 4) Measurements of mouth openings, preoperative and postoperative are recorded in Table No.1

Table 1: Measurements of mouth openings

Case No.	Pre-op vertical opening in mm	Pre-op horizontal opening in mm	Post -op vertical opening in mm	Post- op horizontal opening in mm
1	22	25	54	54
2	20	30	54	60
3	18	90	40	97
4	32	78	54	82
5	32	50	50	54
6	30	67	35	73
7	32	67	34	83

In group A (case no 1,2 and 3.) Average preoperative vertical mouth opening was 20 mm. This was definitely less than 24mm, the lower limit of functional range, thus severely limiting the daily life activities [1]. After bilateral Converse commisuroplasty [2], average vertical mouth opening was 49.3mm.

Thus with the operative treatment there was a significant improvement in the mouth opening from severely impaired range of 16mm to 49.3 mm i.e. reaching the highest upper limit of normal physiological range[1,2] . Individually postoperative results were better in case no 1 and 2 (thermal burns) as compared case no 3 which was due to chemical burn.

In Group B (Case no 4 and 5) Initial average mouth opening was 32mm. It was less than normal physiological range, but it was in range what is called as still functional (25-35mm) [1]. The priority correction was for severe mentosternal neck contracture. After correction of neck contracture, the microstomia was improved allowing the mouth opening of average 52 mm which is average opening with acceptable and significant functional improvement.

In Group C (Case no 6 and 7) Average initial mouth opening was 31 mm. After conservative or no treatment with help of oral exercises the average mouth opening was 34.5mm indicating no significant improvement in mouth opening.

4. Discussion

Timo [1] has given the details of degrees of mouth opening in normal individuals as follows: The average

physiological mouth opening measures 40 to 50 mm. An opening of 25 to 35 mm is still functional; while an opening of less than 24 mm is severely limiting in daily life [1,3].

In Post burn Microstomia - a small oral opening occurs as a result of circumferential scarring at the junction between the lips and cheek. It results in aesthetic disfigurement of face, and functional impairments like feeding, speech, oral hygiene and difficulty of intubation for anesthesia [3], hence Microstomia cases, though incidence wise less in number, they pose a great challenge.

Microstomia cases are generally associated with additional post burn facial contractures needing surgical corrections. In patients having multiple contractures, ideally, reconstructive efforts for improved appearance are delayed until scar is matured. The length of time varies between six months and two years, and may even vary in the same patient from one area to another. The reconstructive procedures are analyzed in two different categories in relation to the time of reconstruction, i.e. essential procedures and elective late or non essential procedures [4,5].

In patients having multiple contractures deformities, Gokalan [4] has provided criteria and stated that following three contractures are to be operated with priority (designating as essential procedure), without waiting for scar maturation, as they affect functional goals: 1. severe ectropion of eyelids endangering vision. 2. Severe microstomia causing difficulty in feeding and intubation for anesthesia. 3. Severe mentosternal contractures etc.

Thus, in patients with multiple facial deformities have microstomia of severe variety then its early surgical correction is of the top most priority next to the correction of ectropion of eyelid endangering the vision. In cases having microstomia of less severity, early surgical correction of other associated contractures enlisted as the essential procedures is done with top priority without waiting for scar maturation, and the microstomia is treated as next priority.

Average age of the patients in this study was 23 years. Predominance of young males and females of marriageable or newly married group was seen in this study. Such predominance was also reported by Gokalan [4].

Only seven cases in 10 yrs extended period in this study, points out low incidence of mouth contracture. Similar finding is also reported by other workers [1,2,4].

Severe microstomia due to chemical burns of varied types had been reported by the other workers. Microstomia due to phosphorous chemical had been reported by Gokalan [4] and due to ingestion of caustic soda had been reported by Jaminet [6]. In our study there is only one case of chemical burns and it is due to sulfuric acid vitriolage.

In this study, for severe microstomia early surgical intervention was done on average at post burn 7.3 weeks period. Such early intervention is also reported by Gokalan *et al* [4], and Rawat *et al* [7].

The surgical correction of severe microstomia (case no 1, 2, and 3.) (Mouth opening less than 24mm), was done on priority basis as an essential procedure by Converse bilateral commissuroplasty [2]. There was significant improvement in the vertical mouth opening from severely impaired average. (From 20 mm to 49.3 mm) (This was better than what (from 25 mm to 35 mm) was reported by Mordjikian E [8].

In-group B: Initial average mouth opening was 32mm. It was less than normal physiological range, but it was in range what is called as still functional (25-35mm) [1]. The priority correction was for severe mentosternal neck contracture .After correction the microstomia was improved allowing the mouth opening of average 52 mm which is average opening with acceptable and significant functional improvement. Such improvement noticed by released of mentosternal contractures was due to extrinsic release of contracture forces. Such experience is also reported by other workers.[5,7].

Immediate results of all cases and long term result in this study had showed that there were no complications or necessity of redoing of the surgery.

5. Conclusion

Post burn microstomia is infrequent yet important functional condition causing difficulty for feeding and for intubation for anesthesia and hence its correction falls under essential procedure to be done earliest without waiting for scar maturation.

In cases of microstomia treated conservatively, the results were inferior to that of surgical treatment.

In cases with severe variety, the surgical correction with Converse's method yielded superior results with high patient satisfaction and was found to be safe, easy to

execute under local anesthesia. This early surgery opens the gateway for safe intubation for anesthesia, facilitating early surgical corrections of the associated additional post burn contractures. Correction of severe microstomia is a gratifying operation, worth to be strived for getting the opportunity.

References

- [1]. Kamolz LP, Jeschke M G, Horch R *et al*. Handbook of Burns: Reconstruction and Rehabilitation Vol II. In: Timo A., Spanholtz M.D., Riccardo E. Giunta. Reconstruction of the perioral region after facial burns, Spinger-Verlag/Wien New York 2012: 227-239.
- [2]. Converse J.M. Techniques for the repair of defects of the lips and cheeks. Converse J.M. (Ed): Reconstructive Plastic Surgery, second edition, Philadelphia, Saunders, 1977; 3: 1544-1594.
- [3]. Joseph G. McCarthy, Robert D. Galiano, Sean G. Boutros – 2006 *Current Therapy in Plastic Surgery* - Page 186
- [4]. Gókan L, Özgür F, Mavili E, Gürsu G. Reconstruction of post-burn face deformities. *Annals of Burns and Fire Disasters* 1997; X (2).
- [5]. Arun Goel, Prabhat Shrivastava. Review article: Post-burn scars and scar contractures. *Indian Journal of Plastic Surgery*, 2010; 43(3): 63-71.
- [6]. Jaminet P, Werdin F, Kraus A, Pfau M, Schaller HE, Becker S, Sinis N. Extreme microstomia in an 8-month-old infant: bilateral commissuroplasty using rhomboid buccal mucosa flaps. *Eplasty*. 2009
- [7]. Rawat K V, Dr. Rawat A, Parhar S, Wagh S, Patel V, Moon P. Role of early post burn contracture release: A review of 136 cases. *Indian Journal of Burns* 2011; 19 (01): 3.
- [8]. Mordjikian ET: Severe *microstomia* after chemical burn- Confex https://asps.confex.com/asps/2004am/techprogram/paper_5677.htm