

Case Report

Pelvic kidney and related anomalies - A case report

Jaidev Singh Shekhawat^{*1}, Prema Ram Choudhary², Amit Tyagi³ and M. S. Verma⁴

¹Assistant Professor, Department of Anatomy, C. U. Shah Medical College, Surendranagar (Gujarat).

²Assistant Professor, Department of Physiology, C. U. Shah Medical College, Surendranagar (Gujarat).

³Professor and Head, Department of Biochemistry, C. U. Shah Medical College, Surendranagar (Gujarat).

⁴Ex. Professor and Head, Department of Anatomy, C. U. Shah Medical College, Surendranagar (Gujarat).

* Correspondence Info:

Dr. Jaidev Singh Shekhawat
Assistant Professor,
Department of Anatomy,
C. U. Shah Medical College, Surendranagar (Gujarat), India
E mail: jaygr1976@gmail.com

Abstract

A case of an ectopic kidney of left side was found during routine dissection in the department of anatomy. It was associated with multiple visceral and vascular variations, compensatory hypertrophy of right kidney, and consequential absence of renal impression (on the spleen). The testis is smaller in size placed in the scrotum is high up under the root of the penis. The right testis placed lower than the left testis in the scrotum and enlarges in size. The vascular variations were multiple. An attempt has been made to systematically document these variations and possible explanation for the same on the basis of ontogeny.

Keywords: Left pelvic kidney, compensatory hypertrophy of right kidney, enlarged right testis, renal impression, and renal arteries

1. Introduction

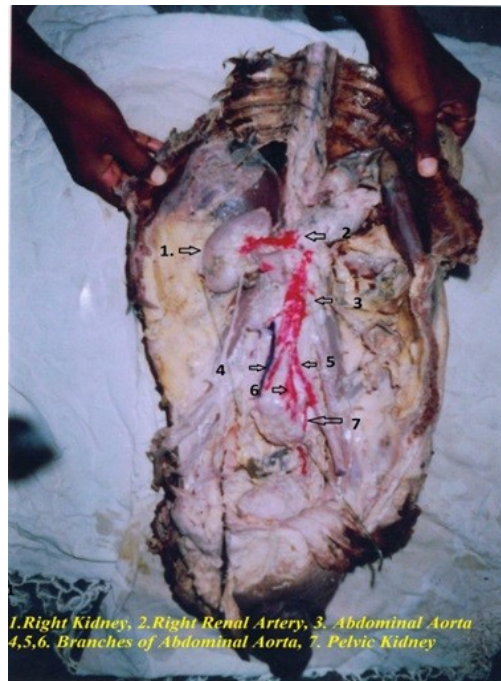
Urinary tract anomalies from a long list; congenital anomalies of the urinary tract are often the underlying cause of pathologies. Most of pathologic conditions of the urinary system are due to these variations, variations may be in the number, position, shape and size or in rotation of the kidney, calices ureter or bladder. Usually these anomalies are associated with anomalies of vertebral column, lower gastrointestinal tract, with 15% of meningocele, myelomeningocele, genital tract, 42% of duplication of colon, and 90% of duplication of genitalia¹. Ectopic kidney has a reported frequency of 1:500 to 1:110; ectopic thoracic kidney, 1:13,000 solitary kidney, 1:1,000; solitary pelvic kidney, 1:22,000; one normal and one pelvic kidney, 1:3,000, and crossed renal ectopia, 1:7, 000. We are reporting a case of pelvic kidney with other anomalies found during the routine dissection in the department of anatomy².

2. Case Study and Observations

A case of unilateral kidney was found during routine dissection in a male cadaver of Indian origin (Fig-1). The right kidney was in normal in position. The left kidney (pelvic kidney) was situated anterior to the bodies of S2, S3 and S4 vertebrae. It was oval in shape and measured 13.5cm vertically, 9.4 cm. transversely and 4.3 cm. Thickness. Its dorsal surface was smooth, ventral surface was marked with hilum and was lobulated, long axis of kidney was more or less in mid line. Lower pole of pelvic kidney was tilted to left side, close to the left lateral wall of the true pelvis and it was very close to the posterior surface of the urinary bladder. Two renal arteries emerge from the ventral aspect of the aorta just 2 cm above

from the bifurcation of the aorta, among two renal arteries, left one approach to the lower pole of the pelvic kidney and divided into three branches (on the ventral surface), remaining artery approach right margin of the kidney. Another renal artery emerged from the lower quadrant of hilum. It was branch of left common iliac artery which lies 2 cm below the bifurcation of aorta. The testis is smaller in size placed in the scrotum is high up under the root of the penis. The right testis placed lower than the left testis in the scrotum and enlarges in size.

Figure-1. Showing case of unilateral kidney a male cadaver of Indian origin



Few other observations were:

- Right kidney was hypertrophied and measured 11.8 cm vertically, 7.2 cm. transversely and 3.8 cm. Thickness.
- Upper pole of pelvic kidney was closed to left common iliac vessels.
- Ventral surface of pelvic kidney was related to the coil of intestine.
- No any renal impression present on the spleen.
- Sigmoid colon and mesocolon shifted to right side.

3. Discussion

An ectopic kidney is classified into an abdominal, lumbar or pelvic kidney based on its location in the posterior abdominal cavity. It is rare in the thoracic and pelvic cavity. Bizarre (2002) reported a case of an ectopic kidney of left side and associated with multiple visceral variations were in the form of mechanical displacement of the sigmoid colon and mesocolon to the right side, compensatory hypertrophy of the right kidney, enlarged uterus and displaced ovary and vascular variations included multiple renal vessels on the both the sides, variations in abdominal aorta, inferior vena cava and in the gonadal vessels¹. In our case it was found similar finding but in male cadaver. The position of pelvic kidney was in front of s₂, s₃ and s₄.

The right testis placed lower than the left testis in the scrotum and enlarges in size. In another case report show there was no right kidney anomaly or genital organ malformation. The left kidney was found in front of the sacrum with a calculus in the renal pelvis. The blood supply of an ectopic kidney can vary. There can be more than one aberrant artery and aberrant arteries can originate from the abdominal aorta, common iliac artery, external iliac artery or inferior mesenteric artery³. Similar finding was also observed in the present case but right kidney was slightly hypertrophopized. The left kidney was supplied by branch from internal iliac, external iliac, left common iliac and direct branch from abdominal aorta.

In the present case, pelvic kidney is due to developmental anomalies. Kidneys normally start to develop in the pelvis and migrate to their normal anatomical position in the upper abdomen.

The ascent of the kidneys precedes the descent of the gonads into the pelvis. Caudal growth in the embryo appears to assist in migration of the kidneys out of the pelvis into their eventual retroperitoneal location in the renal fossa. They attain their adult position by the 9th gestational week. Factors which interfere with development, such as teratogens, genetic factors, the ureteric bud not meeting with the nephrogenic blastema for normal nephrogenesis or metanephric maternal disease, may result in abnormal migration of the kidney resulting in renal ectopia^{4,5}.

References

1. Belsare SM, Chimmalgi M, Vaidy SA, Sant SM. Ectopic Kidney and associated anomalies: A case Report. *J Anat Soc India* 2002; 51: 236-8.
2. Reddy CK, Syed NA, Satyanarayana N, Phukon MJ, Dutta R, Sunitha P et al. Left ectopic kidney with non rotation: a case report. *Nepal Med Coll J*. 2010; 12(2): 123-124.
3. Yano H, Konagai N, Maeda M, Itoh M, Kuwabara A, Kodou T, Ishimaru S. Abdominal aortic aneurism associated with crossed renal ectopia without fusion: A case report and literature review. *J Vasc Surg*. 2003; 37:1098-102.
4. Kang IJ, Lee SH, Lee SM, Lim CH, Yoon JH, Kim TW et al. A case of congenital single ectopic kidney in pelvis of patients with proteinuria. *Korean J Nephrol*. 2005; 24:137-40.
5. Kumar S, Srinivasa RB, Venkata RV. Unilateral Ectopic Kidney in the Pelvis -A Case Report. *Chang Gung Med J*. 2011; 34 (6):10-2.