

Case Report

Cerebral Abscess in a 8 years old with uncorrected tetralogy of Fallot: Anaesthetic challenge

Sidharth Sraban Routray*, Khageswar Raut, Debasis Mishra and Rajib Mishra

Department of Anesthesiology and Critical Care, SCB Medical College Hospital. Cuttack, Odisha, India

* Correspondence Info:

Dr. Sidharth Sraban Routray
Department of Anaesthesiology and Critical Care,
SCB Medical College Cuttack, India
E mail: drkitusraban@gmail.com

Abstract

Patients with cyanotic heart disease are prone to develop frequent brain abscesses. Tetralogy of Fallot is a leading cause of cyanotic congenital heart disease and is responsible for as many as 10 % of all causes of congenital heart diseases. Surgery for drainage of abscess under general anaesthesia in these children is considered a challenge. Hemodynamic instability, cyanotic spells, coagulation defects, electrolyte and acid base imbalance, and sudden cardiac arrest are among the major anaesthetic concerns during perioperative period. We are here by reporting anaesthetic management of such a case with good outcome.

Keywords: anaesthesia, brain abscess, tetralogy of fallot, surgery

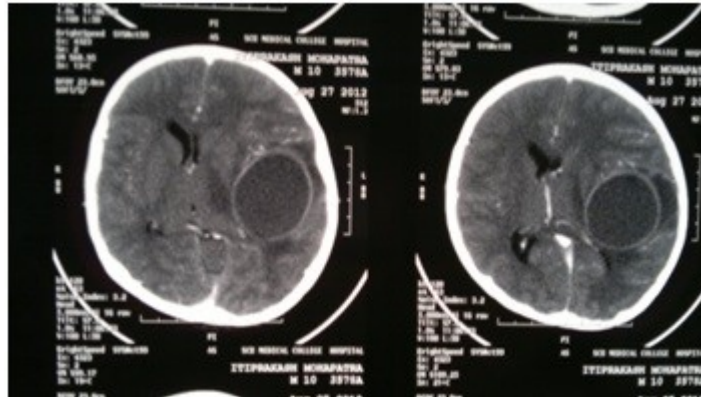
1. Introduction

Tetralogy of Fallot (TOF) is a leading cause of cyanotic congenital heart disease and forms about 10% of total congenital heart diseases and constitutes 13- 70 % of all brain abscess¹. It is characterized by a large ventricular septal defect (VSD), right ventricular outflow tract obstruction (Subpulmonic stenosis), right ventricular hypertrophy and overriding of aorta. If left untreated about half of the affected patients die during the first year of life.²

2. Case Report

A 8 year old male weighing 25kgs presented in the department of neurosurgery at S.C.B Medical college Hospital, Cuttack with the symptoms of headache, vomiting, and high grade fever for one month. There was no history of ear-ache, discharge, scalp infection, trauma, seizures, or any other systemic disorder. He had history of bluish discoloration of lips and tongue which was more pronounced during crying. Subsequently he was diagnosed to be a case of tetralogy of Fallot. In the hospital, the patient was disoriented, irritable and had some dehydration, marked central cyanosis and grade IV clubbing. His heart rate was 140/min, respiratory rate was 24/min and BP- 80/40 mm of Hg, and SpO₂ was 80% in room air. Examination of cardiovascular system revealed parasternal heave with loud pansystolic murmur and accompanying thrill in the suprasternal region. ECG showed sinus tachycardia and right axis deviation with right ventricular hypertrophy. X ray chest was suggestive of right ventricular hypertrophy and cardiomegaly with oligemic lung fields. Echocardiography revealed a large subaortic VSD and aortic override with ejection fraction of 0.75.

CT scan revealed well defined ring enhancing lesion in left temporo-parietal lobe with mass effect possibly due to abscess.

Figure 1: CT scan showing a large ring-enhancing lesion in the left temporo-parietal lobe with mass effect

Biochemical investigations were as TLC- 13000, Platelet count- 160000 and PCV 54%. Coagulation profile was as within normal limits. Other systemic examinations were normal.

In presence of an infective focus and view of the urgent nature of surgery the patient was posted for drainage of abscess under general anaesthesia. Preoperative arterial blood gas analysis revealed desaturation with a SaO₂ of 80% and PaO₂ of 55 mm Hg. The case was accepted for surgery under ASA physical status V and an informed consent was obtained.

In the operating room an intravenous line was established with 22G IV cannula and the patient was connected to cardiac monitor for monitoring of ECG, NIBP, ETCO₂, SpO₂ and temperature. A prophylactic dose of antibiotic, Ceftriaxone 500 mg was given to provide prophylaxis against infective endocarditis. The patient was premedicated with glycopyrrolate 0.1 mg IV and after preoxygenation for 3 minutes anaesthesia was induced with fentanyl 40 mcg and ketamine 50mg IV followed by suxamethonium 40mg IV to facilitate endotracheal intubation. Anaesthesia was maintained with nitrous oxide in oxygen (50:50), vecuronium bromide 0.1 mg per kg body weight IV and isoflurane (0.4-0.6%).

Patient was ventilated to maintain slight hypocarbia (ETCO₂-35). The left radial artery was cannulated for direct arterial pressure monitoring and ABG analysis. CVP monitoring was done through a double lumen CVP catheter inserted into the right internal jugular vein. The bladder was catheterized to monitor the urine output.

Phenytoin 50 mg IV, dexamethasone 4mg IV, mannitol 20gm IV and xylocard 40mg IV was administered to lower the intracranial pressure and make the brain lax for the surgeon. Left temporo-parietal craniotomy was performed by the neurosurgeon and an encapsulated abscess cavity was drained and completely removed. The surgery lasted for about two hours and throughout the procedure, the patient remained stable with SaO₂ ranging between 92-96% and ETCO₂ between 30-35 mm of Hg. Dextrose saline was used as maintenance fluid during surgery and about 100 ml of blood lost was replaced.

At the end of the surgery, the residual neuromuscular block was antagonized with neostigmine 1.5mg IV and glycopyrrolate 0.2mg IV and the patient was extubated once the patient was awake and responded to verbal commands. Postoperatively, the patient was transferred to the surgical intensive care unit for overnight observation and after 24 hours patient was shifted to the neurosurgery ward with O₂ saturation of 84%.

3. Discussion

These Patients usually suffer from the chronic hypoxemia; which manifests as persistent breathlessness and tiredness, repeated chest infections and fever. Usually they may have growth retardation, delayed milestones, severe metabolic derangements, multi-organ failure, and major neurological deficits secondary to a vascular stroke or brain abscess. Right to left shunting that bypasses the filtering of pulmonary capillaries is associated with a higher incidence of systemic infections such as brain abscess. Management of a usual brain abscess includes either aspiration by various techniques and 6-8 weeks of antibiotics. In patients unresponsive to antibiotics, large abscesses causing significant mass effect and neurological deficits, and in multi-loculated abscesses craniotomy and excision of abscesses is indicated³. A deficiency of vitamin K-dependent clotting factors, decreased and defective platelets, and accelerated fibrinolysis results in abnormal hemostasis with frequent and increased bleeding. The presence of CCF, arrhythmias, heart blocks, and infective

endocarditis can cause severe hemodynamic instability. TOF patients also have recurring bouts of severe cyanosis and hypoxemia known as cyanotic spells, which can lead to convulsions, syncope, stroke and death. Increased sympathetic activity during crying, agitation results in spasm of the hypertrophied pulmonary infundibulum and increase in right to left shunting. Both tachycardia and increased myocardial contractility can lead to infundibular spasm. Another mechanism for such hypercyanotic episodes is decreased systemic vascular resistance resulting increase in right to left shunting through ventricular septal defect⁴. It presents as abrupt worsening of cyanosis, tachycardia, hypotension and tachypnea. Cyanotic spells are treated with subcutaneous morphine 0.1-0.2 mg/kg, intramuscular ketamine 1-2 mg/kg, phenylephrine infusion 0.1-0.5 µg/kg/min, propranolol (0.05-0.25 mg/ kg IV). Sodium bicarbonate, oxygen therapy, IV fluids may have a role in reducing spell.⁵

A thorough pre-anesthesia check-up involves assessment of cardiac and neurological status. Cardiology consultation, Two-Dimensional (2D)-echocardiography and assessment of coagulation profile is necessary. Vomiting, fever, poor intake can cause dehydration and exaggeration of cyanotic congenital heart disease. Prolonged preoperative fasting should be avoided. Drinking of clear fluids up to 2 hours before surgery should be allowed. Mannitol must be used cautiously. Cyanotic patients with hematocrit 60% may develop coagulopathy and may require preoperative phlebotomy. Separation of children from their parents should be gentle. One should avoid unnecessary pin-pricks which can result crying and precipitation of cyanotic spells. Intraoperative goals include maintenance of oxygenation and hemodynamic stability by maintaining SVR and reducing PVR⁵. With the use of opiate technique, oxygen saturation levels are well maintained and may actually improve during induction, intubation and surgical stimulation even in cyanotic children⁶. We used a combination of fentanyl and ketamine in our case for induction of anaesthesia which actually improved arterial oxygenation and maintained it between 92-96% intraoperative. Also Ketamine has been found to be the excellent induction agent in such cases as it improves the oxygenation by decreasing the right to left shunt as a result of increase in systemic vascular⁷. ABG monitoring is essential since pulse oximetry is less accurate in severe cyanosis. The allowable blood loss is more in TOF patients due to pre-existing polycythemia and transfusion is deferred till 25% of blood volume is lost. Air entry into veins should be prevented as it can cause life-threatening paradoxical embolism. Hypotension, hypovolemia, acidosis, hypoxia, and hypercarbia increase intraoperative shunting and should be avoided. Postoperative care includes intensive monitoring, appropriate fluid management, and good control of pain.

A higher risk of perioperative complications is reported in children with congenital heart disease especially cyanotic congenital heart diseases, undergoing emergency non-cardiac surgery⁸. A significantly higher mortality has also been reported in cyanotic congenital heart disease patients during brain abscess aspirations, attributed variously to cyanotic spells.⁹ A carefully administered general anesthesia with controlled ventilation, and advanced monitoring is important. Maintenance of hemodynamics, oxygenation, and intracranial pressure and control of seizure will determine the safe outcome.

References

1. Ghafoor T, Amin MU. Multiple brain abscesses in a child with congenital cyanotic heart disease. *J Pak Med Assoc.* 2006;56:603-5.
2. Sharma BS, Gupta SK, Khosla VK. Current concepts in the management of pyogenic brain abscess. *Neurol India* 2000;48:105-11.
3. Moorthy RK, Rajshekhar V. Management of brain abscess: an overview. *Neurosurg Focus.* 2008;24: E3.
4. Oshita S, Uchimoto R, Aka H et al: Correlation between arterial blood pressure and oxygenation in the tetralogy of fallot. *J Cardiothorac Anesth.* 1989 Oct;3(5):597-600.
5. White MC. Anaesthetic implications of congenital heart disease for children undergoing non – cardiac surgery. *Anaesth Intensive Care Med.* 2009;10: 504-9.
6. Abhijit Ratha, Pragati Ganjoo, Amaya Singh, Monica S. Tandon, and Daljitsingh ,Surgery for brain abscess in children with cyanotic heart disease: An anaesthetic challenge. *Journal of Pediatric Neurosciences:* 2012; 1: 23-26.
7. Takeshita M, Kagawa M, Yato S, Izawa M, Onda H, Takakura K, et al. Current treatment of brain abscess in patients with congenital cyanotic heart disease. *Neurosurgery* 1997;41:1270-9.
8. Baum VC, Barton DM, Gutgsell HP. Influence of congenital heart disease on mortality after noncardiac surgery in hospitalized children. *Pediatrics* 2000;105:332-5.
9. Prusty GK. Brain abscesses in cyanotic heart disease. *Indian J Pediatr.* 1993;60:43-51.