

A Comparative Study of Posterior Approach versus Lateral Approach in Surgical Management of Intra-capsular Neck Femur Fractures

Prasad Aparajit^{1*}, Vinay Yadav² and M. R. Koichade³

¹Associate Professor, ²Senior Resident, ³Head of Department,
Department of Orthopaedics, Indira Gandhi Government Medical College and Hospital, Nagpur, Maharashtra, India-440001

QR Code



*Correspondence Info:

Dr. Prasad Aparajit
Aparajit Orthopaedic and Maternity Nursing Home 22,
Near State Bank of India, West High Court Road,
Surendra Nagar, Nagpur, India

*Article History:

Received: 19/02/2017

Revised: 27/03/2017

Accepted: 29/03/2017

DOI: <https://dx.doi.org/10.7439/ijbar.v8i3.4063>

Abstract

Aims and Objective: The present study was undertaken to evaluate and compared relevant early surgical complications rates after posterior and lateral approach.

Methods: A total 80 patients of either sex, age between 50-80 years with intracapsular neck femur fracture were operated with hemiarthroplasty. Patients were divided in two equal groups i.e. group A and B operated with posterior and lateral approach respectively. Several variables including age, sex, operative time, blood loss, early surgical and post-operative complications, post-operative care, hip function and final outcome measures were noted and compared between two groups.

Results: The mean age of patients was 64.30 ± 5.39 years in group A and 65.85 ± 5.64 years in group B with female to male ratio was 1.6:1 for group A and 1.4:1 for group B. Operating time for group A and for group B was 48.43 ± 5.38 and 47.50 ± 7.59 minutes respectively. Mean intraoperative blood loss was 144.75 ± 17.68 ml in group A and 148.38 ± 15.03 ml in group B. The most common complication in both the groups was infection and rate in group A was 17.50% and in group B was 12.50%. Posterior approach carries an increased risk of prosthetic dislocation as compared to lateral approach. There was no intraoperative mortality seen in follow up period. The rate of secondary procedures was high with posterior approach (12.5%) as compared to lateral approach (7.5%). The average Harris Hip Score was 85.62% in group A and 83.40% in group B.

Conclusion: The rate of early surgical complications and outcome measures after posterior and lateral approaches is not significantly different. A larger randomized trial or may be a multicentre trial can further improve the interpretation of the results.

Keywords: Intracapsular neck femur fracture, Hemiarthroplasty Posterior approach, Lateral approach, Harris Hip Score.

1. Introduction

Hip fractures are common and comprise about 20% of the operative workload of an orthopaedic trauma unit [1]. Intracapsular femoral neck fractures account for about 50% of all hip fractures. The lifetime risk of sustaining a hip fracture is high and lies within the range of 40% to 50% in women and 13% to 22% in men. Life expectancy is increasing worldwide, and these demographic changes can be expected to cause the number of hip

fractures occurring worldwide to increase from 1.66 million in 1990 to 6.26 million in 2050 [2].

The femoral neck fracture is one of the most common fractures in the elderly. Younger patients are also frequently affected due to accidents. During the past decade, there has been a change in the treatment of femoral neck fractures from internal fixation to more use of hemiarthroplasty (HA) in many countries [3-7].

Hemiarthroplasty has many advantages since it allows the immediate return to daily activities and avoids bed rest complications. This procedure carries a relatively short duration of operation and reasonable clinical outcomes. One important issue when treating patients with hemiarthroplasty is the type of surgical approach. Two different surgical approaches have predominated. In transgluteal direct lateral approach, as described by Hardinge in 1982 [8], the anterior portion of the gluteus medius and minimus muscles is divided. The posterior approach, as described by Moore in 1957 [9], involves division of the piriformis, obturator internus muscle, and gemelli tendons. It is still unclear whether one approach may be advantageous. In Norway, the direct lateral approach has been the most common surgical approach when treating elderly patients with femoral neck fractures [10]. The methods are often chosen independently of scientific studies and often depend on the local economic and social conditions and/or preferences of surgeons.

Recently some less invasive modifications have been described and compared to the standard approaches such as Kocher-Langenbeck (dorsal), Bauer or Hardinge (lateral), Watson-Jones (anterolateral) and Smith-Peterson (anterior). All of them seem to have several advantages and every modification leads to different new problems. Following hemiarthroplasty several studies showed a lower dislocation rate after the lateral approach compared to the posterior approach. Unfortunately most publications focus only on dislocation rate. This has to be regarded as a limitation, since all types of complications should be evaluated when investigating surgical techniques. Hence the aim of this study was to perform a thorough evaluation of relevant early surgical complications in patients being treated with hemiarthroplasty after femoral neck fracture, comparing the posterior approach to the lateral approach.

2. Material and Method

The study designed was a prospective comparative study comprising of series of 80 patients with intracapsular neck femur fractures between 50 to 80 years of age treated with hemiarthroplasty either by posterior approach or lateral approach from October 2014 to October 2016. Study was started, after obtaining institutional ethical committee approval and written informed consent from all the patients. Those patients having painless hip before trauma, patients with no other associated hip pathology and patients who are fit and willing to go for surgery were included in the study. Exclusion criteria consisted of patients with intertrochanteric femur fractures, pathological neck femur fractures, patients with an additional acute lower extremity fracture in addition to the neck femur fracture, All patients with age below 50 years and above 80 years, fracture

duration more than one month, painful hip before trauma, intracapsular neck femur fracture managed by any other approach or treatment modality, neurological deficit involving same limb, patients with severe medical comorbidities and are unfit for surgery, revision surgery. A detailed evaluation including history and a thorough general and systemic examination and all relevant investigations were done for all the patients. Then patients were divided in two groups by simple random sampling method: Group A: patients to be operated by posterior approach and Group B: patients to be operated by lateral approach.

Both the approaches were performed under spinal anaesthesia, in lateral decubitus with operative extremity facing up, axillary roll, anterior positioner on pubic symphysis and posterior positioner on sacrum, foley in place. All patients were given broad spectrum intravenous antibiotic in immediate preoperative period. Preoperative scrubbing and draping was done with sterile sheets.

2.1 Incision and exposure

In posterior approach a longitudinal incision is made centered on the greater trochanter. After division of fascia the trochanteric bursa is excised. Then incision can be made through tendon of gluteus medius extending distally to reflect vastuslateralis off the femur. At proximal end of the trochanter the gluteal muscles are split in line with their fibres. Care should be taken not to carry this split too proximally or injury to the superior gluteal nerve is a risk. This risk is increased if dissection is performed more than 5 cm proximal to the trochanter. In that case the approach can be developed by dissecting down to bone and then reflecting the tissues in an anterior direction until capsule is incised around base of neck. The alternative is to divide the gluteus medius and minimus tendons separately, which exposes the hip joint capsule, which is then incised separately. The hip can then be exposed by flexion and external rotation of the femur, which delivers the fractured femoral neck out of the joint, thereby allowing access to the fractured head in the acetabulum. Once this is removed, hemiarthroplasty can be carried out.

The lateral approach is made through an incision centered on the greater trochanter, which extends distally down the shaft and proximally toward the posterior superior iliac spine. The more proximal part of the approach, which provides access to the sciatic notch and posterior column of the acetabulum, is not routinely required for femoral neck surgery. The fascia is divided in line with the incision. Above the level of the trochanter the gluteus maximus is split. More distally the exposure is facilitated by partial division of the gluteus maximus insertion into the lineaaspera. The sciatic nerve should be indentified and protected. The short external rotators of the hip are divided starting proximally with piriformis. The obturatorinternus

and the gemelli are then divided and reflected posteriorly, where they lie over the sciatic nerve. The capsule can then be incised to expose the femoral head and neck. The neck is accessed by flexing the knee to 90 degrees and internally rotating the femur.

2.2 Prosthesis insertion and cementing

Femoral head was removed using cork screw. It was used to measure head size for templating implant. Neck cut was made 0.5 -1cm proximal to lesser trochanter. Box cutters, canal finder, lateralizing reamer were used to make sure down canal and not in virus, serial reaming done. Implant trials done. Stability, range of movements and limb length checked. Hip dislocated, trails removed and cement restricter placed 15 cm down from neck cut (depth may vary depending on the stem being used). Canal was cleaned and dried using sponge or suction. Sponge was placed in acetabulum to block cement extrusion. Insert cement in retrograde fashion pressurized with gun. Cement usually takes 3.5-4.5 minutes to reach appropriate consistency for insertion. Place implant in 10-15 degrees anteversion (angled posterior for increased anteversion). Use stem pusher and tommy bar to control depth and anteversion. Hold in place until cement hardens (usually 15 minutes). Relocate hip. Confirm implant position and leg length.

An immediate postoperative check up X-ray was done to confirm proper positioning of the prosthesis. The patients were allowed to sit on first postoperative day and immediate weight bearing was allowed as tolerated by the patient. Physiotherapy was immediately started. Intravenous antibiotics were continued postoperatively and given for five days and analgesics were added as per need. Dressing was checked on third and fifth day and patients were discharged unless there was a wound complication. Before discharging the patient all the data including demographics, preoperative and intraoperative findings were collected in prescribed format. Oral antibiotics were given for 7 to 10 days. On discharge patients were instructed to perform a rehabilitation program three times a day including quadriceps and abductor strengthening exercises. Suture removal was done on outpatient basis on 14th day. Then regular follow up was done at 3,6,12 months. Patients were evaluated for surgical complications like dislocation,

infection, post operative bleeding or hematoma, periprosthetic fractures at each follow up visit, also the active range of motion, assessment of Harris hip score was done. Follow up data was collected in the prescribed format for every patient.

2.3 Statistical Methods

The descriptive statistics for demographic variables like age, sex were obtained according to approach used in surgery. The data was expressed in terms of percentages. The continuous variables were handled by calculating the mean and standard deviation. Student's t test was used for calculating significance of difference between two continuous variables. The categorical variables were handled by using chi square test and fisher exact test to find association between the variables.

3. Observations and Results

Eighty patients were selected for the study, divided into Group 'A' and Group 'B'; forty patients were studied in each group, who were in the age group of 50-80 years. Mean age of patients was 64.30 ± 5.39 years in group A and 65.85 ± 5.64 years in group B. We had almost equal distribution of males and females in both the surgical groups with female to male ratio of 1.6:1 for group A and 1.4:1 for group B. The involvement of right side was commoner than left side in both surgical groups. The most common mode of trauma was low energy injuries like fall at home in elderly patients. The distribution was almost same in both groups with around 90% to 92.5% patients having simple trivial trauma. Road traffic accident was common in 50 to 55 years. The most common type of fracture was subcapital followed by transcervical and basicervical. One patient in both surgical groups had associated ipsilateral distal end radius fracture which was managed conservatively by closed reduction and below elbow cast. One patient in posterior surgical group had ipsilateral proximal humerus fracture which was managed conservatively by universal shoulder immobilizer. The mean operating time for group A was 48.43 ± 5.38 minutes and for group B was 47.50 ± 7.59 minutes (p-value 0.532), (Table 1).

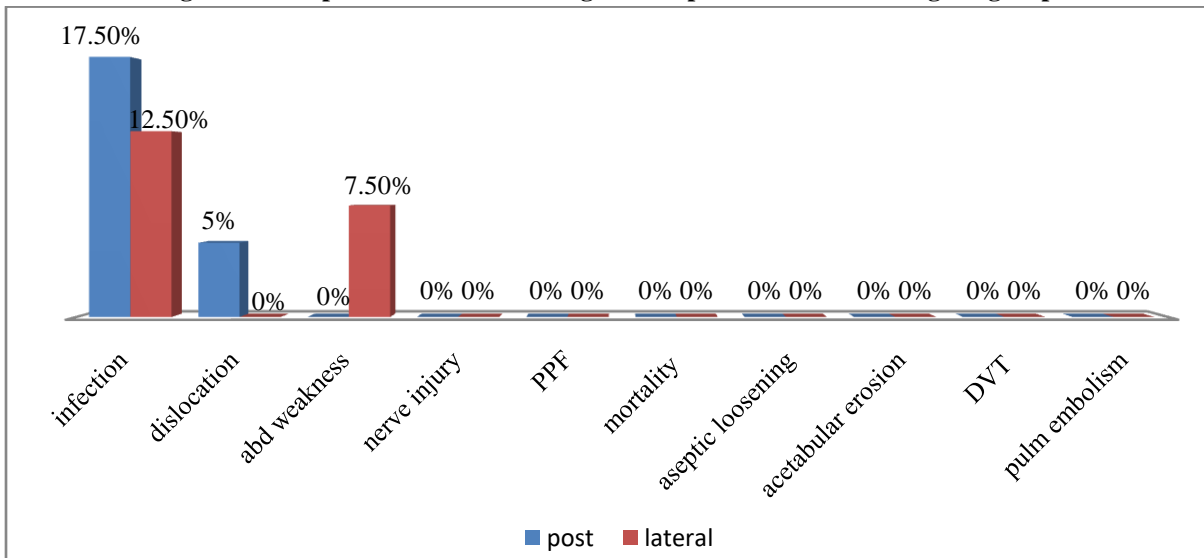
Table 1: Comparison of various parameters between two groups

Parameters	Group A	Group B	P value
Age (years)	64.30±5.39	65.85±5.64	0.213
Male/Female (n)	15/25	17/23	0.82
Involvement of side- Right side/Left side (n)	25/15	21/19	-
Low energy(Fall)/ High energy(RTA) (n)	36/4	37/3	-
Subcapital/ Transcervical/Basicervical Fracture	23/11/6	21/9/10	
Duration of surgery (min.)	48.43±5.38	47.50±7.59	0.532

The mean intraoperative blood loss was 144.75±17.68 ml in group A and 148.38±15.03 ml in group B which was statically insignificant. We had thoroughly studied the relevant surgical complications in both surgical groups and which was observed in 22.5% of patients operated with posterior approach and 20% patients operated with lateral approach. The most common complication in both the surgical approaches was infection; overall infection rate in all patients operated for hemiarthroplasty was 15% whereas infection rate in group A was 17.50% and group B

was 12.50%. Dislocation was seen in 2 patients operated with posterior approach while this complication was not seen with lateral approach. The incidence of abductor weakness was present in three patients of lateral approach while no patients operated with posterior surgical approach. Other surgical complications such as sciatic nerve injury, periprosthetic femur fracture, intraoperative or perioperative mortality, aseptic loosening of prosthesis, erosion of acetabulum, deep vein thrombosis and pulmonary embolism were not seen in patients of either group (Figure 1).

Figure 1: Comparison of relevant surgical complications in both surgical groups



The rate of secondary procedures was high with posterior approach (12.5%) as compared to lateral approach (7.5%). In group A, 5 patients with deep infection underwent debridement and 2 patients with dislocated prosthesis required open reduction while in group B, 3 patients with deep infection were debrided. Table 3 shows

the average Harris Hip Score at follow up. The average Harris Hip Score at end of 1 year follow up was comparable in both groups and it was 85.62% in posterior approach and 83.40% in lateral approach. No mortality was seen in the follow up period.

Table 2: Average Harris hip score at follow up

Harris Hip Score	Group A	Group B	P-value
3 months	67.22±7.61	65.01±7.35	0.191
6 months	76.45±6.31	74.06±6.81	0.108
1 year	85.62±6.04	83.40±5.09	0.094

4. Discussion

The present study hypothesize that the results are needed in order to help orthopaedic surgeons to decide about the surgical approach when treating patients in orthogeriatrics, where studies about this topic are lacking. The observations and results clearly indicated that both the approaches are comparable to each other in terms of primary and secondary outcome measures. The primary outcome measure was the regain of walking ability. Secondary outcome measures recorded included mortality,

ease of surgery, length of surgery, operative blood loss, post-operative complications, hospital stay, need for subsequent revision surgery and range of movements of the hip. However we found no significant difference in overall complication rates between two groups. This overall complication rate seems to be high for hiphemiarthroplasty in general. For hemiarthroplasty in particular however these findings are consistent with the literature, indicating a need to further optimise femoral neck fracture treatment in elderly trauma patients. Remarkably, the patterns of surgical

complications were not equally distributed in the two groups. This was particularly true for dislocation. Consistent with the literature we found that the risk for dislocation was reduced by 3 to 4% after lateral approach.

The mean age of patients for posterior approach was 64.30 years and for lateral approach was 65.85 years, ranging from 50-80 years and the difference was found statistically insignificant ($p>0.05$) indicating that there was no age bias while selecting patients for the two approaches. The age group in our study was comparable to previous studies [11-13]. Females formed majority of patients in this series which was comparable to the series of Barber *et al* [12] and Mukka *et al* [14]. The female preponderance in the series can be attributed to the fact that the estrogen level decreases after menopause which in turn predisposes elderly females to osteoporosis. Also females have low BMI and poor exposure to sunlight. The involvement of right side of the neck femur was commoner than left side in both the approaches but it doesn't affect the outcome of the study, so no need to do randomization in this, which corresponds with the study of Mukka *et al* [14] and Moore *et al* [15].

The low energy injuries which include fall at home, fall from bed, slip in bathroom were most common cause of fracture as compared to high energy injuries like road traffic accidents. The distribution between two groups was almost same with 90% and 92.5% low energy injuries in posterior and lateral approaches respectively. Thus, it is clear that simple trivial trauma like fall is the most common mode of injury for intracapsular neck femur fracture occurring in elderly patients in most of the studies [16,17] but distribution varies with studies. The neck femur fracture was classified according to their anatomic location. The most type of intracapsular neck femur fracture was subcapital. The distribution between two groups was almost same 57.5% and 52.5% in posterior and lateral approach respectively. Transcervical was the second most common type. The distribution of patients in our study was almost similar to a study of Tolani *et al* [17]. We had compared the operative time in minutes in both surgical approaches and difference was statically insignificant. Only few studies [18-20] had mentioned the operating time in minutes.

Intraoperative blood loss was calculated by number of mops used and blood collected in suction machine before the wash is given. Mop used in our institute was weighed before and after complete soakage and an average of 40 ml blood loss per mop was taken. The mean intraoperative blood loss was 144.75 ml in posterior approach and 148.38 in lateral approach. Very few studies [20] have mentioned intraoperative blood loss.

Seven patients in group A and 5 patients in group B got infected postoperatively. The overall infection rate in all patients operated for hemiarthroplasty irrespective of the

approach was 15% which was quiet high as compared to other studies. It is one of the main reasons for the failure after haemiarthroplasty surgery. The approach used does not affect the infection rate. There are many risk factors predisposing to infection such as comorbidities of patients, poor patient hygiene, and low sterile conditions. This was comparable with studies done by Barber *et al* [12] and Mukka *et al* [14]. In current study 2 patients operated by posterior approach suffered dislocation while dislocation was not seen in any patients of lateral surgical approach. Most of the studies [12, 21] done in past indicate that posterior approach as compared to lateral approach carries an increased risk of prosthetic dislocation. Thus use of lateral approach prevents dislocation related reoperations. There was no other postoperative complications observed like sciatic nerve injury, periprosthetic fracture, mortally aseptic loosening of prosthesis, acetabularerosion, deep vein thrombosis, pulmonary embolism in both surgical groups. Our results were correlated with other studies [14,16,20].

We had done secondary procedures in the form of debridement and open reduction to manage complications like infection and dislocation respectively. In case of posterior approach it was done for three cases of deep infection and two cases of dislocation. In case of lateral approach it was done for three cases of deep infection. However in most studies it had been performed for infection with debridement, dislocation with open reduction and periprosthetic fracture with plating. Our result was compared with previous studies [14,16].

In most studies on intracapsular neck femur fracture the functional outcome was assessed by Harris hip score. In our study the average Harris Hip Score at 1 year follow up was 85.62 in posterior surgical approach and 83.40 in lateral approach. Patients in both groups had good average Harris Hip Score and difference was statically insignificant. The distribution in our study was comparable to studies performed by other authors [14,15].

5. Conclusion

The present study concluded that there were no notable differences in outcomes and complications between the two approaches. Neither lateral nor the posterior approaches seem to offer a clear advantage regarding the early surgical complications. A decision in favour of one surgical approach cannot be based on evidence on early surgical complication rates alone. More outcome parameters should be included together with studies on the severity of various kinds of complications. Thus a recommendation for a certain surgical approach remains an expert opinion based on subjective judgement on the severity of several complications.

The quality of the literature regarding the surgical approaches is limited. A larger randomized trial or may be a multicentre trial can further improve the interpretation of the results.

Acknowledgement

The authors sincerely thank the department of orthopaedics, surgery, other staff of operation theatre and administration of Indira Gandhi Government Medical College and Hospital, Nagpur, Maharashtra, for permission to study and providing facility to carry out the work.

Reference

- [1] Singer BR, McLauchlan GJ, Robinson CM *et al.* Epidemiology of fractures in 15,000 adults: the influence of age and gender. *J Bone Joint Surg Br* 1998; 80(2):243-248.
- [2] Dennison E, Mohamed MA, Cooper C. Epidemiology of osteoporosis. *Rheum Dis Clin North Am* 2006; 32(4):617-629.
- [3] Keating JF, Grant A, Masson M, Scott N W, Forbes J F. Randomized comparison of reduction and fixation, bipolar hemiarthroplasty, and total hip arthroplasty. Treatment of displaced intracapsular hip fractures in healthy older patients. *J Bone Joint Surg Am* 2006; 88 (2): 249-260.
- [4] Frihagen F, Nordsletten L, Madsen J E. Hemiarthroplasty or internal fixation for intracapsular displaced femoral neck fractures: randomised controlled trial. *BMJ (Clinical research ed)* 2007; 335 (7632): 1251-1254.
- [5] Gjertsen JE, Vinje T, Engesaeter LB, Lie SA, Havelin LI, Furnes O *et al.* Internal screw fixation compared with bipolar hemiarthroplasty for treatment of displaced femoral neck fractures in elderly patients. *J Bone Joint Surg Am* 2010; 92 (3):619-628.
- [6] Stoen RO, Lofthus CM, Nordsletten L, Madsen JE, Frihagen F. Randomized trial of hemiarthroplasty versus internal fixation for femoral neck fractures: no differences at 6 years. *Clin Orthop Relat Res* 2014; 472 (1): 360-367.
- [7] Parker MJ, Khan RJ, Crawford J, Pryor GA. Hemiarthroplasty versus internal fixation for displaced intracapsular hip fractures in the elderly. A randomised trial of 455 patients. *J Bone Joint Surg Br* 2002; 84 (8):1150-1155.
- [8] Hardinge K. The direct lateral approach to the hip. *J Bone Joint Surg Br* 1982; 64 (1):17-19.
- [9] Moore A T. The self-locking metal hip prosthesis. *J Bone Joint Surg Am* 1957; 39-A(4): 811-827.
- [10] Havelin LI, Furnes O, Engesaeter LB, Fenstad AM, Johannessen CB, Dybvik E, Fjeldsgaard K, Gundersen T: The Norwegian Arthroplast Register. *Annual report* 2016. ISBN: 978-82-91847-21-4 ISSN: 1893-8914 2016.
- [11] Parker MJ, Dynan Y. Is Pauwels classification still valid? *Injury* 1998; 29(7):521-523.
- [12] Barber TC, Roger DJ, Goodman SB, Schurman DJ. Early outcome of total hip arthroplasty using the direct lateral Vs the posterior surgical approach. *Orthopedics* 1996; 19:873-875.
- [13] Weale E, Newman P, Ferguson IT, Bannister GC. Nerve injury after posterior and direct lateral approaches for hip replacement. A clinical and electrophysiological study. *The Journal of Bone and Joint Surgery* 1996; 78:899-902.
- [14] Mukka SS, Sayed-Noor AS. An update on surgical approaches in hip arthroplasty: Lateral versus posterior approach. *HIP International* 2014; 24:S7-11.
- [15] Moore AT. The self-locking metal hip prosthesis. *J Bone Joint Surg Am* 1957;39-A(4): 811-827.
- [16] Parker MJ. Hemiarthroplasty versus internal fixation for displaced intracapsular fractures of the hip in elderly men. *Bone Jt J* 2015; 97-B (7):992-996.
- [17] Tolani *et al.* Proximal Femoral Nail - A Minimally Invasive Method for Stabilization of Subtrochanteric Femoral Fractures. *International Journal of Scientific Research* 2014; 3(1):20-22.
- [18] Sipilä J, Hyvönen P, Partanen J, Ristiniemi J and Jalovaara P. Early revision after hemiarthroplasty and osteosynthesis of cervical hip fracture Short-term function decreased, mortality unchanged in 102 patients, *Acta Orthopaedica Scandinavica* 2004; 75:4, 402-407.
- [19] Parker MJ, Stockton G. Internal fixation implants for intracapsular proximal femoral fractures in adults. *Cochrane Database Syst Rev* 2001; (4): CD001467.
- [20] Keene GS, Parker MJ. Hemiarthroplasty of the hip — the anterior or posterior approach? A comparison of surgical approaches. *Injury [Internet]*. 1993; 24(9): 611-613.
- [21] Jameson SS, Kyle J, Baker PN, Mason J, Deehan DJ, McMurtry IA, Reed MR. Patient and implant survival following 4323 total hip replacements for acute femoral neck fracture. *J Bone Joint Surg Br* 2012; 94-B (11) 1557-1566.