

A Clinical Study of Oral Malignancies in Rural Set Up

Yashwant L. Durge, Megha A. Kawale* and Vijay Potey

Department of General Surgery, Shri V. N. Government Medical College, Yavatmal, Maharashtra, India

QR Code



*Correspondence Info:

Dr. Megha A. Kawale,
Department of General Surgery,
Shri V. N. Government Medical College,
Yavatmal, Maharashtra, India

*Article History:

Received: 18/02/2017

Revised: 20/03/2017

Accepted: 22/03/2017

DOI: <https://dx.doi.org/10.7439/ijbar.v8i3.4050>

Abstract

Aim and Objectives: Aim of the present research was to study the epidemiologic profile, risk factors, different surgical approaches, post operative complications and surgical outcome of oral cancer in rural set up.

Methods: We conducted a clinical study of 30 histopathologically confirmed cases of oral cancer in tertiary care hospital, over a period of 23 months from December 2012 to October 2014. Data were collected and analyzed using SPSS computer software version 17.0 and Graph Pad Prism 5.0.

Results: Mean age of the patients was 55.46 years, ranging from 32-80 years; malignancy of oral cavity was common in males (60%) with a male: female ratio of 3:2. 20 (66.66%) oral cancer patients had risk habits, 33.33% were habituated for tobacco chewing and 20% for smoking and alcohol, moreover 6.67% were having addiction of smoking, alcohol and tobacco chewing and 6.67% were having addiction of smoking. Buccal mucosa was the commonest site of lesions (50%) followed by tongue (30%) and then lips (13.33). Wide local excision with modified radical neck dissection (50%) was most common surgical procedure done, followed by Hemiglossectomy with modified radical neck dissection (26.67%). Stitch infection was common early post operative complication while marginal flap necrosis was most common complication after reconstruction with PMMC flap. During follow up, 2 patient died mortality of patient was due to poor general condition and old age.

Conclusion: The malignancy of oral cavity was higher among elderly males predominantly with risk habits of tobacco consumption, also with increasing incidence in females. A surgical excision with wide margins and appropriate reconstruction is necessary to optimize the disease and functional outcome.

Keywords: Epidemiologic profile, Risk factors, Histopathology, Hemiglossectomy, PMMC flap.

1. Introduction

Cancer is one of the major threats to public health in the developed world and increasingly in the developing world [1]. In developing world, Oral cancer is the fourth most common cancer in men and fifth most common cancer in women [2]. Oral cancer is a heterogeneous group of cancers arising from different parts of the oral cavity, with different predisposing factors, prevalence and treatment outcomes. It is among the top three types of cancers in India [3]. Severe alcoholism, use of tobacco like cigarettes, smokeless tobacco, betel nut chewing and human papilloma virus (HPV) are the most common risk factors for oral cancer [4,5]. It may also occur due to poor dental care and poor diet [6]. Global cancer statistical data showed that

India has one of the highest incidence rates of oral cancer worldwide.

Oral cancer is significant public health importance to India. Firstly, it is diagnosed at later stages which result in low treatment outcome and considerable costs to the patient whom typically cannot afford this type of treatment [7]. Secondly rural areas in middle and low income countries also have inadequate access to trained providers and limited health services as a result delay has also been largely associated with advanced stages of oral cancer. Earlier detection of oral cancer offers the best chance for long term survival and has better potential to improve treatment outcome and make healthcare affordable [8].

Thirdly oral cancer affect's those from the lower socioeconomic groups, that is peoples from lower socioeconomic strata of society is due to a higher exposure risk factors such as use of tobacco [9]. Lastly even though clinical diagnosis occurs via examinations of oral cavity and tongue which is accessible by current diagnostic tool, majority of cases presents to a health care facility at later stages of cancer subtypes, thereby reducing chances of survival due to delay in diagnosis [10].

Although tumours of the oral cavity are readily accessible due to their anatomic location, most are diagnosed at an advanced stage. The treatment consists of complex oncotherapy, the basis of which to the present day is the radical surgical procedure. Surgical excision of the primary tumour and the regional lymph nodes greatly influences the feeding and speech functions, as well as the appearance of the patient due to the amount of excised tissue. In patients receiving complex oncotherapy for oral cavity tumours, especially in the case of composite surgery, the accepted method for large surface area and tissue volume replacement is the microsurgical free tissue transfer [11].

Considering the rising trends in the incidence of oral malignancies in rural areas, current study was carried out with objectives to study the epidemiologic profile of oral cancer, its clinical correlation between risk factors, different surgical approaches for treating oral cancers and to study the post operative complications and surgical outcome of oral cancer in rural set up.

2. Materials and Methods

After obtaining institutional ethical committee approval and patients written informed consent, the clinical study was conducted in department of general surgery at tertiary care hospital in rural setup over a period of 23 months from December 2012 to October 2014. Total 30 patients of histopathologically confirmed squamous cell carcinoma of oral cavity with pre-specified inclusion criteria were included in study. Most of Stage 1, Stage 2 and Selected Stage 3 disease patients were enrolled in current study while Stage 4 disease patients were referred to higher centre for chemo-radiotherapy for downgrading due to unavailability of this facility at this institution. All immunocompromised patients (HIV, Steroid Therapy, Organ Transplant patients) and patients with distant metastasis were excluded from the study.

Patients who were admitted with primary diagnosis of oral cancer, (based on detailed history, clinical examination, routine investigations, biopsy, FNAC, USG, CT Scan, x ray mandible and chest x-ray) were subjected to the required preoperative investigations. After ensuring

fitness for surgery, these patients were taken for appropriate surgeries.

According to site, tumour size, stage and lymph node status appropriate surgical procedures were planned i.e. Wide local excision, wide local excision + Modified Radical Neck Dissection, Wide local excision+ Radical Neck Dissection, Wide local excision+ Hemimandibulectomy, Hemiglossectomy + Modified Radical Neck Dissection, Hemiglossectomy + Radical Neck Dissection. All surgical procedures were done under general anaesthesia and done by senior general surgeon at tertiary care hospital. Nasal intubation tracheostomy was done whenever required. All 30 patients underwent above surgical procedure and possible reconstructions were followed up upto 6 months.

Details about the demographic profile, personal habits like smoking, consumption of alcohol, tobacco chewing, pattern of chewing, presenting complaints, site of the lesion, staging of the disease and histopathological type, and differentiation were recorded in case report proforma and analysed statistically.

2.1 Statistical Analysis

Analysis was done by using descriptive and inferential statistics using chisquare test. The software used in the analysis was SPSS 17.0 version and GraphPad Prism 5.0. The results were considered significant at $p < 0.05$.

3. Observations and results

The study involved 30 patients of oral malignancies, among these 18 (60%) were males and 12 (40%) were females and male to female ratio was 3:2. Majority of the patients were in the age group of 51-60 years (46.67%), followed by 31-40 (20.0%). The youngest patient in present study was 32 years old while oldest was 80 years old. Mean age of the patients was 55.46 years. The majority of patients were agriculturists (43.33%), household worker (20%) and labourers (20%), followed by business man (16.66%) and office worker (10%).

Regarding personal habits, most of the patients were having history of tobacco consumption in various forms. 10 patients (33.33%) were having addiction of tobacco chewing. Alcohol consumption and addiction of smoking was found in 6 (20%) patients, 3 (10%) were consuming smokeless tobacco in the form of chewing pan, 2 (6.67%) patient had history of smoking, 2 (6.67%) patients were having addiction of smoking, alcohol and tobacco chewing, furthermore alcohol consumption was found in 2 (6.67%) patients. Consumption of alcohol and tobacco in the form of smoking or chewing was noted in 2 patients. Three (10%) patients had no habits, (Table 1).

Table 1: Distribution of patients according to risk factors

Risk Factors	No of patients	Percentage (%)
Tobacco	10	33.33
Smoking+Alcohol	6	20.00
Pan	3	10.00
Smoking	2	6.67
Smoking+Alcohol+Tobacco	2	6.67
Alcohol	2	6.67
Alcohol+Tobacco	2	6.67
No Habit	3	10.00

Presence of oral lesion in the form of growth and ulcer was the most common complaint noted which accounted for 83.33% of cases, from which most of the patients (46.67%) presented with growth as a presenting symptoms followed by 36.67% presented with ulcer. Other complaints included growth plus pain (6.67%), pain (3.33%), growth with node (3.33%) and growth with ulcer (3.33%). Buccal mucosa was the most common site of oral cancer (50%), (Fig 1a and 1b) followed by oral tongue (30%), and then lips (13.33%), (Fig 1c and 1d) and alveolus (6.67%), (Fig 1e and 1f). Most of the patients of oral cancer from Stage 1 (11, 36.7%) and Stage 2 (17, 56.7%) and only 2 patients (6.7%) had Stage 3 oral cancer.

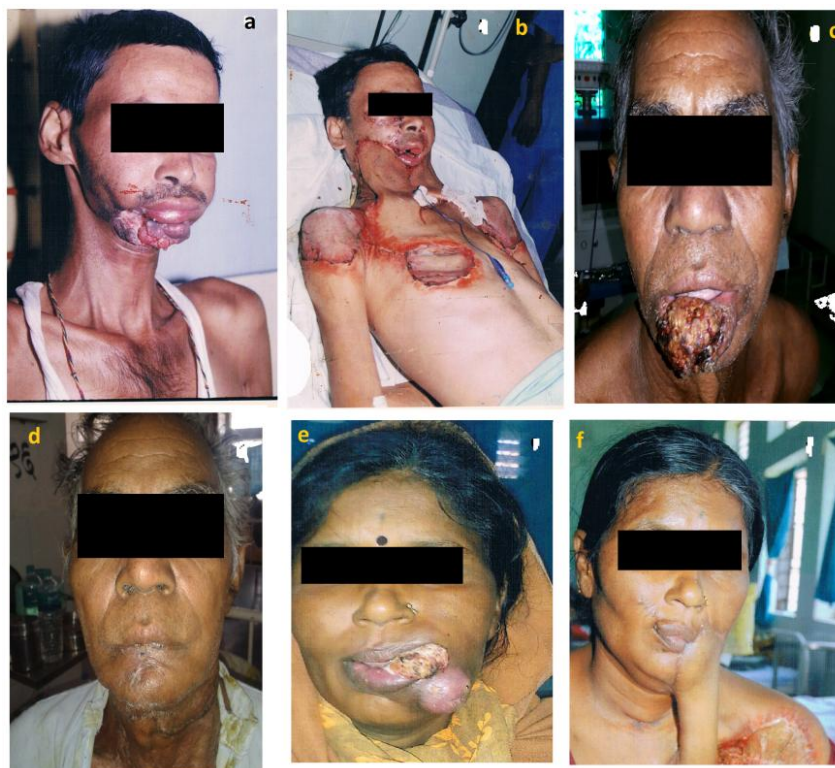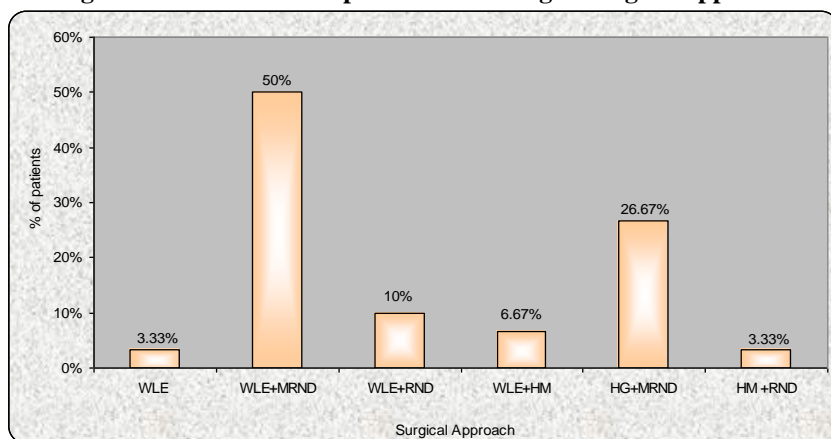


Figure 1: a) Pre operative patient of carcinoma cheek (buccal mucousa), b) Post operative patient of carcinoma cheek (buccal mucousa) reconstruction done with PMMC flap, c) Pre operative patient of carcinoma of lip, d) Post operative patient of carcinoma of lip after wide local excision with modified radical neck dissection done, e) Pre operative patient of Carcinoma of Alveolus, f) Post operative patient of Carcinoma of Alveolus After reconstruction with PMMC flap

Wide local excision with modified radical neck dissection was the primary procedure done in maximum number of patients (15, 50%), followed by Hemiglossectomy with modified radical neck dissection done in 8 (26.67%) patients. While wide local excision with

Hemimandibulectomy done in 2 (6.67%) patients (Fig 3g) and wide local excision with radical neck dissection done in 3 (10%) patients. Only 1 (3.33%) patient underwent wide local excision (Figure 2).

Figure 2: Distribution of patients according to surgical approach



In present study all 30 patients underwent surgery with reconstruction done in 12 patients with PMMC flap (Fig 3h and 3i), out of which 4 (13.33%) patients had marginal flap necrosis (Fig 3j) and 5 (16.67%) had partial flap necrosis. The most common complication encountered was stitch infection in 6 (20%) patients while 3 (10%) patients had developed seroma at operative site but 12 (40%) patients had no complications at operative site. Out of 30 patients 2 patient died during follow up, 2 patients had oroutineous fistula, 1 patient had dysphagia while 1 patient had recurrence (Fig 3k). 24 (80%) patients had no complications during follow up. Mortality of patient is due to poor general condition and old age (Table 2).

Table 2: Distribution of patients according to postoperative early and late complications

Post Op early complications	No of patients	Percentage
Marginal Flap Necrosis	4	13.33%
Partial Flap Necrosis	5	16.67%
Total flap necrosis	0	0
Hematoma	0	0
Infection	6	20%
Seroma	3	10%
No complications	12	40%
Late complications		
Recurrence	1	3.33%
Dysphagia	1	3.33%
Orocutaneous Fistula	2	6.67%
Mortality	2	6.67%
no complications	24	80%

As regards to surgical outcomes of the study, 22 (73.33%) patients were satisfied with surgical procedures and not having disfigurement but 8 (26.67%) patients were not satisfied with surgical procedure because of flap necrosis, recurrence wound infection and seroma formation.

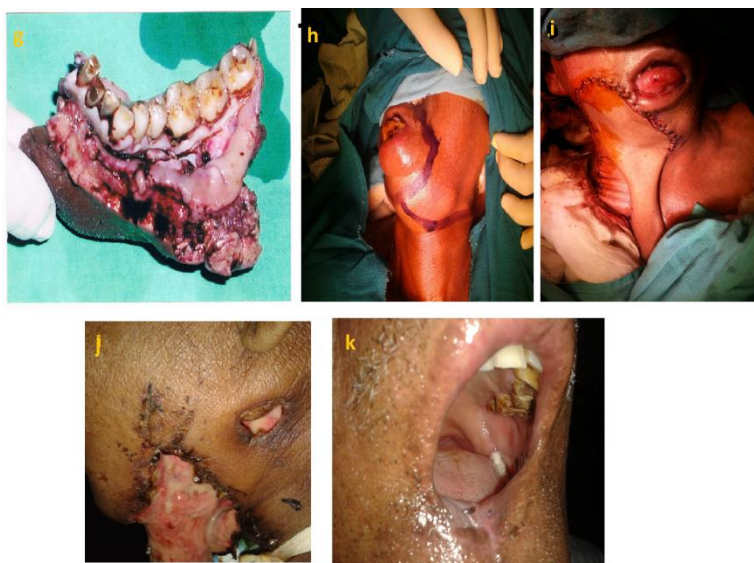

Figure 3: g) Specimen of mandible after hemimandibulectomy in patient of carcinoma of Alveolus, h) Y shape incision taken for reconstruction, i) Intro operative image of PMMC flap in patient of Carcinoma buccal mucosa, j) Marginal flap necrosis seen after reconstruction with PMMC flap, k) Recurrence seen in operated case of carcinoma buccal mucosa

4. Discussion

In India, cancer of the oral cavity and oropharynx is the commonest cancer in men and third commonest cancer in women [12]. Oral cancers are more common in males than females; however there is a rise in the incidence of these malignancies in females. In our study, majority (60%) were males with a male to female ratio of 3:2. This ratio was seen in most of the published studies [13,14] in India. Gender is not a risk factor per se in oral malignancies. The difference may be due to the high rate of tobacco and alcohol consumption among males. Moreover tobacco is consumed in both smoking and chewing form in males whereas in our society females are usually not indulged in smoking. This can also be attributed to more males seeking early medical consultation. As study is being conducted in rural setup where women's were offend offers medical care as compared to male. Women's are shy and afraid to show there dieses in tertiary care hospital. Most of the current study participants were between 51-60 (46.67%) years of age group, followed by 31-40 (20%) years and 71-80 (13.33%) years. Mean age of the patients was 55.46 years.

According to Abhinandan *et al* [15], the commonest age group affected was 6th decade (31.13% cases); 22.8% cases were in the 4th and 18% in 5th decade. In a study by Ahluwalia *et al* [16] the peak incidence was noted among males in 6th decade of life (40.89%), while in females it was 5th decade comprising 37.31% case. Patel *et al* [13] reported that 12.9% of oral and oropharyngeal malignancies were below 35 years of age, 23.8% between 35 and 45, and 63.3% cases over 45 years of age. The mean age reported in a study done by Durazzo *et al* [17] was 57.4 years and only 8.6% of the patients were 40 years or less. In conclusion, oral cancer commonly occurs in 5th-6th decade of life. Though the incidence below 40 years is relatively low, they are not completely spared. Total 30 patients were selected for the study, from which 44.33% of patients had agriculture work, 20 % of patients had house hold work, 16.66% were labourers and 10 % of patients having business occupation and 10 % patient had office work, this was compatible with different study [9,18]. The low socioeconomic status may be a risk factor for poor oral hygiene thereby further increasing the risk of oral cancer in tobacco chewers.

Among 30 patients oral cavity cancer 33.33% gave history of tobacco chewing, 10% of the patients were consuming smokeless tobacco in the form of pan, 20% of the patients consuming both smoking and alcohol, 6.67% were consuming smoking, alcohol and tobacco, 6.67% patients consuming only alcohol and 20% of the patients consuming both alcohol and smoking. 10% of the patients did not have any habits. So in present study tobacco was the most common risk factor associated with oral cancer which

was comparable with various studies [9,18]. Tobacco chewing has emerged as a stronger risk factor of oral carcinoma than smoking, since there is a direct exposure of tobacco chewing on the mucosa for longer period, while smoking has more contact with pharynx, larynx, and lungs. Women have substantially high level of chewing habits than men in many rural areas, as they believe that tobacco has magical and medicinal properties [12,19].

Any growth or ulcer in the oral cavity should have a high index of suspicion and should be further investigated. Site of involvement in oral malignancy has a variable geographical distribution. In our study, buccal mucosa was the commonest site of oral cancer, comprising 50% cases, followed by oral tongue in 30% and then lip in 13.33%. Other site was alveolus (6.67%). More and D'cruz, in their review of oral malignancies across India, noticed buccal mucosa is the commonest site [20]. It is also observed that oral cancer affects mainly the anterior parts (buccal mucosa, anterior 2/3 of the tongue, alveolus) of oral cavity. Anterior part of the oral cavity is the area that comes largely in contact with the smokeless tobacco while chewing. Smokeless tobacco, which has carcinogenic agents like carbon monoxide, nicotine, hydrogen cyanide, ammonia, benzyl, phenol, benzanthrene and benzopyrene, on chewing can cause chronic inflammation and carcinogenesis [13]. In our study growth was most common presenting symptom and ulcer was second most common presenting symptom, this was comparable with the study of Bhat *et al* [21] and Jashvanth *et al* [22]. The maximum number of patients i.e. 93.33% had N 0 lymph node status while 6.67 % of patients had N1 status of lymph node, the difference between present study and Jashvanth *et al* [22] study could be attributed to the patient inclusion criteria. 17 patients of our study had stage 2 oral cancers, 11 patients had stage 1 oral cancer and only 2 patients had stage 3 oral cancer. Most of the patients of oral cancer from stage 1 and stage 2. The stage 3 and stage 4 oral cancer cases were purposefully avoided because of technical difficulty in reconstruction and lack of facility in our institution. This was comparable with previous studies [9,23].

Surgical procedures were done according to the site, size, stage and lymph node status. Wide local excision with modified radical neck dissection was the primary procedure done in maximum number of 15 patients (50%), Hemiglossectomy with modified radical neck dissection done in 8 patients (26.67%), while hemimandibulectomy with wide local excision done in 2 patients (6.67%), wide local excision with radical neck dissection done in 3 patients (10%), wide local excision done in only 1 patient. The 88.89% of patients underwent hemiglossectomy with MRND while 11.21% of patients had hemiglossectomy with RND. The present study was comparable with the study of

Rana M *et al* [24]. Out of 30 patients diagnosed with squamous cell carcinoma of oral cavity in which 4 patient with lip cancer 25% of patients under went Wide local excision and 75% patients underwent Wide local excision with Neck dissection. Similar result found in study done by Moretti A *et al* [25]. Out of 30 patients, 28 were in stage 1 and stage 2 all patients underwent surgery alone (93.33%), 2 patient had infiltration in alveolus and every patient underwent wide local excision with hemi- mandibulectomy with neck dissection.

All patients underwent surgery, reconstruction done in 12 patients with PMMC flap. 4 patients (13.33%) had marginal flap necrosis and 5 patients (16.67%) had partial flap necrosis. Early postoperative complications i.e. stitch infection and developed seroma at operative site observed in 6 and 3 patients respectively. 21 patients (70%) had no complications at operative site. Reconstruction with PMMC Flap shows less complication rate in our study and in study of Lekawale H *et al* [26] favours use of PMMC flap for reconstruction in rural setup as well. The 80% of patient had no late postoperative complications, recurrence observed in 3.33% of patients, Dysphagia in 3.33% of patients while 6.67% had orocutaneous fistula and 6.67% of patients had post operative mortality. Most of the patients (22, 73.33%) were satisfied with surgical procedures but 8 (26.67%) patients were not satisfies because of late postoperative complications.

5. Conclusion

The prevalence of oral cancer was higher among elderly males predominantly with risk habits of various forms tobacco consumption. There is a rising incidence of oral cancers noted in female patients as they are hardcore tobacco chewers and less educated than men in the rural setup. As well it is increasing in younger population due to the habit of consuming alcohol and tobacco. Agriculturists were more vulnerable to oral malignancy in rural area. Cheek (buccal mucosa) was the commonest site involved, followed by tongue, possibly due to the longer duration of contact with the carcinogens in tobacco and alcohol. Wide local excision with modified radical neck dissection was most common surgical procedure done in present study. A surgical excision with wide margins and appropriate reconstruction is necessary to optimize the disease and functional outcome. Most of the patients were satisfied with post operative appearance after reconstruction indicating feasibility of surgery resection, nodal dissection with reconstruction at tertiary care hospital with limited resources.

Acknowledgement

The authors sincerely thank the department staff members, other staff of operation theatre for their support and cooperation. As well authors would like to thank administration of Shri V. N. Government Medical College, Yavatmal, Maharashtra, for permission to study and providing facility to carry out the work.

Reference

- [1] Petersen PE. Strengthening the prevention of oral cancer: the WHO perspective. *Community Dentistry Oral Epidemiology* 2005; 33:397-399.
- [2] Ahluwalia H, Gupta S.C., Singh M, Mishra V, Singh P.A., Walia D.K. Spectrum of Head and Neck Malignancies in Allahabad. *Indian Journal of Otolaryngology and Head and Neck Surgery*, January - March 2001; 53(1):16-21.
- [3] Elango JK, Gangadharan P, Sumithra S, and Kuriakose MA. Trends of head and neck cancers in urban and rural India. *Asian Pac J Cancer Prev*. 2006 Jan-Mar; 7(1):108-12.
- [4] Chaturvedi AK, Anderson WF, Lortet-Tieulent J, *et al*. Worldwide Trends in Incidence Rates for Oral Cavity and Oropharyngeal Cancers. *Journal of Clinical Oncology*. 2013; 31(36):4550-4559. doi:10.1200/JCO.2013.50.3870.
- [5] PLopez Jornet, FJ Gomez Garcia, M Lucero Berdugo, F Parra Perez. A Pons-Fuster Lopez, "Mouth self-examination in a population at risk of oral cancer" *Australian Dental Journal* 2015; 60(1):59-64. DOI: 10.1111/adj.12274
- [6] Wen-Jiun Lin, Rong-San Jiang, Shang-Heng Wu, Fun-Jou Chen, and Shih-An Liu, "Smoking, Alcohol, and Betel Quid and Oral Cancer: A Prospective Cohort Study," *Journal of Oncology*, vol. 2011, Article ID 525976, 5 pages, 2011. doi:10.1155/2011/525976.
- [7] Sankaranarayanan R, Ramadas K, Thomas G *et al*. Effects of Screening on Oral Cancer Mortality in Kerala, India: A Cluster Randomized Controlled Trial, *The Lancet*. 2005; 365(9475):1927-1933.
- [8] Manoharan N, Tyagi BB, Raina V. Cancer incidences in rural Delhi -2004-2005. *Asian Pacific Journal of Cancer Prevention*. 2010; 11(1):73-78.
- [9] Khandekar SP, Bagdey PS, Tiwari RR. Oral cancer and some epidemiological factors: a hospital based study. *Indian Journal of Community Medicine*. July-September 2006; 31(3):157-159.

- [10] Kumar S, Hellar RF, Pandey U, Tewari V. *et al.* Delay In Presentation Of Oral Cancer: A Multifactor Analytic Study *Nation Medical Journal Of India.* 2001; 14(1):13-17.
- [11] Takácsi-Nagy Z, Oberna F, Somogyi A, Polgár Cs, Major T, Németh Gy: Experiences in the treatment of tumour of base of the tongue with high dose rate interstitial radiotherapy on the basis of a retrospective analysis *Magyar Onkológia.* 2000; 44: 117-121.
- [12] Balaram P, Sridhar H, Rajkumar T, Vaccarella S, Herrero R, Nandakumar A, *et al.* Oral cancer in Southern India: The influence of smoking, drinking, pan chewing and oral hygiene. *Int J Cancer* 2002; 98:440-445.
- [13] Patel MM and Pandya AN. Relationship of oral cancer with age, sex, site distribution and habits. *Indian J Pathol Microbiol* 2004; 47(2): 195-197.
- [14] Bhattacharjee A, Chakraborty A, Purkaystha P. Prevalence of head and neck cancers in North East – An institutional study. *Indian J Otolaryngol Head Neck Surg* 2006; 58(1): 15-19.
- [15] Abhinandan B, Chakraborty A, Purkaystha P. Prevalence of head and neck cancers in the North East- An institutional study. *Indian J Otolaryngol Head Neck Surg* 2006; 58:15-19.
- [16] Ahluwalia H, Gupta SC, Singh M, Gupta SC, Mishra V, Singh PA, *et al.* Spectrum of Head -Neck cancers at Allahabad. *Indian J Otolaryngol Head Neck Surg* 2001; 53(1):16-21.
- [17] Durazzo MD, Araujo CEN, Neto JSB, Potenza AS, Costa Pedro, Takeda F *et al.* clinical and epidemiological features of oral cancer in a medical school teaching hospital from 1994 to 2002: increasing incidence in women, predominance of advanced local disease, and low incidence of neck metastases. *Clinics* 2005; 60(4):293-298.
- [18] Mehrotra R, Singh M, Kumar D, Pandey AN, Gupta RK, Sinha US. Age specific incidence rate and pathological spectrum of oral cancer in Allahabad. *Indian J Med Sci* 2003; 57 (9): 400-4.
- [19] Muwonge R, Ramadas K, Sankila R, Thara S, Thomas G, Vinoda J, *et al.* Role of tobacco smoking, chewing and alcohol drinking in the risk of oral cancer in Trivandrum, India: A nested case-control design using incident cancer cases. *Oral oncol* 2008; 44: 446-454.
- [20] More Y, D'cruz A. Oral cancer: Review of current management strategies. *Natl Med J India.* 2013; 26(3):152-8.
- [21] Bhat SP, Naik R, Swetadri DK, D'souza H Jayprakash CS, Bhat V. Clinicopathological Spectrum of Malignancies Of Oral cavity And Oropharynx-Our Experience In Referral Hospital *World Articles In ENT.* 2010;3(1).
- [22] Jashvanth G, Murali K, Kasa S, Ramesh K. A Study on Clinical Presentations of Oral Cancer at Tertiary Care Hospital, Bellary, Karnataka. *IJSR* 2014; 3(7):234.
- [23] Malhotra A *et al.* Demographic, Histopathological Patterns and Clinical profile of Oral Squamous Cell Carcinoma (OSCC) at a tertiary level referral Hospital in Vidarbha (Central India): A 7-year Retrospective Study. Nov 2014; 13(II):53-56.
- [24] Rana M *et al.* Modern surgical management of tongue carcinoma-A clinical retrospective research over a 12 years period. *Head and neck oncology* 2011; 3; 43.
- [25] Moretti A, Vitullo F, Augurio A, *et al.* Surgical Management of Lip Cancer. *Acta Otorhinolaryngol Ital.* 2011; 31:5-10.
- [26] Lekawale H, Patil B. Pectoralis Major Myocutaneous Flap for Oral Cavity Cancer Reconstruction - Our Experience with 30 Cases. *Ind Journ of Appl Resear* 2012; 2(3):159-161.