

Surgical anatomy of external branch of superior laryngeal nerve (EBSLN) in thyroid surgery

Arfath Mustafa* and Bhagyashree Bokare

Department of ENT, Government Medical College, Nagpur, Maharashtra, India- 440001

*Correspondence Info:

Dr. Arfath Mustafa,
Consultant Ent and Head, Neck surgeon,
Sri Harihar Hospital and Research Centre
Nh 21, Vpo Gutkar, Mandi, Himachal Pradesh-175021
E-mail: arfathent@gmail.com

Abstract

Aim and objective: To study the anatomic variations of the external branch of superior laryngeal nerve & to propose a systemic approach to identification and preservation of this nerve during thyroid surgery.

Methods: In the present study total 90 cases of thyroid diseases were treated with surgery, in the department of ENT at a tertiary care hospital, over a period of 2 years. Hemithyroidectomy was the most common operative procedure implemented in 63 patients (70%) among which right sided was more common (58.7%). Next common procedure performed was that of total thyroidectomy in 27 patients (30%). The position of EBSLN was classified according to the Cernea's classification.

Results: A total number of 88 EBSLN were identified and majority of EBSLN were found to be type II a variant i.e. 59% followed by type I variant (25%) and type II b variant (16%). In about 18 patients, EBSLN was not identified.

Conclusion: In our study the surgeons can be sensitized about EBSLN anatomic variations, anatomic variation taken into consideration to identify EBSLN during thyroid surgery. Preservation of the EBSLN maintains optimal function of the larynx.

Keywords: External branch of superior laryngeal nerve, thyroidectomy, Hemithyroidectomy

1. Introduction

The basic principle of head and neck surgery is based on the identification and preservation of important structures, rather than avoidance. This principle is also applicable to identification and preservation of external branch of the superior laryngeal nerve (EBSLN) as a standard routine in all thyroid surgeries. External Branch of Superior Laryngeal Nerve (EBSLN) supplies the cricothyroid muscle which is the main tensor of the vocal cord. Injury to the EBSLN during surgery can result in the voice changes, loss of upper range and easy fatigability of voice, the severity of which varies according to the vocal demand of the patient. Refinement in surgical techniques, recognition of the importance of parathyroid, recurrent laryngeal nerve, external branch of superior laryngeal nerve, need to protect them result in lesser morbidity.[1]

Iatrogenic injuries to EBSLN are not infrequent due to anatomical variation of relationship of this nerve with superior thyroid vessels. The reported risk of EBSLN injury in the literature varies from 0.3 to 13%[2]. Paralysis of the superior laryngeal nerve can significantly affect those whose career depends heavily on full range of voice. Even at present, available data on the exact topography of the EBSLN is sporadic and variable. So considering anatomic variation

and careful dissection this often neglected nerve during thyroidectomies will help to spare annoying and permanent symptoms of injuries to EBSLN.

The present study focuses on intra operative identification and preservation of EBSLN during thyroid surgery. The importance of voice in today's world cannot be understated and with more people depending on their voice for livelihood by preventing damage to the EBSLN, possible voice symptoms post thyroidectomy can be prevented.

2. Materials and Methods

The design was a prospective study enrolling ninety patients of thyroid swelling were treated in the department of ENT at Tertiary care hospital during the period from September 2012 to September 2014. The study was of 2 years duration. Exclusion criteria include malignancy of thyroid with extra thyroidal spread affecting the course of the nerve, revision surgery that may have altered the course of nerve due to fibrosis. Once the patient was selected for the study, an informed written consent was taken and a detailed history and clinical examination was done according to proforma. Laryngoscopic examination, fundamental frequency of voice (Fo) was recorded to document preoperative status of

EBSLN. Also other necessary investigations were done and the patients fit for surgery were posted for surgery

After taking all aseptic precautions, under general anaesthesia patient was given horizontal skin incision of around 1 to 2 cms above the suprasternal notch. Sub platysmal flap was elevated and gland was exposed by separating strap muscles in the midline laterally. If gland was found to be too large then strap muscles were cut. Dissection was started from middle of the thyroid gland. In the center, after identifying middle thyroid vein it was clamped, cut and ligated after adequate exposure, dissection of superior pole was carried out. Adequate mopping of surgical field was done for better visualisation. We followed below mentioned approach to protect the SLN- Medial and lateral borders of the superior pole were mobilized. The lateral retraction of the strap muscles and the carotid sheath and the medial retraction of the thyroid were done to allow blunt dissection of the largely avascular investing fascia to expose the lateral aspect of the superior pole. The upper pole was then retracted laterally while the cricothyroid muscles and larynx were pushed medially. The intent was to pull the upper pole out and away from course of SLN. There are often 1 or more blood vessels that pass transversely through this plane of dissection and they were ligated and divided to free the medial aspect of the superior pole, mobilizing the upper pole pedicle. The individual branches of the superior thyroid vessels were divided as low as possible as they entered the thyroid capsule. This lessened the potential for injury to the nerves at risk as it minimized the problem of the proximity of the vessels to the nerve. When taking down the superior pole, any tissue that had a vertical orientation that could be pushed medially away from the upper pole tissue was pushed away to avoid injury to the SLN. After identifying SLN, in space medial to superior pole, its branch EBSLN was seen entering cricothyroid muscle. Distance between EBSLN and upper pole of thyroid was measured with the help of caliper.

On post operative period on day 7th, 1st month and 3rd month fundamental frequency of voice was also recorded.

3. Results

Total 90 patients of age between 16-68 years were enrolled for the study that underwent thyroid surgery. The highest number of patients were found to be in the age group of 21-30 years (55%) i.e. in second and third decade of life, in accordance with the study conducted by Estrela *et al* followed by 31-40 years.[3] As far as gender distribution was concerned, 68 patients were female (75.5%) and 22 patients were males (24.5%). Male to female ratio was 1:3. Majority of the patients had solitary thyroid swelling 71 (78.88%) while only 19 (21.12%) patients had multinodular swelling. Most common histological type found on FNAC was colloid goitre (53%). Maximum number of patients, i.e. 63 (70%) patients, underwent hemithyroidectomy. 27 (30%) patients underwent total thyroidectomy. Out of total 63

hemithyroidectomy patients, 58.7% of patients had undergone right side hemithyroidectomy while 41.3% patients had undergone left side hemithyroidectomy.

The pitch of voice gets lowered due to injury to EBSLN. This can affect women much more than men. The EBSLN was identified in all the patients irrespective of the etiology and type of thyroid disease. Total of 88 EBSLN were identified and majority of EBSLN i.e.; 52 out of 59 (59%) were found to be type II a variant followed by type I variant (25%) and type II b variant (16%). In about 18 patients, EBSLN was not identified. However, the identified EBSLN variant i.e. type I, type IIa and type IIb variant were shown in following figures.

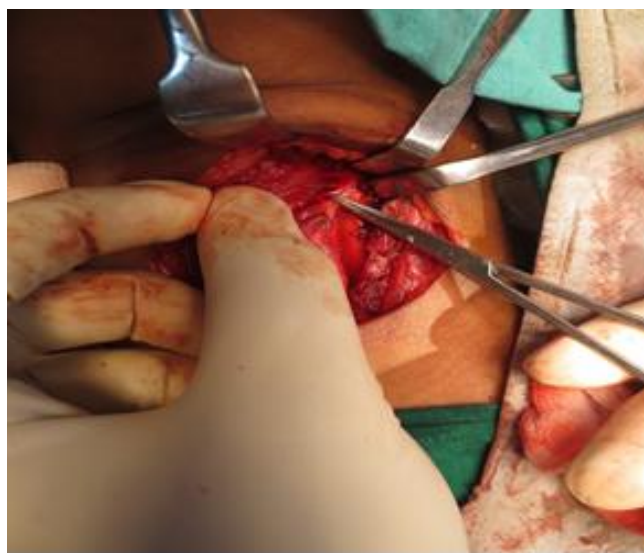


Figure 1: It depicts medial thyroid space with the type I EBSLN.

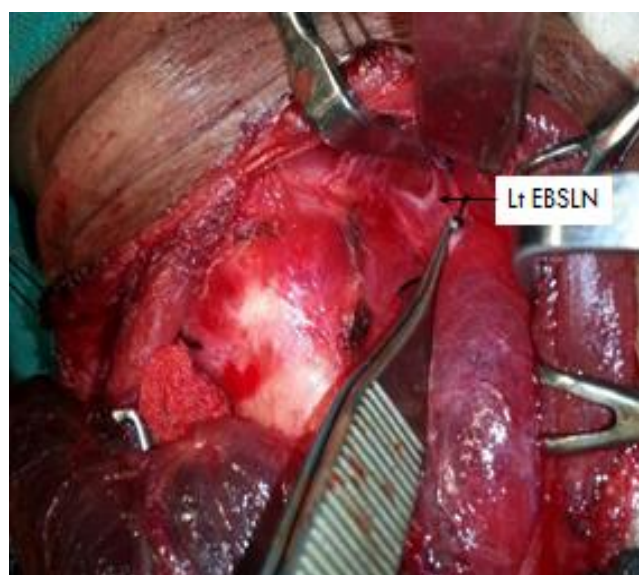


Figure 2: It depicts type II a EBSLN. Its course is very close to the superior pole of thyroid.

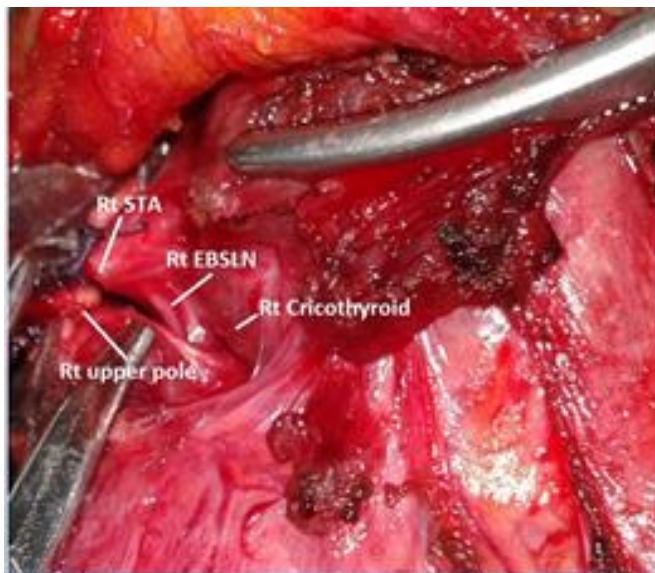


Figure 3: It depicts type II b EBSLN.

Out of total 90 thyroidectomy patients, 50 patients showed drop in fundamental frequency on post operative day 7 and out of these 50 patients, 38 (76%) patients showed recovery of fundamental frequency drop in voice after 1 month (post-operatively), while 12 (24%) patients showed permanent drop in fo. We found 16 patients with unidentified EBSLN, out of which 10 patients (62.5%) showed permanent drop in fundamental frequency of voice post operatively, while 6 (37.5%) patients didn't show permanent drop in fundamental frequency of voice. Also the 72 (97.30 %) patients with EBSLN identified intra-operatively showed no drop in fundamental frequency of voice, while 2 (2.70%) showed permanent drop in fo with nerve identified which was type II b.

4. Discussion

Most studies have emphasized the importance of preservation of the Recurrent Laryngeal Nerve during thyroidectomy. Nevertheless, knowledge of intra-operative localization and anatomical variations of the External Branch of the Superior Laryngeal Nerve (EBSLN) is essential for surgeons who perform operations on the thyroid gland to prevent intra-operative injury to it during thyroid surgery.

Although iatrogenic injury to nerve is one of the most commonly encountered post surgical complication of thyroid surgery. But iatrogenic injury to EBSLN during thyroid surgery is often overlooked as the patient is usually asymptomatic depending on the range of voice used, and due to compensatory mechanism it usually goes undiagnosed until the person is professional voice user. Sometimes patients may experience voice weakening, hoarseness and may typically complain of voice fatigue towards the evening. The injury may be catastrophic to those who use their voice professionally such as singers and public speakers. Careful and meticulous dissection is imperative to avoid injury to the

nerve. It is also important to have adequate knowledge of the anatomical variations of the course of the nerve. Although most surgeons tend to avoid rather than to expose the nerve, injury of the low-lying EBSLN with the superior thyroid artery would be inevitable.[4]

Even though various classification have been given in different studies of EBSLN but Cernea classification, is one of the most popular classifications worldwide of the EBSLN.[5] In the present study surgical anatomy of EBSLN and its variation during thyroid surgery was correlates with Cernea classification. The anatomic course, relationship & branching pattern of EBSLN beyond the operative field was not included i.e its origin from inferior no dose ganglion of vagus, to its termination into cricothyroid muscle and dissection through inferior constrictor muscle. Also the proximal & distal course of this nerve apart from operative field was not studied.

The type I variant of EBSLN (which crosses STA > 1 cm above upper pole of thyroid gland) was seen in 22 (25%) patients unlike the findings of Aina *et al*[1] and Hwang *et al*[6], who reported lower prevalence of type I variant i.e 17.8% and 16.3% respectively. However, type II a variant of EBSLN (which crosses STA < 1cm above upper pole) was seen in 52 (59%) patients. the percentage of type II a variant as reported by Aina *et al*[1] was lower i.e., 44.4% while Hwang *et al*[6] found it to be 56.5%. Also the type II b variant of EBSLN (which crosses STA undercover of upper pole) was seen in 14 (16%) patients. We found lower percentage of this variant as compared to findings of Aina *et al*[1] and Hwang *et al*[6] who found it to be 37.8% and 27.2% respectively.

All the patients were subjected to video laryngoscopy before and after the surgery. Also the fundamental frequency of voice before and after the surgery was assessed to evaluate the intact function of cricothyroid muscle which is supplied by EBSLN. Voice Analysis of all patients was done pre and post-operatively. Fundamental frequency Fo on post-operative day 7th, 1st & 3rd month was measured and compared, which showed drop in fundamental frequency of approximately 30-40 Hz in about 50 patients on post-operative day 7.

In the present research majority of thyroid diseases were solitary thyroid swelling with colloid goitre as most common histological type. Right hemithyroidectomy was the commonly performed surgical procedure. Type II a variant of EBSLN was most commonly seen (based on Cernea's classification). Prevalence of type II (II a and II b) variant of EBSLN was likely to increase with the increase in the size of gland. We understand that Type II (II a and II b) variant of EBSLN was found to be at greater risk of injury during surgical procedure as it is closer to the thyroid gland. Also the significant number of cases with unidentified EBSLN showed drop in fundamental frequency of voice Fo.

5. Conclusion

Through this study, the surgeons can be sensitized about EBSLN anatomic variations. Therefore anatomic variation has taken into consideration to identify EBSLN during thyroid surgery. Preservation of the EBSLN maintains optimal function of the larynx that's why identification and preservation of EBSLN was needed in the study.

The sample studied in this research was not sufficient to represent the entire population. Larger sample size would further help in understanding the anatomic variations of EBSLN, hence guiding the surgeon to take adequate measures to identify and preserve the nerve.

Acknowledgement

The authors would like to thank the department of ENT, surgery, other staff of operation theatre and administration of Government Medical College, Nagpur, Maharashtra, for permission to study and providing facility to carry out the work.

Reference

- [1] Aina EN, Hisham AN. External laryngeal nerve in thyroidsurgery: recognition and surgical implications. *ANZ J Surg* 2001; 71:212e214.
- [2] Choksy SA, Nicolson ML. Prevention of voice change in singersundergoing thyroidectomy by using a nerve stimulator to identify the external laryngeal nerve. *Br J Surg* 1996; 83: 1131-2.
- [3] Moosman DA, Weese MS. The external laryngeal nerve as related tothyroidectomy. *Surgery Gynecology and Obstetrics* 1968; 127(5):1011–1016.
- [4] Pulakunta T, Potu BK, Rao MS, Vollala VR, Nayak SR. Unusual external branch of thesuperior laryngeal nerve: A case report. *Cases J.* 2009; 11(2): 7754.
- [5] Jansson S, Tisell LE, Hagne I, Sanner E, Stenborg R, Svensson P. Partial superiorlaryngeal nerve (SLN) lesions before and after thyroid surgery. *World J Surg* 1988; 12:521-7.
- [6] Hwan Hong *et al.* Functional differences between the two bellies of the cricothyroidmuscle. *Otolaryngology Head and Neck Surgery* 1998; 118:714-22.