

Proximal Femoral Nailing vs. Dynamic Hip Screw in unstable Intertrochanteric Fracture of Femur – A comparative analysis

Mohammad Faisal^{*1} and Prithviraj Nistane²

¹(MS Orth), Associate Professor and Head of Unit, Department of Orthopaedics, Indira Gandhi Govt. Medical College, CA Road, Nagpur, Maharashtra, India

²(MS, DNB Orth), Assistant Professor, Department of Orthopaedics, Indira Gandhi Govt. Medical College, CA Road, Nagpur, Maharashtra, India

*Correspondence Info:

Dr. Mohammad Faisal, (MS Orth)

Prime Nursing Home,

25, Ahabab Colony, in front of Anant Nagar bus stop,

Behind Police Line, Takli, Nagpur-13, Maharashtra, India

E mail: drfaisalm@gmail.com

Abstract

Inter-trochanteric (IT) fractures account for approximately half of the hip fractures in elderly; out of this, more than 50% fractures are unstable. The Dynamic Hip Screw (DHS) had gained widespread acceptance in previous decades. DHS has been shown to produce good results but complications are frequent, particularly in unstable inter-trochanteric fracture. The advantage of Proximal Femur Nailing (PFN) fixation is that it provides a more biomechanically stable construct by reducing the distance between hip joint and implant. The goal of this study is to compare the clinical and radiological outcomes of DHS and PFN for the treatment of unstable Intertrochanteric hip fractures.

In our study we included 100 unstable intertrochanteric fractures, out of which 50 were treated with PFN and 50 were treated with DHS. All surgeries were done on traction table and were followed up at regular intervals at 4 weeks, 8 weeks, 12 weeks, 6 months and annually thereafter. The functional results were assessed with Harris Hip Score. At latest follow up, Patients with excellent results were 33 (66%) in group A and 18 (36%) in group B while patients with good results were 14(28%) in group A and 27(54%) in group B. We observed statistically significant difference between two groups in view of late & early complications and time to union. We observed significantly better outcomes in PFN group for unstable inter-trochanteric fractures and reduction loss was significantly lower. We concluded that PFN may be the better fixation device for most unstable inter-trochanteric fractures.

Keywords: Inter-trochanteric fractures, DHS, PFN

1. Introduction

Inter-trochanteric (IT) fractures account for approximately half of the hip fractures in elderly; out of this more than 50% fractures are unstable [1,2]. These fractures primarily involve cortical and compact cancellous trochanteric bone. Because of the complex stress configuration and its non-homogeneous osseous structure and geometry, fractures occur along the path of least resistance. It is predicted that the yearly total number of hip fractures will reach 2.6 million by 2025 and 4.5 million by 2050 [2]. In 1990 26% of all hip fractures occurred in Asia alone whereas this figure could rise to 37% in 2025 and 45% in 2050 [3].

The goal of treatment of any IT fracture is to restore mobility efficiently while minimizing the risk of complications and restoring the patient to pre-operative status. Treatment options for intertrochanteric fractures are mostly operative. Non-operative methods were used in early

19th century when the operative technique was not evolved enough for a stable fixation. Non-operative treatment should only be considered in non-ambulatory, chronic dementia patients, terminal diseases with less than 6 weeks of life expectancy, unresolved medical comorbidities, active infectious disease etc. Unstable IT fractures can be managed by either Dynamic Hip Screw (DHS) or Proximal Femoral Nailing (PFN). DHS has gained widespread acceptance and has produced good results but complications are frequent, particularly in unstable inter-trochanteric fracture. The advantage of PFN is that it provides a more biomechanically stable construct by reducing the distance between hip joint and implant [4, 5]. While DHS is a load bearing implant, PFN is a load sharing one. Each implant offers certain advantages over the other.

Hence we conducted a study in our tertiary care centre to compare the clinical and radiological outcomes of

treatment of unstable IT fractures by either of these two methods, i.e. proximal femoral nailing (PFN) and dynamic hip screw (DHS). The objectives of this study were -

- 1) To compare DHS and PFN methods of fixation of unstable IT fracture of femur in adults with respect to intra operative parameters
- 2) To compare the functional outcome with respect to fracture union, functional return, and complications in the two groups.
- 3) To determine which implant would be ideal for this fracture type so as to provide the best results with the least complications.
- 4) To study long-term follow up of the two groups with respect to any residual impairment of function and overall tolerability of implant.

2. Materials and Methods

A double blind randomized control study was conducted on the patients with unstable IT fractures admitted in the orthopedics department. Ethical clearance was obtained from the institutional ethics committee. The study period was 2 year from April 2014 to April 2016. The study was conducted among the study population after obtaining written informed consent. Our study population consisted of 100 patients (50 in each group). Out of 100 cases, 50 were treated by proximal femoral nailing (PFN-group A) and 50 were treated by dynamic hip screw (DHS-group B). The allocation of patients in either group was done randomly. AO/OTA classification for per trochanteric fractures was used. According to AO/OTA classification -

- 31A1** - fractures are simple, two-part fractures,
- 31A2** - fractures have multiple fragments
- 31A3** - fractures includes reverse oblique and transverse fracture patterns

2.1 Inclusion criteria

- 1) Patients who were in the age group of more than 50 years of either sex
- 2) Unstable Intertrochanteric fracture type 31-A 1/2/3 (OTA classification)

2.2 Exclusion criteria

- 1) Patients unfit for the surgery
- 2) Open/ pathological/ bilateral fractures
- 3) Patients who had less than 2 years of follow-up
- 4) Polytrauma patients
- 5) Pre-existing hip/femoral deformity
- 6) Sub-trochanteric fractures

The relevant information was collected from all included patients like history, general, systemic and local examination findings. Initial radio-graph of the hip joint was conducted besides routine pre anesthetic evaluations. The 100 patients were divided in to two groups, 50 in each. The division of the patients in these groups was random. The patients under group A were treated by PFN and patients under group B were treated by DHS. All the cases included in our study were operated after stabilization of general status as soon as possible. The average delay of surgery in our study was 4 days (mean 2-10 days). All surgeries were performed

on the traction table following closed reduction, confirmed with fluoroscopy on two different views.

For PFN, the nail diameter was determined by measuring diameter of the femur at the level of isthmus on an AP X-ray and a standard length PFN (250 mm) was used in all our cases. Neck shaft angle was measured in unaffected side in AP X-ray using goniometer. (as shown in figure 1- Pre-operative X ray and figure 2 – Post-operative X ray)

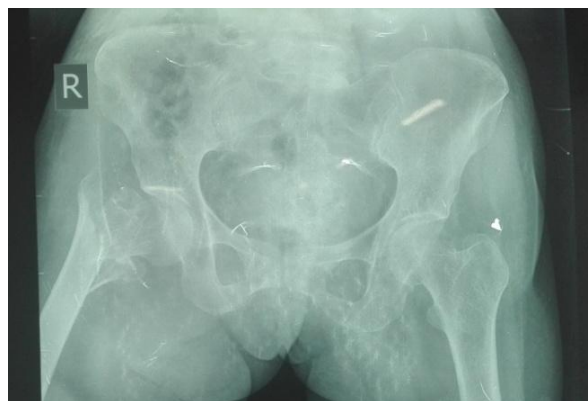

Figure 1: Pre-op - unstable IT fracture

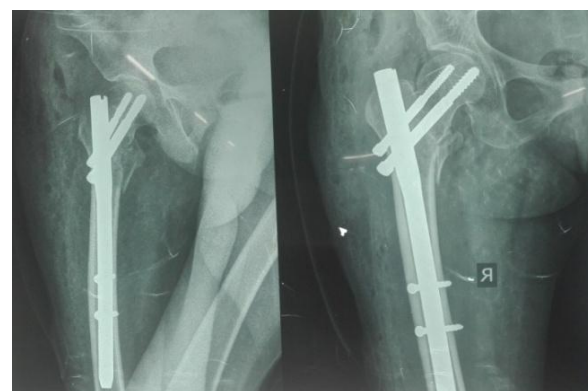


Figure 2: Post-op - Proximal femoral nailing

For DHS length of compression screw was measured from tip of the head to the base of greater trochanter on AP view X-ray. Neck shaft angle was determined using goniometer on X-ray AP view on unaffected side and length of side plate was determined to allow purchase of at least 8 cortices on the shaft, distal to the fracture. (As shown in figure 3-Pre-operative X ray and figure 4– Post-operative X ray)

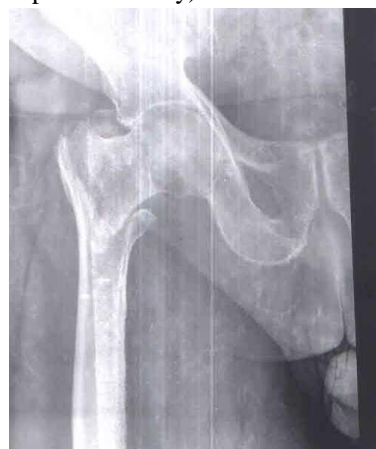

Figure 3: Pre-op - unstable IT fracture

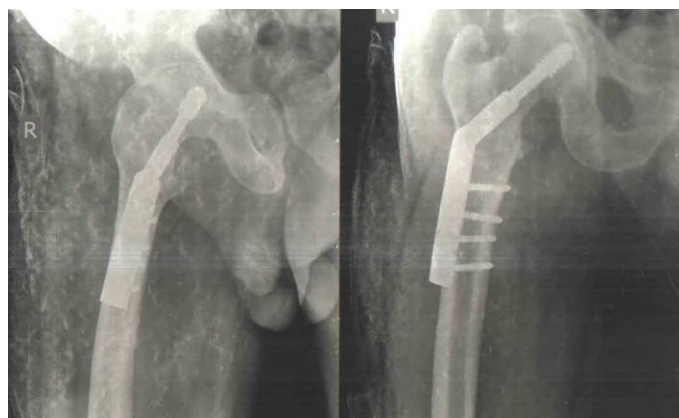

Figure 4: Post-op – Dynamic hip screw

Post-operatively, all patients were subjected to physical methods such as early mobilization. Patients were encouraged for ankle and calf exercises from day one and mobilized non-weight bearing from the second post-operative day depending upon pain tolerance of the patient. Surgical site suction drain was removed after 24 hr. The wound was inspected on the 3rd and 6th post-operative day. Stitches were removed on the 11th-13th day. Patients followed up at 4 weeks, 8 week, 12 weeks, 6 months and annually thereafter.

Various parameters assessed on each follow up visit were:

Clinical:

1. Wound condition
2. Functionality
3. Harris hip score

Radiological:

1. Union
2. Amount of collapse
3. Complication

Functional outcome was assessed with Harris Hip Scores on following parameters:

- Pain
- Limp
- Distance walked
- Support Sitting
- Enter public transportation
- Stairs
- Put on shoes and socks
- Absence of deformity
- Range of motion

Grading of Harris Hip Score:

- <70 Points - Poor
- 70-79 Points – Fair
- 80-89 Points - Good
- 90-100 Points - Excellent

3. Observations and Results

The study involved 100 cases of unstable IT femur fracture of either sex followed up from April 2014 to April 2016. Out of 100 cases, 50 were treated by PFN (group A) and 50 were treated by DHS (group B). . The results were

statistically analyzed using students-t test and the two tailed p values were evaluated.

In our study maximum age was 78 years and minimum was 51 years. The average age was 66.8 years. In either group, 26 were OTA 31-A2 and 24 were 31- A3 type fractures. The Singh’s index for osteoporosis showed that, both groups inclusive, there were 46 patients with grade 4 and above. In this study, Harris hip score at latest follow up was excellent in 33 patients (66%) in group A and 18 (36%) in group B, patients with good results were 14(28%) in group A and 27(54%) in group B, patients with fair results were 3(6%) in group A and 4 (8%) in group B and patients poor results were 1(2%) in group B and no patient with poor results in group A.(Table -1)

Table 1: Harris hip scores at latest follow up

Harris Hip score	PFN group	DHS group
Excellent	66%	36%
Good	28%	54%
Fair	6%	8%
Poor	nil	2%

In the D.H.S group, 1 month Harris hip score (mean = 24.5) was less than that of the P.F.N group (mean = 35.23) i.e. $p < 0.0001$. In 6 month, hip score in DHS (mean = 78.8) was also less than that of PFN (mean = 82.8), i.e. p value = 0.021. (Table 2)

Table 2: Comparative hip scores at serial follow up

Harris hip score	PFN group	DHS group
One month follow up	35.23	24.5
Six months follow up	82.8	78.8

A comparison of time to union demonstrated no statistically significant differences between study groups ($P=0.542$). Out of 22 A3 fractures, in group B reduction loss occurred in 6 hips and in group A it was seen in 2 cases. Thus in unstable IT fractures reduction loss is significantly lower in group A than group B ($p<0.005$).

Comparative analysis

- **Duration of Surgery:** Duration of surgery was more for DHS compared to PFN. The duration of surgery as calculated from the time of incision to skin closure was counted in each case. The average duration of surgery for the PFN (Avg. time 58.73 min) was significantly shorter than DHS (Avg. time 89.03 min), p value < 0.0001 .
- **Intra operative blood Loss:** Blood loss was measured by mop count and collection in suction drain. The average blood loss in the PFN group was 116 ml and in the DHS group was 253 ml. Blood loss was less in PFN which is statistically significant, p value < 0.0005 .
- **Intraoperative complications in PFN:** There was failure to achieve close reduction in 3 patients where open reduction was performed. There was no iatrogenic fracture, difficulties in distal locking or any other intra-operative complication.

- **Intraoperative complications in DHS:** In 4 of the 50 cases there was improper placement of Richard's screw. Difficulties were encountered in reverse oblique fractures as the fracture site extended to entry point. There was varus angulation in 5 of 50 patients. On table surgeon had to switch to PFN in 2 cases in reverse oblique fracture. These cases were considered with PFN group for further follow up.
- **Infection:** There were 3 cases of superficial infection seen in the DHS group. They were seen within 10 days of surgery and were treated by local debridement and antibiotics and did not require implant removal. No case of infection was seen in PFN group.
- **Sliding:** The sliding in both groups was compared at the end of 1 year on the X-rays as described by Hardy *et al*[3], there was an average of 5.50 mm of sliding in the P.F.N group as compared to 8.10 mm in the D.H.S group ($p < 0.0005$).
- **Shortening:** The average shortening in the PFN group was 5.35 mm as compared to 9.62 mm in the D.H.S group. So shortening is less in PFN group which is statistically significant. (p value < 0.0005)
- **Implant Failure:** There was 4 of 50 case of implant failure in P.F.N group and revision surgery was required for two of those. The 'Z' pattern of implant failure was seen in both. In the D.H.S group there were 2 of 50 cases of implant failure, of which one was due to screw cut out and other was due to plate breakage. In both the cases revision surgery was required.

4. Discussion

The development of the dynamic hip screw in the 1960s saw a revolution in the management of intertrochanteric fractures. The device allowed compression of the fracture site without complications of screw cut-out and implant breakage associated with a nail plate. However, the extensive surgical dissection, blood loss and surgical time required for this procedure often made it a contraindication in the elderly with co-morbidities. The implant also failed to give good results in unstable and the reverse oblique fractures.

In the early 90s intramedullary devices were developed for fixation of Intertrochanteric fractures. These devices had numerous biomechanical and biological advantages over the conventional dynamic hip screw [4-6]. Long term studies, however, revealed that the use of these devices was associated with higher intra operative and late complication often requiring revision surgery. This has led to modifications in the device and technique of the intramedullary devices.

In our study we found:

- Less operative time in PFN group
- Less operative blood loss in PFN group
- Early return to daily activities in PFN group
- Less complication in PFN group as compared to DHS group.

In contrast, the plate and screw device will weaken the bone mechanically. The common causes of fixation failure are instability of the fractures, osteoporosis, and the lack of anatomical reduction, failure of fixation device and in-correct placement of screws.

5. Conclusion

Though PFN and DHS have similar outcomes in stable fractures [3], PFN has better functional outcome with unstable fractures. PFN requires shorter operation time and lesser soft tissue dissection; it has distinct advantages over DHS even in stable inter-trochanteric fractures. Hence from our study it may be concluded that, PFN is better fixation device for most unstable intertrochanteric fractures.

References

- [1] Melton L J, Kearns A E, Atkinson E J *et al.* Secular Trends in Hip Fracture Incidence and Recurrence, *Osteoporosis International*; 2009; 20(5): 687- 694.
- [2] Gullberg B, Johnell O, Kanis A. World Wide Projection for Hip Fracture, *Osteoporosis International*; 1997; 7(5):407-413.
- [3] Hardy D, Descamps P, Krallis P *et al.* Use of an Intramedullary Hip Screw Compared with a Compression Hip Screw with a Plate for Intertrochanteric Femoral Fractures. A Prospective Randomized Study of One Hundred Patients, *The Journal of Bone & Joint Surgery* 1998; 80: 618-630
- [4] Carter D, Hayes W. The Compressive Behavior of Bone as a Two-Phase Porous Structure, *The Journal of Bone & Joint Surgery* 1977; 59A (7): 954-962.
- [5] Nuber S, Schoweiss T, Ruter A. Stabilization of unstable trochanteric femoral fractures: dynamic hip screw with trochanteric stabilization plate vs Proximal femoral nail, *Journal of orthopaedic trauma* 2003; 17(4): 316-317.
- [6] Steinberg E L, Nehemia N H, Shmuel D L *et al.* The fixation proximal femur nailing system: biomechanical properties of the nail and a cadaveric study, *Journal of Biomechanics*; 2005; 38: 63-68.