

## Rapidly growing *Mycobacterium*: A cause of post operative wound infection following a surgical procedure

Sheetal Bankar<sup>\*1</sup>, Reena Set<sup>2</sup>, Ashvini Khaparde<sup>3</sup> and Jayanthi Shastri<sup>4</sup>

<sup>1</sup>Assistant Professor, Department of Microbiology, TNMC & BYL Nair Ch. Hospital, Mumbai, India

<sup>2</sup>Professor (Addl.), Department of Microbiology, TNMC & BYL Nair Ch. Hospital, Mumbai, India

<sup>3</sup>Resident, Department of Microbiology, TNMC & BYL Nair Ch. Hospital, Mumbai, India

<sup>4</sup>Professor & Head, Department of Microbiology, TNMC & BYL Nair Ch. Hospital, Mumbai, India

### \*Correspondence Info:

Dr. Sheetal Bankar,  
Assistant Professor,  
Department of Microbiology,  
TNMC & BYL Nair Ch. Hospital, Mumbai, India  
E-mail: [drsheelat2000@gmail.com](mailto:drsheelat2000@gmail.com)

### Abstract

We report a case of postoperative wound infection due to *Mycobacterium fortuitum-chelonae* complex in a male patient who presented with induration and discharging sinuses over the flank, 15 days after he had undergone Percutaneous Nephrolithotomy (PCNL) for pelvic calculus. The seropurulent discharge from the wound showed acid-fast bacilli (AFB) on Ziehl-Neelsen stain and culture yielded *Mycobacterium fortuitum-chelonae* complex. The source of infection was probably contaminated water or disinfectant solution used for sterilization of the instruments.

**Key Messages:** The diagnosis of chronic non-healing wound is of utmost importance and should be done at the earliest. The treatment is also different for non-tuberculous mycobacteria. So there is a need of proper sterilisation and disinfection of surgical instruments in order to prevent such infections.

**Keywords:** Non-tuberculous mycobacteria, *Mycobacterium fortuitum-chelonae* complex, postoperative wound infection, disinfection.

### 1. Introduction

Although *M. tuberculosis*, *M. bovis* and *M. leprae* are established pathogens predominating human mycobacterial infections, nontuberculous mycobacteria (NTM) are increasingly being reported as etiological agents of human infections.[1] The rapidly growing NTM, namely *Mycobacterium fortuitum* and *Mycobacterium chelonae* reportedly cause a range of manifestations ranging from skin and wound infections to septicaemia, meningitis and endocarditis.[2]


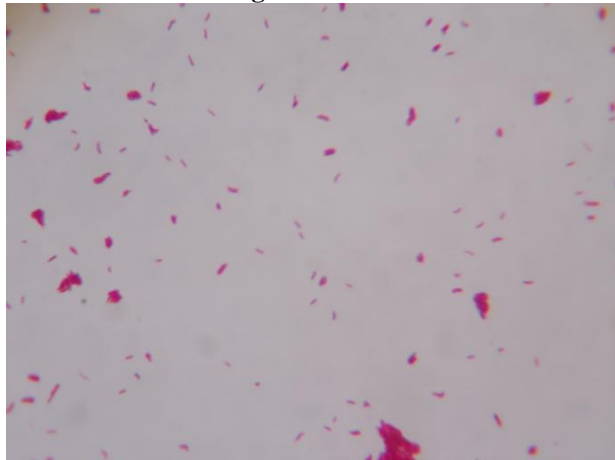
Here we report a case of post operative wound infection due to *Mycobacterium fortuitum-chelonae* complex in a patient who underwent PCNL for pelvic calculus. Though there are reports on isolation of NTM from various parts of India, information on its occurrence in western India is lacking.

### 2. Case History

A 30 years old male patient presented to Urology out Patient Department (OPD) with complaints of left flank pain over the past 7 months. X-Ray and CT scan showed left pelvic calculus with mild hydronephrosis. Results of all blood

tests were within the normal range. After 5 months, the patient underwent PCNL for the calculus. The procedure was successful and patient was discharged. Fifteen days later, the patient came in again to the OPD with complaints of non-healing wound with discharge and induration at the PCNL site.

On examination, the patient had developed sinus at the site. Pus was collected and sent for Microbiological investigations. Ziehl-Neelsen staining of the pus did not show any AFB; however, growth was seen on Lowenstein Jensen medium within 3 days of incubation (Figure 1). A secondary smear was prepared from the growth, and showed AFB (Figure 2). Biochemical tests performed were growth at 37°C and 42°C, growth on MacConkey agar, iron uptake, pigment production, nitrate reduction and urease test. [3] Depending on the findings of the tests the isolate was identified as belonging to *Mycobacterium fortuitum-chelonae* group.

**Figure 1: Growth within 3 days on Lowenstein Jensen Medium****Figure 2: Secondary smear by Ziehl Neelsen stain showing Acid fast bacilli**

### 3. Discussion

There have been earlier reports from India of postoperative wound infections following laparoscopy caused by *M. chelonae*. [2,4-7] Atypical mycobacteria colonize tap water, natural waters, and soil and thus can easily contaminate solutions and disinfectants used in hospital settings. These infections have been a source of significant morbidity for patients who are recovering from laparoscopic surgeries. [4] Inadequate sterilization of laparoscopes by chemical disinfectants has been incriminated as a cause of infection in these cases. Moreover, some of the rapidly growing mycobacteria can survive in such disinfectant solutions for periods as long as four hours. [8] Current guidelines on infection control recommend a minimum

exposure time of 8–12 hours to achieve the desired level of sporicidal activity of these germicides and the use of higher concentrations (3.4%) of glutaraldehyde disinfectants. These disinfectants can be used for maximum of a 100 cycles or a period of 14 days (2.5% glutaraldehyde) or 28 days (3.4% glutaraldehyde), but often no count of cycles are kept in some hospitals and thus the chemicals often do not have the right potency to achieve the desired level of sterilization. Also the practice of rinsing the instruments with boiled tap water to rinse off the glutaraldehyde, further limits the efficacy of use of this system of sterilization as it causes the re-introduction of mycobacterial spores on the instruments that are then deposited at the ports. Therefore, the water used to rinse the instruments should be autoclaved to prevent recontamination with spores post sterilization or preferably use disposable laparoscopic instruments.[9] The favoured choices for treatment of these patients are changeable combination of antibacterial agents like amikacin, fluorinated quinolones, doxycycline, imipenem and clarithromycin.[4] In India cases of *M. fortuitum-chelonae* complex infections are being underreported due to low suspicion amongst clinicians and microbiologists.[4, 10]

### 4. Conclusion

We emphasize the need to suspect non-tuberculous mycobacterial infections in patients presenting with chronic non-healing post-operative wound infections so that they are diagnosed at the earliest and treated appropriately. This report also highlights the need to adhere to strict sterilization and disinfection techniques in surgical units and operation theatres.

### Limitations

- 1) We could not speciate the NTM due to resource constraints.
- 2) We could not perform antibiotic susceptibility testing as Minimum inhibitory concentration technique was not available.

### References

- [1] Wolinsky E. Non Tuberculous Mycobacteria and associated disease. *Am Rev Respir Dis* 1979; 119: 107-59.
- [2] Sethi NK, Aggarwal PK, Duggal L, Sachar VP. *Mycobacterium chelonae* infection following laparoscopic inguinal herniorrhaphy. *JAPI* 2003; 51:81-82.
- [3] Koneman EW, Allen SD, Janda WM, Schreckenberger PC, Winn Jr WC. *Mycobacteria*. Diagnostic microbiology, 4<sup>th</sup> ed. Philadelphia: J.B. Lippincott Company; 1997 p. 703-56.
- [4] Gayathri Devi DR, Sridaran D, Indumathi VA, Babu PRS, Belwadi SM, Swamy ACV. Isolation of *Mycobacterium chelonae* from wound infection

- following laparoscopy: A case report. *Indian J Tuberc* 2004; 51:149-51.
- [5] M Rajini, SR Prasad, RR Reddy, RV Bhat, KR Vimala. Postoperative infection of laparoscopic surgery wound due to *Mycobacterium chelonae*. *Indian J Med Microbiol* 2007; 25 (2):163-5.
- [6] Atul K. Sharma, Rakesh Sharma, Santosh Sharma. Port Site Infection in Laparoscopic Surgeries. *Indian Medical Gazette* - June 2013, pp 224-8.
- [7] Susan Verghese, Parag Agrawal, Santosh Benjamin. *Mycobacterium chelonae* causing chronic wound infection and abdominal incisional hernia. *Ind Jour Pathol Microbiol*, 2014; 57 (2): 335-7.
- [8] Wenger JD, Spika JS, Smithwick RW, Pryor V, Dodson DW, Carden GA, et al. Outbreak of *Mycobacterium chelonae* infection associated with use of Jet injectors. *JAMA* 1990; 264:373-6.
- [9] Rutala W.A., Weber D.J. Disinfection and sterilization in healthcare facilities: what clinicians need to know. *Healthcare Epidemiol*, 2004; 39:702-709.
- [10] Unni M, Jesudason MV, Rao S, George B. *Mycobacterium fortuitum* bacteraemia in an immunocompromised patient. *Indian J Med Microbiol* 2005; 23:137-8.