

A prospective study observing outcome following posterior fossa craniotomy in patients with sitting position

Sonali Kore¹, Pallavi Waghalkar^{2*}, Anita Shetty³ and Madhu Garasia⁴

¹Senior Resident, ²Associate Professor, ⁴HOD, Department of Anaesthesiology, Seth G.S. Medical College and K.E.M. hospital, Mumbai, Maharashtra, India-400012

³Professor, Department of Neuro anaesthesia, Seth G.S. Medical College and K.E.M. hospital, Mumbai, Maharashtra, India-400012

*Correspondence Info:

Dr. Pallavi Waghalkar
Senior Resident,
Department of Anaesthesiology,
Seth G.S. Medical College and K.E.M. Hospital,
Mumbai, Maharashtra, India-400012
E-mail: drpallaviw@gmail.com

Abstract

Aims and Objective: To assess the outcome following posterior fossa craniotomy in sitting position with respect to hemodynamic changes as well as intra and post operative complications.

Material and Method: The present study was conducted in 150 adult patients undergoing posterior fossa craniotomy in sitting position under general anaesthesia. Induction was done with thiopentone sodium 5mg/kg. Neuromuscular blockade was achieved with vecuronium bromide 0.1mg/kg to facilitate intubation. Radial arterial line was inserted preferably in left hand side for invasive blood pressure monitoring. Sitting position was given to patients' slowly over 20-30 minutes. Vital of the patients were monitored during and after giving sitting position. Patients were observed in ICU for first 48 hrs for neurological status, cardiovascular status, respiratory and surgical complications.

Results: We found significant hemodynamic changes during and after giving sitting position to the patients which returned back to normal after 2 hrs of position. There were no perioperative cardiac events and neurological alteration. The incidence of venous air embolism was 5.3% and it was not associated with any postoperative morbidity and mortality. Other complications observed were pneumocephalous (0.7%), tongue oedema (2%) and glossopharyngeal nerve palsy (0.7%).

Conclusions: Use of sitting position for posterior fossa surgery is safe anesthetic techniques and presents unique challenges for the anesthetist; taking measures to minimize hypotension and postoperative complications.

Keywords: Sitting position, Posterior fossa craniectomy, Venous air embolism, Pneumocephalous, Glossopharyngeal nerve palsy.

1. Introduction

Positioning of the surgical patient is an important part of anesthesia care and attention to the physical and physiological consequences of positioning can help prevent serious adverse events and complications. The use of the sitting or upright position for patients undergoing posterior fossa surgery facilitates surgical access but presents unique physiological challenges for the anesthetists with the potential for serious complications such as undesirable hemodynamic instability, venous air embolism, pneumocephalous, complications related to positioning like lingual/laryngeal oedema, brachial plexus injury, sciatic nerve injury, quadriplegia etc[1-3]. However the specific advantages which made this position popular include improved surgical exposure, provides good surgical assess, anatomical orientation, facilitates cerebral decompression, IJBAR (2016) 07 (09)

gravity aided blood and CSF drainage, decreased bleeding, less impairment of diaphragmatic movement leading improved ventilation with lower airway pressure, improved access to endotracheal tube, thorax, extremities, ability to observe face for signs of surgical stimulation of cranial nerves [1-3].

Despite these advantages the use of the sitting position in neurosurgical practice is declining dramatically because of the potential for serious complications after venous air embolism and successful malpractice liability claims. Although there is much debate on advantages and disadvantages of sitting position for neurosurgery, it is routinely used in many institutes including our for posterior fossa surgeries [1,3]. Assessment of relative risk and benefit of sitting position surgery for the individual patient, based on physical status and specific intracranial pathology is,

therefore, of paramount importance. Appropriate patient selection, anticipation of potential complications and careful perioperative monitoring facilitate safe use of sitting position.

In our institute sitting position is very commonly used for the posterior fossa craniotomy so we have decided to conduct a prospective observational study seeing outcome following posterior fossa craniotomy in sitting position. We have studied 150 patients coming for elective posterior fossa surgery for hemodynamic changes, complication rate, associated morbidity and post operative complications for 48hrs in neurosurgical ICU for neurological status, cardiac complications, respiratory or surgical complication.

2. Material and Method

After obtaining institutional ethical committee approval and patients written informed consent, the study was conducted in 150 patients of either sex, aged between 18 to 80 years, ASA grade I, II and III, scheduled for posterior fossa craniotomy in sitting position under general anaesthesia. Patients with ASA grade IV, patients with systemic diseases other than CNS i.e. cardiac diseases, renal diseases, respiratory diseases etc and patients who will not give informed consent were excluded from the study. A detailed history and a thorough general and systemic examination and all relevant investigations were done for all the patients.

In the operation theatre standard monitoring device ECG was applied to the patient and baseline parameters like heart rate and blood pressure were recorded before the surgery. An intravenous access with an appropriate size cannula was obtained. All patients were premedicated with glycopyrrolate 0.004mg/kg IM, midazolam 0.03mg/kg IV, fentanyl 0.002mg/kg IV. Patient was pre oxygenated with 100% oxygen for 3 min. Anaesthesia was induced with injection thiopentone sodium 5mg/kg to loss of eyelash reflex. Neuromuscular blockade was achieved with vecuronium bromide 0.1mg/kg to facilitate intubation with flexometalic armoured tube; oesophageal stethoscope was inserted, throat packing was done and bite block was placed. Eyes were taped and padded with adequate gauze pieces.

Peripherally inserted central venous access was obtained through antecubital veins with the help of 14- 16 gauge cavafix. Radial arterial line was inserted preferably in left hand side with the help of 20 gauge jelco and line was transduced for invasive blood pressure monitoring. Sitting position was given to patients slowly over 20-30 minutes. Meanwhile patient was preloaded with intravenous fluids 10-15 ml/kg crystalloids or colloids to avoid hypotension with positioning. Before positioning vital of the patients were recorded. Legs were slightly flexed at knees so as to bring them nearly at heart level. Head was supported with the help of headholder frame, eyes were taken care by avoiding undue pressure during head positioning. Pressure points were padded with the help of gamgee paddings. Blankets were

placed under the elbow and forearm to support the weight of the arm so that there was no downward stretch on the arms and minimising risk of brachial plexus injury [4]. Excessive neck flexion or rotation was avoided to ensure proper intracranial venous drainage and to avoid airway edema. During positioning vitals monitored were heart rate, systolic and diastolic blood pressure and end tidal carbon dioxide (ETCO₂). Anaesthesia was maintained with O₂:N₂O (40:60), inhalational agent isoflurane and vecuronium as a muscle relaxant; semiclosed circuit with non rebreathing valve was used. Pulse rate, O₂ saturation, ETCO₂, invasive or non invasive blood pressures, central venous pressure and heart beat by auscultation through oesophageal stethoscope were monitored throughout the procedure up to four hours. Intraoperative blood loss was monitored and transfusion was given according to patient's physical status, preoperative haemoglobin values. N₂O was discontinued immediately in cases where venous air embolism were suspected, surgeon was informed to flush the surgical site with normal saline, jugular venous pressure was increased by infusion of crystalloids or colloids through large bore peripheral IV line and air was aspirated through central venous line. During dural closure N₂O was turned off and only 100% O₂ was given. Patient was made supine and head holding pins were removed. Bite block, throat pack, oesophageal stethoscope were removed. Thorough oropharyngeal suctioning was done and neuromuscular blockade was reversed with neostigmine 0.05mg/kg and glycopyrrolate 0.008 mg/kg. After confirming patients good neurological status, muscle tone, movements of all four limbs and adequate air blast; ET tube was removed and patient was observed for 15-20 minutes inside the operation theatre.

Patient was shifted to neurosurgery ICU for further management and observed for first 48 hrs for neurological status, cardiovascular status and respiratory system. Post operative surgical complications were also noted like need for re exploration or wound infection.

2.1 Statistical analysis

The study results were analysed by a repeated measures ANOVA with a Greenhouse-Geisser correction and Post hoc tests using the Bonferroni correction. The level of significance was taken as: $p < 0.05$ - Significant; $p > 0.05$ - Insignificant

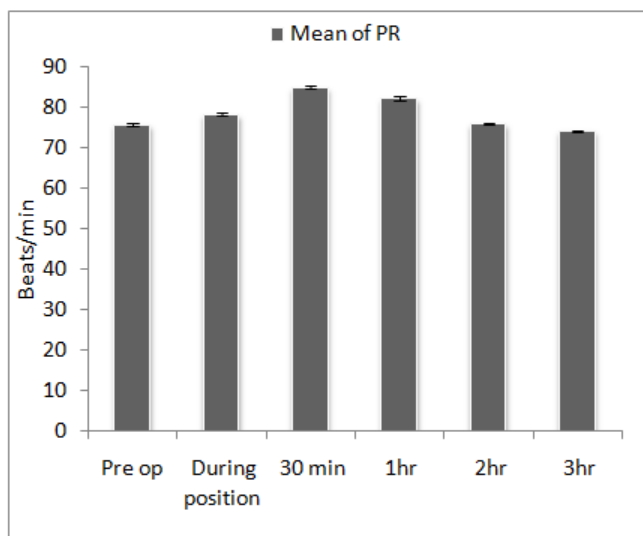
3. Observations and Results

We have studied 150 patients coming for elective posterior fossa surgery. The most common tumour in the posterior fossa found was of vestibular schwannoma type which accounted 46 % followed by meningioma which was seen in 38 patients (25.2%). The third most common variety encountered was epidermoid inclusion cyst, was seen in 20 patients (13.3%). Other histological types that were found in adult posterior fossa tumour were depicted in table 1.

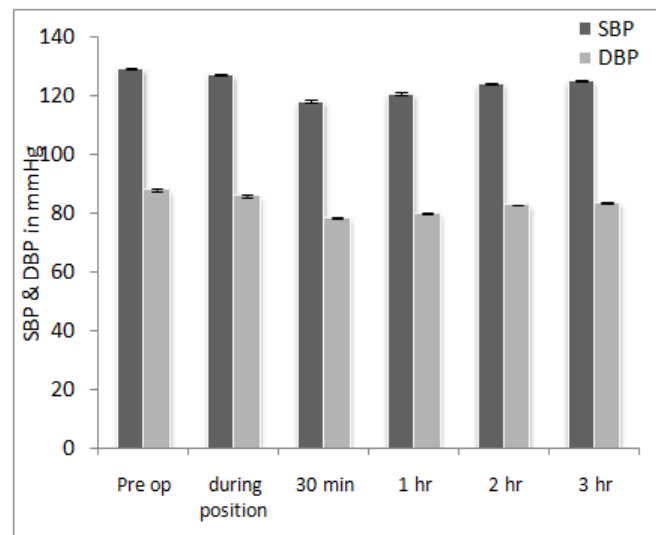
Table 1: Tumour Histology

Tumour Type	N=150 Patients
Vestibular schwannoma	69
Meningioma	38
Epidermoid inclusion cyst	20
Astrocytoma	7
Glioma	5
Hemangioblastoma	4
Medulloblastoma	4
Ependymoma	3

There were significant hemodynamic changes observed during and after positioning of the patient. Pulse rate increased significantly from pre-operation (75.87 ± 5.631) to during positioning (78.33 ± 5.5) and till 30 min. After positioning (85.07 ± 5.797) and then decreased significantly at 1 hour (82.35 ± 5.19) but returned to normal at the end of 2 hours (76.07 ± 3.57). It further decreased significantly to (74.29 ± 2.15) at the end of 3 hours (Figure 1).

Figure 1: Intraoperative Mean Pulse Rate

We found statistically significantly decreased in systolic and diastolic blood pressure from pre-operation value (128.92 ± 4.53 and 87.76 ± 3.8 respectively) to during positioning (SBP- 126.07 ± 5.13 and DBP- 85.72 ± 4.27) and till 30 min. after positioning (SBP- 117.89 ± 6.56 and DBP- 78.29 ± 4.57) and then increased significantly at 1 hour (SBP- 120.39 ± 5.5 and DBP- 79.84 ± 4.12) but returned to near normal at the end of 2 hours (SBP- 124.00 ± 3.04 and DBP- 82.63 ± 2.45). It further increased significantly to (SBP- 124.86 ± 2.1 and DBP- 83.38 ± 2.38) at the end of 3 hours (Figure 2).

Figure 2: Intraoperative Mean Systolic and Diastolic Blood Pressure

We divided the patients into two groups, one with evidence of venous air embolism (VAE) and other without evidence of VAE. There was statistically significant difference of $ETCO_2$ levels between these two groups of the patients posted for sitting position craniotomy. The fall in $ETCO_2$ level was significant at 1 and 2 hrs.

Among the complications incidence of venous air embolism was 5.3% (8 patients out of 150) and it was not associated with any postoperative morbidity and mortality. There were 4 patients who required blood transfusion intraoperatively, the incidence was 2.66%. Tongue oedema was seen in 2% of patients but not affecting the respiration of the patient and it subsided gradually. Pneumocephalus incidence was 0.7% (1 out of 150 patients) which was treated in the ICU postoperatively by doing burr hole in both vertices. Incidence of IX cranial nerve palsy was 0.7% (1 out of 150 patients). It was secondary to the surgical manipulation and has no correlation with sitting positioning. There was no evidence of any peripheral neuropathy secondary to sitting position. There was no new onset motor or sensory deficit or alteration in mental status of patients compared to preoperative state.

4. Discussion

In the patients undergoing posterior fossa craniotomy, sitting position pose many challenges to the anaesthetists. Along with advantages it has many disadvantages. As this position is most commonly used in our institute for doing posterior fossa craniotomies; we decided to do a study observing hemodynamic changes and complications in the anaesthetized patients undergoing posterior fossa craniotomy in sitting position.

Change in the patient position is associated with various hemodynamic changes which are further influenced by general anaesthesia. There is a complex system of local mechanisms (i.e., autoregulation) and reflexes in the venous and the arterial systems maintain heart rate, blood pressure and blood flow during changes in position. Although these local mechanisms and reflexes work in concert, anaesthesia can blunt the response of each element of the system, thereby altering the final response in either direction. Different studies show that change in the patient position was associated with various cardiovascular changes [1,5,6]. In our study pulse rate increased statistically significantly during positioning and till 30 min. after positioning from pre-operation pulse rate and but then returned to normal at the end of 2 hours. Sitting position not only permits gravity dependant venous and cerebrospinal fluid drainage away from surgical field, but may also produce decrease in systemic arterial pressure because of pooling of venous blood in lower extremities [7]. As much as 1500 ml may be sequestered in venous system of lower limbs because of the effect of the gravity [8]. Different authors have described hypotension in different ranges in their studies [1,9-11] but in our study hypotension was considered if there was decrease of 20% or more in systolic blood pressure from ward pressure. Systolic and diastolic blood pressure decreased statistically significantly during positioning and till 30 min. after positioning from pre-operation and then increased significantly and returned to near normal at the end of 2 hours.

VAE is a potential complication of the surgery performed in the sitting position. If left untreated it is having very high mortality. Therefore in order to prevent potentially serious complications, prompt detection and treatment of VAE is essential. No single monitor is completely reliable, use of more than one monitoring modality for VAE detection for sitting position surgery is recommended. Black and Cucchiari[12] recommend a minimum of three monitoring techniques. Placement of multi-orificed central venous catheter is strongly recommended as a means of aspirating air from circulation if embolism occurs [13]. The junction of superior vena cava and right atrium is optimum catheter position for maximum efficacy for aspirating air [14] Precordial Doppler is one of the sensitive monitors to diagnose VAE. In a study of Albin et al[1] done in 180 patients, they used precordial Doppler for diagnosis of VAE and the incidence of VAE they found was 25%. By monitoring ETCO₂ some authors have described the incidence of VAE from 7% to 40%[15-17].

We used capnography, oesophageal stethoscope and central venous catheter for diagnosis of VAE. In our study, we found 8 cases of VAE and incidence of VAE was 5.3%. Such variability in incidence could be ascribed to different states of preoperative hydration in these patients. There was statistically significant difference of ETCO₂ levels between

the patients with evidence of venous air embolism and without venous air embolism posted for sitting position craniotomy. The fall in ETCO₂ level was statistically significant at 1hr and at 2 hrs after the positioning. There was sudden fall in ETCO₂ level which was associated with hypotension and tachycardia. We could aspirate the air from central venous catheter in almost all patients with VAE. Mill wheel murmur was not audible in any patient. There was no postoperative morbidity or mortality in any of these patients.

Decreased blood loss secondary to gravitational pooling of blood in the lower extremities is one of the advantages of sitting position. In a retrospective review of 579 records of patients who underwent posterior fossa craniectomy at the Mayo Clinic[9] from 1981 through 1984 in either sitting or horizontal positions, it was observed that intraoperative requirement for transfusion of more than two units of blood was significantly greater in patients in the horizontal group occurring in 13% of those patients as opposed to only 3% of patients in the sitting group. Average blood replacement was statistically significantly less in the sitting patients. In our study 4 patients out of 150 required blood transfusions, incidence was 2.66%. Only one patient was diagnosed with pneumocephalus and incidence of pneumocephalus was 0.7%. 3 patients had tongue oedema but it was not associated with any respiratory difficulty and it subsided gradually. The mechanism of tongue edema may be sustained neck flexion, the use of oral airways and long duration of surgery which may promote obstruction of venous and lymphatic drainage of the tongue. One patient out of 150 had glossopharyngeal nerve palsy which was secondary to surgical manipulation and had no relation to sitting position. That patient was shifted to ICU on T-piece without extubating due to inability to elicit gag reflex.

5. Conclusion

Present study concluded that the use of sitting position for patients undergoing posterior fossa surgery is safe anesthetic techniques and presents unique challenges for the anesthetist; appropriate patient selection and preparation, taking measures to minimize hypotension and using vigilant intraoperative monitoring and selected patients should still benefit from this position.

Acknowledgement

We sincerely thank the department of anaesthesiology, surgery, other staff of operation theatre and administration of G.S. medical college and K.E.M. hospital, Mumbai, (M.S.), for permission to study and providing facility to carry out the work.

References

- [1] Albin MS, Babinski M, Maroon JC, Janetta PJ. Anaesthetic management of posterior fossa surgeries in

- sitting position. *Acta Anaesthesiol Scand* 1976; 20:117-128.
- [2] Standefer M, Bay JW, Trusso R: The sitting position in neurosurgery: A Retrospective analysis of 488 cases. *Neurosurgery* 1984; 14:649-658.
- [3] Elton RJ, Howell SC. The sitting position for neurosurgical anaesthesia: A survey of British practice in 1991. *Br. J. Anaesth* 1994; 73:247-248.
- [4] Ronald J, Faust, Roy F, Cucchiara, Perry S, Bechtel. Miller: Patient positioning. Miller's Anesthesia, 6th ed. 1161-1166.
- [5] Marshall WK, Bedford RF, Miller ED. Cardiovascular responses in the seated position- impact of four anaesthetic techniques. *Anaesth Analg* 1993; 62:648-653.
- [6] Ward RJ, Danziger F, Bobica JJ, Allen JD, Tolas AG. Cardiovascular effects of change in the posture. *Aerospace Med* 1966; 37:257-259.
- [7] Miller RA. Neurosurgical anaesthesia in the sitting position. *Br. J Anaesth* 1972; 44:495-505.
- [8] Michenfelder JD. Complications during neurosurgery. Anaesthesia and neuromuscular system II. Auto-digest foundation. *Anaesthesiology* 1974; 16:17.
- [9] Black S, Ockert DB, Oliver WC, Cucchiara RK. Outcome following posterior fossa craniectomy in patients in the sitting or horizontal position. *Anaesthesiology* 1988; 69:49-56.
- [10] Matjasko J, Petrozza P, Cohen M, Steinberg P. Anaesthesia and surgery in the seated position: analysis of 554 cases. *Neurosurgery* 1985; 17:695-702.
- [11] Young ML, Smith DS, Murtagh F, Vasquez A, Levitt J. Comparison of surgical and anaesthetic complications in neurosurgical patients experiencing venous air embolism in sitting position. *Neurosurgery* 1986; 18:157-161
- [12] Black S, Cucchiara RF. Tumour surgery. In Cucchiara RF, Michenfelder JD, eds. Clinical neuroanesthesia. New York: Churchill Livingstone, 1990; 285-308.
- [13] Marshall WK, Bedford RF. Use of pulmonary artery catheter for detection and treatment of venous air embolism: a prospective study in man. *Anesthesiology* 1980; 52:131-134.
- [14] Michenfelder JD. Central venous catheter for management of air embolism: Whether as well as where. *Anesthesiology* 1981; 55:339-341.
- [15] Brechner VL, Bethune RWM. Recent advance in monitoring pulmonary air embolism *Anaesth Analg* 1971; 50:255-261
- [16] Tateishi H. Prospective study of air embolism. *BJA* 1972; 44:1306-10. 159.
- [17] Michenfelder JD, Miller RH, Gronert GA. Evaluation of an ultrasonic device (doppler) for the diagnosis of venous air embolism. *Anesthesiology* 1972; 36:164-167.