

A rare intracranial tumor of 'Psammomatous anaplastic meningioma'

Vivek H^{*1}, Vaibhav Bhadbhade² and Paparaja Murthy³

¹Department of General Surgery, Sri DevarajUrs Medical College and Research Centre, Kolar 563101, Karnataka, India

²Department of Orthopaedics, Sri DevarajUrs Medical College and Research Centre, Kolar 563101, Karnataka, India

³Department of Neurosurgery, Sri DevarajUrs Medical College and Research Centre, Kolar 563101, Karnataka, India

*Correspondence Info:

Dr.Vivek. H

Junior Resident

Department of General Surgery,

Sri DevarajUrs Medical College and Research Centre,

Kolar 563101, Karnataka, India

E-mail: harihar.vivek@gmail.com

Abstract

Intracranial meningiomas continue to challenge our best clinical efforts to eliminate them once discovered and deemed appropriate for treatment. Malignant meningiomas constitute 10% to 15% of all meningiomas and limited information exists regarding adjuvant treatment. The external whole brain irradiation is recommended. Traditional chemotherapy has proven ineffective; thus, new chemotherapeutic agents and new methods of delivery should be developed. Immunotherapy may be considered for patients with malignant meningiomas when all others previous treatment have failed. We report a rare case of Psammomatous anaplastic meningioma. A 45-year-old man presented with head ache since 15 days and vomiting since 13days. Magnetic resonance image demonstrated a large left frontal mass with heterogenous enhancement and moderate peri-lesional edema. The tumor and the infiltrated dura were radically removed. Postoperatively, the patient remained neurologically intact.

Keywords:Anaplastic meningioma; Chemotherapy; Psammoma body; Radiotherapy

1. Introduction

Meningioma, one of the most common types of brain tumors in adults, remains a clinical problem yet to be solved by neurologist, neurosurgeons and oncologists. Meningiomas constitute 15% to 20% of all primary brain tumors and 10% to 15% of all meningioma are considered malignant [1,2]. These tumors will recur after standard therapies of surgical excision, radiation therapy, radio-surgical techniques, and chemotherapy.[1,3-6] We report a rare case of anaplastic meningioma with review of literature.

2. Case Report

A 45-year-old man presented with strong headache since 15days and vomiting since 13days. Headache is pulsating type, continuous in nature, relieved by medications and vomiting presents soon after the food intake. There was

no history of head injury. On examination the patient was alert, orientated and obeying commands. Cranial nerves examination was normal and fundus shows bilateral papilledema. Systemic examination was unremarkable.

2.1 Plain and Contrast MRI of brain revealed

Fairly well defined rounded mass lesion measuring 5.7×5.5×5cm (anteroposterior ×transverse ×craniocaudal) in the left frontal region. Inferiorly the mass is seen extending into adjacent ethmoid air cell, which may be the origin of mass. There is moderate perilesional edema. The lesion shows cystic and solid components and hemorrhage. The mass is causing mass effect in the form of midline shift to right by 1.5cm - To consider possibility of Teratoma? Malignancy. (Figure 1 and 2)

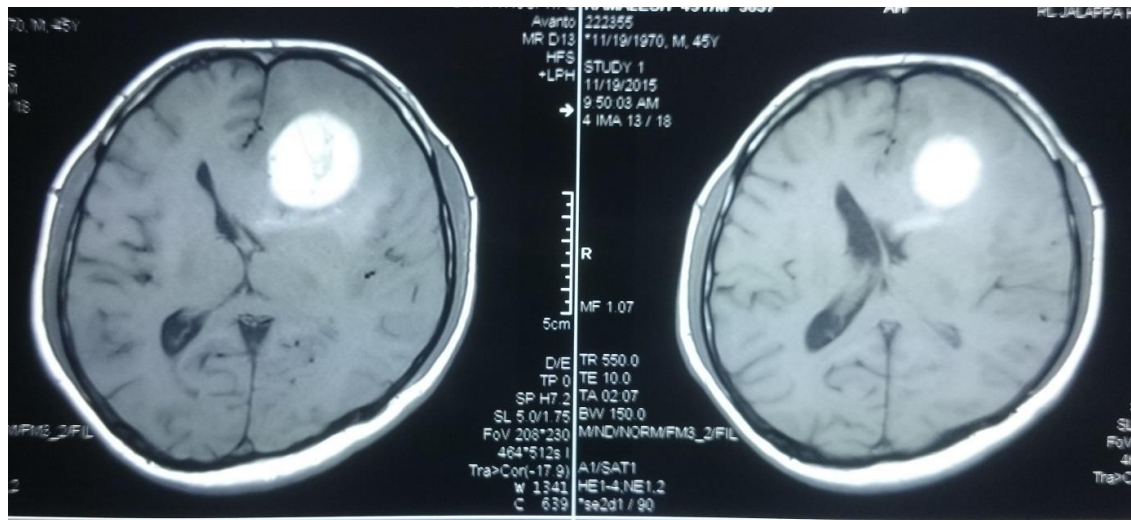


Figure 1: Preoperative MRI of brain in Sagittal plane

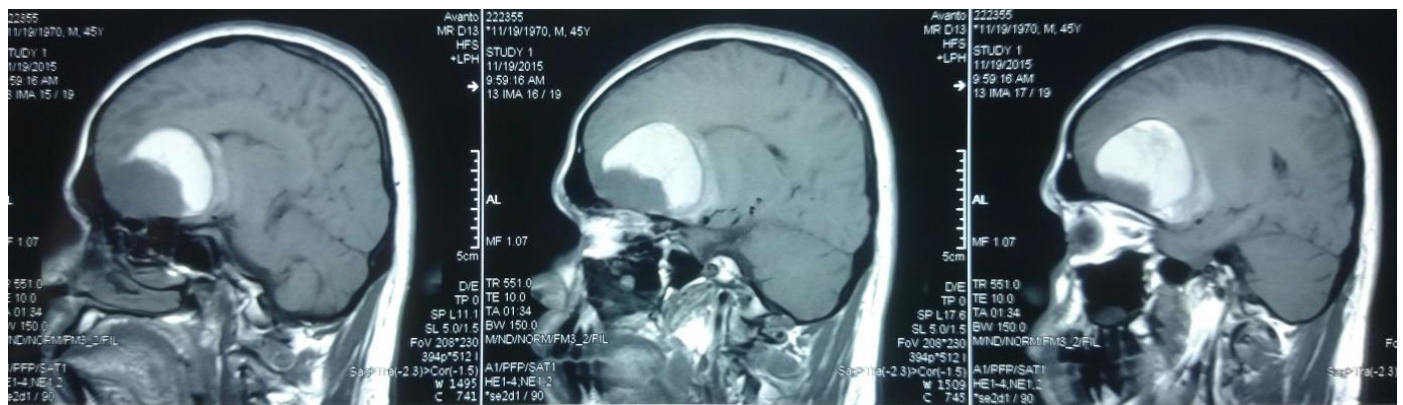


Figure 2: Preoperative MRI of brain in coronal plane

2.2 Peri-operative findings

Capsulated, extra axial tumor, greyish to greyish brown in colour, cyst fluid is dark brown, vascular, intra-tumoralhaemorrhage was noted. Tumor found attached to

anterior skull base dura near the cribriform plate and the falx. Intra operative frozen section revealed – Primary CNS tumor.

In view of Primary CNS tumor, Craniotomy and excision of tumor was done. The patient tolerated the procedure well and the postoperative period was uneventful.

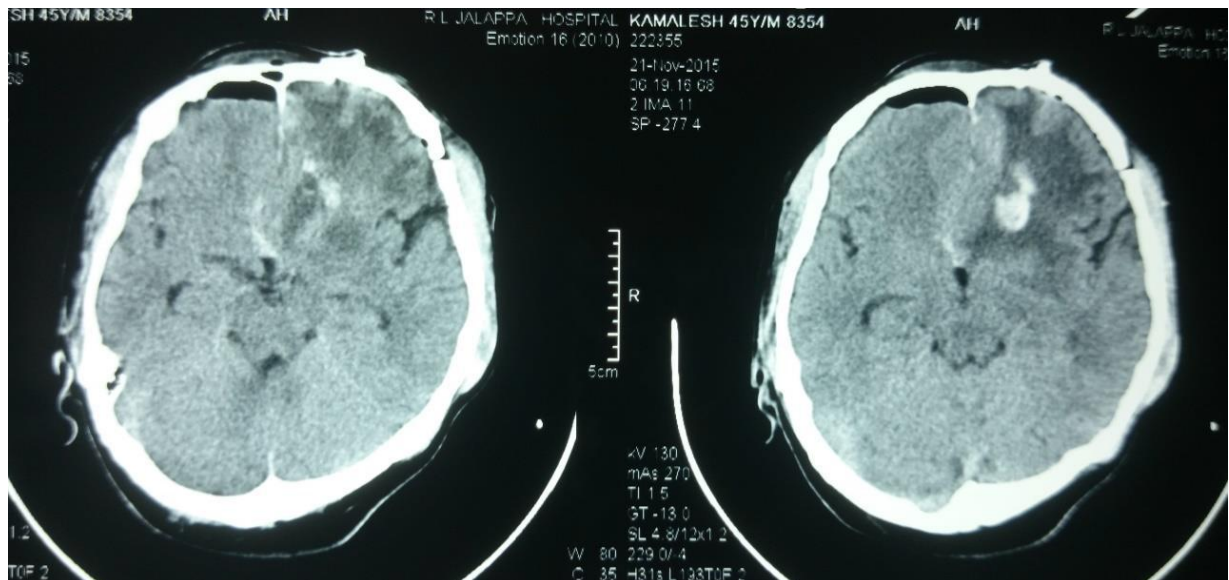


Figure 3: Post-operative CT-scan of Brain

2.3 Histopathology

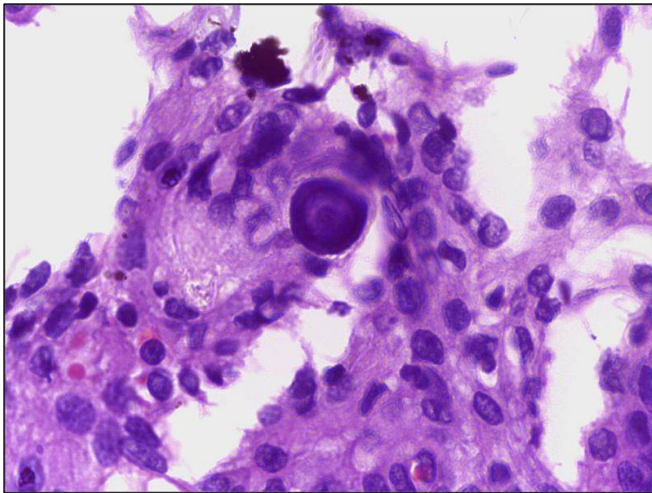


Figure 4: Micrograph of psammoma body in the centre of the field in an anaplastic meningioma of brain. (H&E stain)

3. Discussion

Meningiomas occur at a rate of 7.8 per 100,000 per year, but only 25% are believed to be symptomatic, with the others being found incidentally.[3] The male-to-female ratio is 1:1.8, and the incidence increases with age, peaking at age 85 years.

Malignant meningiomas represent 10% to 15% of all meningiomas.[1] The peak incidence of atypical and malignant meningioma was in the seventh and sixth decades, respectively.[7] These anaplastic meningioma are defined by several criteria including: 1) Invasion of adjacent brain parenchyma or skull, 2) Numerous mitoses (> 5/high-powered field), 3) Elevated proliferative index (>3%) as assessed by either 5bromodeoxyuridine or KI-67 staining, 4) Necrosis, 5) Increased cellularity, 6) Nuclear pleomorphism and 7) Metastasis.[1,5,8-12]

The cell origin of the meningioma's is the arachnoid cap cell, which has a slow rate of cell division. Although tumors originating from the meninges are typically benign, they occasionally behave in an aggressive fashion and carry a much poorer prognosis than do benign meningiomas.[1,3-6] Tumorigenesis must be the result of exogenous or endogenous factors acting alone or together. Exogenous factors include trauma, viral infection, and prior brain irradiation. Endogenous stimulation can occur through the action of hormones or growth factors.

A psammoma body is a round collection of calcium, seen microscopically. The term is derived from the Greek word psammos meaning "sand". Psammoma bodies usually have a lamellar appearance, are circular, acellular and basophilic. Psammoma bodies are commonly seen in certain tumors such as [17,18]: 1) Papillary thyroid carcinoma; 2) Papillary renal cell carcinoma; 3) Micropapillary subtype of lung adenocarcinoma; 4) Ovarian papillary serous cystadenoma and cystadenocarcinoma; 5) Endometrial adenocarcinomas (Papillary serous carcinoma ~3%-4%); 6)

Meningiomas, in the central nervous system; 7) Peritoneal and Pleural Mesothelioma; 8) Somatostatinoma (pancreas); 9) Prolactinoma of the pituitary

Psammoma bodies may be seen in benign conditions like:

1) Endosalpingiosis; 2) Psammomatous melanotic schwannoma; 3) Melanocytic nevus; 4) CVC of spleen.[17,18]

Computed tomography (CT) is probably used most often as the initial imaging study, but magnetic resonance imaging (MRI) is considered to be the gold standard when done with and without gadolinium contrast. On MRI, meningioma's are typically isodense, dura-based masses that often show homogeneous enhancement.[8] There was a clear tendency toward a progressively higher frequency of anaplastic meningioma's among recurrent tumor[13]. Anaplastic meningioma's were tumors that had undergone reoperation and had originally been either benign or aggressive meningioma. This suggests a likelihood that any benign tumor that recurs will be malignant [1,6]. Whereas benign meningioma's tend to show preponderance in females, atypical and malignant meningioma's have a male preponderance [12,14].

Surgery remains an important part of treatment of anaplastic meningioma's. Over the past several years, advances in surgical technique and a revisiting of surgical anatomy have prompted more aggressive approaches to brain tumors. Despite the gross total tumor resection, the survival of malignant meningioma's without adjuvant therapy is less than 2 years [1,5,8-11]. In patients with malignant meningioma's treated with surgery and adjuvant therapy (radiation alone or radiation plus chemotherapy), median survival time was 5 years.

Immunotherapy may be considered for anaplastic meningioma's when all others previous treatment have failed. The most effective immunotherapy appears to be administration of interferon-alpha, which is relatively non-toxic and easily tolerated [15,16]. More studies are needed to better define the roles of these agents in the treatment of anaplastic meningioma's.

4. Conclusion

In conclusion, an aggressive treatment approach with radical surgery and postoperative radiotherapy is warranted in patients with these tumors. Traditional chemotherapy has proved ineffective and the role of adjuvant immunotherapy, brachytherapy or radiosurgery are unknown. Because Psammomatous anaplastic meningiomas are uncommon tumors, a cooperative group study would be required to assess co-variants.

Conflicts of interest: None.

Funding: None

Author contribution: All authors contributed to the paper.

Reference

- [1] Wilson CB. Meningiomas: genetics, malignancy, and the role of radiation in induction and treatment. *J Neurosurg* 1994; 81:666-675.
- [2] Maier H, Ofner D, Hittmair A, *et al.* Classic, atypical, and anaplastic meningioma: three histopathological subtypes of clinical relevance. *J Neurosurg* 1992; 77:616-623.
- [3] Akeyson EW, McCutcheon IE. Management of benign and aggressive intracranial meningiomas. *Oncology (Huntingt)* 1996; 10:747-756.
- [4] Chen WY, Liu HC. Atypical (anaplastic) meningioma: relationship between histologic features and recurrence - A clinicopathologic study. *ClinNeuropathol* 1990; 9:74-81.
- [5] Inoue I, Tamura M, Koizumi H, *et al.* Clinical pathology of malignant meningiomas. *ActaNeurochir* 1984; 73:179-191.
- [6] Palma L, Celli P, Franco C, Cervoni L, Cantore G. Long-term prognosis for atypical and malignant meningiomas: a study of 71 surgical cases. *J Neurosurg* 1997; 86:793-800.
- [7] Mahmood A, Caccamo DV, Tomecek FJ, Malik GM. Atypical and malignant meningiomas: A clinicopathological review. *Neurosurgery* 1993; 33:955-963.
- [8] Alvarez F, Roda JM, Romero MP, *et al.* Malignant and atypical meningiomas: A reappraisal of clinical, histological, and computed tomographic features. *Neurosurgery* 1987; 20:688-694.
- [9] Cho KG, Hoshino T, Nagashima T, *et al.* Prediction of tumor doubling time in recurrent meningiomas: cell kinetics studies with bromodeoxyuridine labeling. *J Neurosurg* 1986; 65:790-794.
- [10] Jaaskelainen J, Haltia M, Servo A. Atypical and anaplastic meningiomas: radiology, surgery, radiotherapy, and outcome. *Surg Neurol* 1986; 25:233-242.
- [11] Thomas HG, Dolman CL, Berry K. Malignant meningioma: clinical and pathological features. *J Neurosurg* 1981; 55:929-934.
- [12] Younis GA, Sawaya R, DeMonte F, Hess KR, Albrecht S, Bruner JM. Aggressive meningeal tumors: review of a series. *J Neurosurg* 1995; 82:17-27.
- [13] Dziuk TW, Woo S, Butler EB, *et al.* Malignant meningioma: An indication for initial aggressive surgery and adjuvant radiotherapy. *J Neurooncol* 1998; 37:177-188.
- [14] Chamberlain MC. Adjuvant combined modality therapy for malignant meningiomas. *J Neurosurg* 1996; 84:733-736.
- [15] Kaba SE, De Monte F, Bruner JM, *et al.* The treatment of recurrent unresectable and malignant meningiomas with interferon alpha-2B. *Neurosurgery* 1997; 40:271-275.
- [16] Kyritsis AP. Chemotherapy for meningiomas. *J Neurooncol* 1996; 29: 269-272.
- [17] Robbin's Pathology, Eight Ed
- [18] Hallman KB, Nahhas WA, Connelly PJ. "Endosalpingiosis as a source of psammoma bodies in a Papanicolaou smear. A case report". *J Reprod Med* 1991; 36 (9): 675-8.