

A study of variations in the origin of vertebral artery and its clinical significance

Neelesh Kanaskar* and P. Vatsalaswamy

Department of Anatomy, Dr. D. Y. Patil Medical College, Pimpri, Pune 18, India

*Correspondence Info:

Dr. Neelesh Kanaskar,
Department of Anatomy,
Dr. D. Y. Patil Medical College, Pimpri, Pune 18, India
E-mail: neeleshkanaskar@gmail.com

Abstract

Objectives: An understanding of anatomy is essential to surgeons and knowledge of variations is of practical importance. The anatomic and morphologic variations of great vessels are significant for diagnostic and surgical procedures in the neck and thorax region.

Vertebral artery is a branch of subclavian artery, generally arising from the first part of subclavian artery on both the sides. Multiple variations in the origin of vertebral artery have been reported in the literature, most common being directly from the arch of aorta, as a branch of thyrocervical trunk, as a branch of common carotid or external carotid artery.

Material and methods: Study was carried out among 30 formalin fixed cadavers procured from Dr. D.Y. Patil Medical College, to note down the variations in the origin of vertebral artery.

Results: Origin of right vertebral artery was normal in all the cases while the left vertebral artery showed varied origin.

Conclusions: Anomalous vertebral artery origins may predisposes an individual to cerebrovascular disorders.

Keywords: Vertebral artery, subclavian artery, arch of aorta

1. Introduction

Variations of the arteries in the human body are important clinically as well as anatomically. Accurate knowledge and understanding of the variations of great vessels are required keeping in view the advances and popularity of endovascular interventions.

Anomalous variations in the origin and course of arteries have serious implications in angiographic and surgical procedures hence it is of great importance to be aware of such possibilities of variations.

The vertebral arteries arise from the superoposterior aspect of the first part of subclavian artery. It passes through the foramina in the transverse processes of all cervical vertebrae except the seventh, curves medially behind the lateral mass of the atlas and enters the cranium via the foramen magnum [1] and at the lower border of pons it unites with similar artery of opposite side to form basilar artery, therefore each vertebral artery is divided into four parts i.e. cervical, vertebral, sub-occipital and intra-cranial part [2].

2. Materials and Methods

30 cadavers which comprise the material for the present study were procured from the department of Anatomy. These cadavers were embalmed with 10 per cent formalin and fixed. After separating the head and abdomen

region from the cadaver, branches of subclavian artery were dissected.

The steps of dissection were as follows:

- Cadavers where superficial dissection of Head, Neck and Thorax was done, where in investing layer of cervical fascia was removed from the lower part of roof of posterior triangle were cut at the level of sixth thoracic vertebra.
- The specimens were labeled with number and side.
- Sternocleidomastoid, Strenothyroid and Sternohyoid muscles were exposed, cut and reflected superiorly.
- Fascial sling of intermediate tendon of Omohyoid muscle was cut and reflected.
- Clavicle was cut at its midlength.
- Blood vessels were exposed; internal jugular vein (IJV) was identified and traced till its opening in subclavian vein.
- IJV was displaced medially to expose subclavian artery, which was identified as a branch of brachiocephalic trunk on right side and from arch of aorta on the left side.
- Branches from 1st part of subclavian artery were exposed and identified.
- Variations if any in the origin of vertebral artery were noted according to side.
- Photographs of variations were taken.

3. Observations and Results

30 formalin fixed cadavers where neck and thoracic region were dissected meticulously and variations if any in the origin of vertebral artery were observed noted and photographed. All the findings were recorded and assembled in the tabulated form. The variations are shown below in the following table.(Table 1)

Table 1: variations in the origin of vertebral artery

Name	Side	Sp.No.	Variation if any
Origin of Vertebral artery	Lt	10 14 17 22 25	From arch of aorta between left Common carotid artery and left Subclavian artery. (fig.1)
	Lt	8	From root of left Subclavian artery. (fig. 2)

However no variations were observed in the origin of right vertebral artery.

4. Discussion

Considering the surgical importance of variations in the vessels of head and neck region, 30 cadavers were dissected for the study of variations in the origin vertebral artery.

Many variations occur in the number and position of the vessels that arise from the aortic arch. A common form of three branches arising from the aortic arch is seen in approximately 80%.When more than three branches arise from the aortic arch; the vertebral arteries are usually added [3].

A detailed knowledge of the anomalous origins of supra-aortic vessels is of importance in patients who have to undergo four-vessel angiography. If a vertebral artery cannot be found in the usual position, the possibility of such a variant must be considered. The existence of these anomalies also accounts for the policy in many practices, of routinely performing an angiogram of the aortic arch before attempting selective catheterization of the carotid and vertebral arteries.

Vertebral artery (VA) is classically described as the first branch of ipsilateral subclavian artery; multiple variations in the origin of this artery have been reported in the literature. The vertebral artery can arise from the aortic arch; from common carotid; internal or external carotid arteries; or from subclavian branches itself like thyrocervical trunk. Vertebral artery may have duplicate origins, generally from the aortic arch and subclavian artery [4].

Literature shows the frequency of origin of the left vertebral artery from aortic arch in the range of about 1%-3%[5]. According to Bernadi and Deton, the abnormal origin of vertebral artery may favour cerebral disorders because of change in cerebral hemodynamics[6]. Also Nathan & Seidal, had reported a left vertebral artery of aortic origin associated with retroesophageal right subclavian artery and thoracic duct terminating on right side, yet with normal origin of right vertebral artery [7].

The prevertebral segment (cervical segment) of vertebral artery is frequently affected with atherosclerosis. Though the overall incidence of anomalous origin of prevertebral segment of vertebral artery is low, it is extremely important to be aware of these complications in patients with this anomaly [8].

Komiyana *et al*, reported the incidence of arterial dissection of the vertebral artery of aortic origin and vertebral artery of subclavian origin. According to their studies left vertebral artery of aortic origin was associated with a significantly higher incidence of vertebral artery dissection than left vertebral artery of left subclavian artery origin and right vertebral artery of right subclavian origin [9].

The left vertebral artery arising from the aortic arch is the third most common aortic arch branching pattern with an incidence of 0.79-8% [10]. This variation plays an important role for vascular surgeons, neurosurgeons and thoracic surgeons because vertebral artery injury is a known complication of the extended lateral decompression during anterior cervical spine surgery, which can result in exsanguinations and permanent neurologic deficits. It is important for the neurovascular interventionalist and the neurosurgeon to be aware of this variant [11].

A case of anomalous origin of the left vertebral artery from thyrocervical trunk was reported in CT angiography [12].

Koenigsberg *et al* described three cases of right vertebral artery abnormalities: as a fourth and the most distal branch of aortic arch, as a branch distal to thyrocervical trunk and as a branch of right common carotid artery in addition to retroesophageal right subclavian artery (RRSA)[13].

Fazan *et al* reported a case of a right vertebral artery originating from the right common carotid artery with the addition of a RRSA [14].

The embryological mechanism of aberrant right subclavian artery (ARSCA) with a right vertebral artery from the right common carotid artery (VA-CCA) has been explained in several studies [15]. The known incidence of right VA-CCA is less than about 0.18%.A combination of these two variations is rare [16].

During surgery at the craniovertebral junction, injury to vertebral artery can cause brain stem ischemia and cerebellar infarction^[17]. Anomalous vertebral artery origins present a pitfall at diseased cerebral angiography because they may be assumed to be occluded or diseased if they are not catheterized [11].

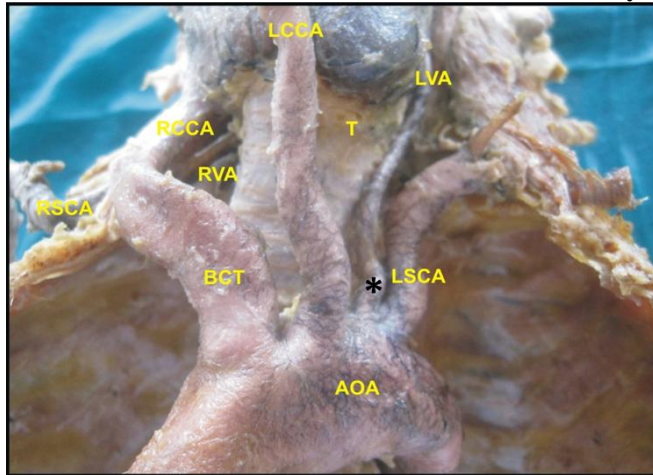
4.1 Variations in the origin of vertebral arteries

4.1.1 Left vertebral artery

Left vertebral artery was seen arising as a direct branch from arch of aorta between left common carotid and left subclavian artery by Sait Albayram *et al*[18], R. Suresh *et al*[19], Paniker, H.K *et al*[20], Young-Don Kim *et al*[21], Ronald A. Bergman *et al*[22], Mange Manyama *et al*[23], similar variation was observed in the present study in 5 cases

(Figure 1) and also as a branch from thyrocervical trunk by W. M. Struba *et al* [12], Ronald A. Bergman *et al* [22].

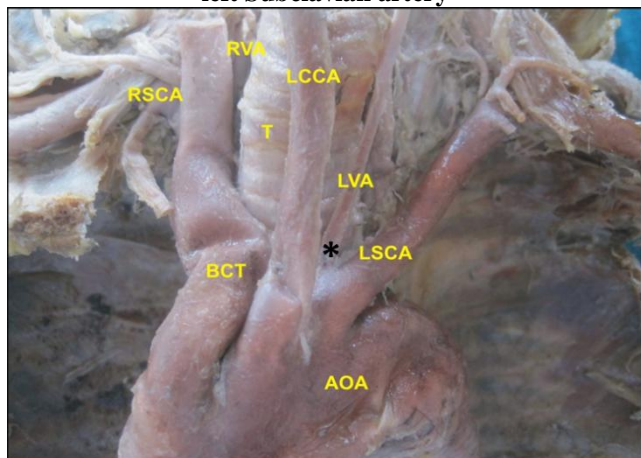
Figure 1: Origin of Left Vertebral artery from arch of aorta between left Common Carotid and left Subclavian artery



AOA- Arch of aorta, BCT- Brachiocephalic trunk, RSCA- Right subclavian artery, RCCA- Right common carotid artery, RVA- Right vertebral artery, LCCA- Left common carotid artery, T- Trachea, LVA- Left vertebral artery, LSCA- Left subclavian artery.

It was seen as a branch from root of left subclavian artery close to the arch of aorta by Konstantinos Natsis *et al* [24] and a similar variation was observed in the present study in one case (Figure 2).

Figure 2: Origin of Left Vertebral artery from root of the left Subclavian artery



AOA- Arch of aorta, BCT- Brachiocephalic trunk, RSCA- Right subclavian artery, RVA- Right vertebral artery, LCCA- Left common carotid artery, T- Trachea, LVA- Left vertebral artery, LSCA- Left subclavian artery.

4.1.2 Right vertebral artery

Right vertebral artery was seen as a direct branch from the arch of aorta between left common carotid artery and left subclavian artery by Sait Albayram *et al* [18], M. Loukas *et al* [25], it was seen as last branch of aortic arch distal to left subclavian artery by P. Ligege *et al* [3] and as a branch right common carotid artery by Young-Don Kim *et al* [21] and Ronald A. Bergman *et al* [22]. However no such variation was found in the present study.

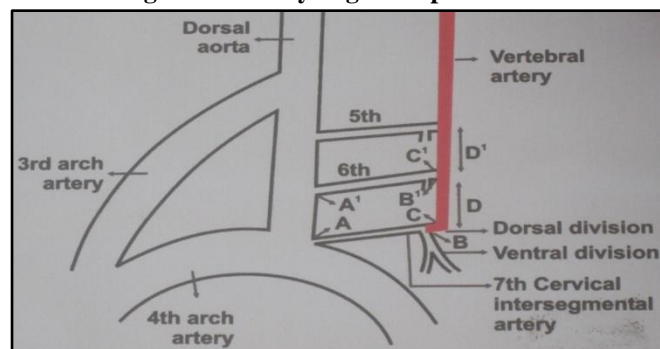
4.1.3 Embryological basis of variations of vertebral artery

Embryologically, the vertebral artery (VA) is formed by the development of longitudinal anastomoses that link the cervical intersegmental arteries. The intersegmental arteries eventually regress except for the seventh, which becomes the proximal subclavian artery and which includes the point of origin of the VA in adults [26].

The origin of the vertebral arteries from the aortic arch is because of degeneration of the normal origin from the seventh intersegmental artery with persistence of a higher intersegmental artery, such as sixth [27].

It can be explained from the figure that dorsal branch of 6th intersegmental artery (segment B`C`), 6th intersegmental artery itself (segment A`B`) and (segment A`A`) of dorsal aorta fail to disappear, hence blood flows through these persistent vessel forming a vertebral artery of aortic arch origin [20]. (Fig. 3)

Figure 3: Embryological explanation



5. Conclusion

The knowledge of anatomical variations of vessels in the head and neck region is of immense importance. Considering that vascular variations have been always a subject of controversy, more detailed knowledge about anatomical structures in the neck region is required especially while performing procedures such as MRI, CT and other surgical procedure.

With more and more technical advancement, clinicians dealing with the arch of aorta and the great vessels should be aware of these variations. Further more knowledge of the development of the cardiovascular system could be useful for better understanding of the pathophysiology of the variation and apply that knowledge to recognize the variations.

The findings of the present study are as follows:

Left vertebral artery was seen arising from arch of aorta directly between left common carotid and left subclavian artery in five cases. It was seen arising from the root of left subclavian artery close to the arch of aorta in one case. Knowledge of variations in the branching pattern of the arch of aorta is of great importance in patients who have to undergo four vessels angiography, aortic instrumentation and head neck surgery. It could also lead to cerebral abnormalities by altering the pattern of blood flow in cerebral vessels [28].

Clinical signs or symptoms associated with anomalous vertebral artery origins though have not been reported yet but some are of the opinion that vertebral origin variant predisposes an individual to cerebrovascular disorders.

Anomalous vertebral artery origin also represents a potential pitfall at diagnostic cerebrovascular imaging. One or both vertebral arteries may be assumed to be occluded or diseased during angiography or noninvasive procedure such as CT angiography, MR angiography or Doppler sonography. Hence it is important to understand anomalous variations of the vertebral artery since it allows physicians to avoid accidental damage to the vertebral artery during these procedures.

References

- [1] Gray H. The Anatomical Basis of Clinical Practice. 40th ed. Susan Standring, Elsevier Churchill Livingstone; 2008. p. 447-449.
- [2] Dutta AK. Essentials of Human Anatomy Part 2. 5th ed. Kolkata: Current Books International; 2009. p. 185-190.
- [3] Ligege P, Scholtz L. Rare variation in the origin of right vertebral artery. *SA Journal of Radiology* 2004; 8(1):34-35.
- [4] Lemke AJ, Benndorf G, Liebig T, Felix R. Anomalous origin of right vertebral artery: review of the literature and case report of the right vertebral artery origin distal to the left subclavian artery. *AJNR* 1999; 20:1318-1321.
- [5] Dasler EH, Anson BJ. Surgical anatomy of the subclavian artery and its branches *Surgery Gynecology Obstetrics* 1959; 108:149-174.
- [6] Bernardi L, Deton P. Angiographic study of a rare anomalous origin of the vertebral artery. *Neuroradiology* 1975; 9:43-47.
- [7] Nathan H, Seidel MR. The association of a retroesophageal right subclavian artery, a right sided terminating thoracic duct and a left vertebral artery of aortic origin. Anatomical and Clinical considerations. *Anatomica* 1983; 117:363-373.
- [8] Vicko G, Goran I, Damjan M, Sanja P. Anomalous origin of both vertebral arteries. *Clinical Anatomy* 1999; 12:281-284.
- [9] Komiyama M, Morikawa T, Nakajima H, Nishikawa M, Yasui T. High incidence of arterial dissection associated with left vertebral artery of aortic origin. *Neurology Medical Chir* 2001; 41(1):8-11.
- [10] Liechty JD, Shields TW, Anson BJ. Variations pertaining to the aortic arches and their branches. *Q Bull Northwest Univ Med Sch* 1957; 31:136-143.
- [11] Lu J, Ebraheim NA. The vertebral artery: surgical anatomy. *Orthopedics* 1999; 22:1081-1085.
- [12] Struba WM, Leach JL, Tomsick TA. Left Vertebral Artery Origin from the Thyrocervical Trunk: A Unique Vascular Variant. *American Journal of Neuroradiology* 2006; 27:1155-1156.
- [13] Koenigsberg RA, Pereira L, Nair B, McCorming D, Schwartzman R. Unusual vertebral artery origins: Examples and related pathology. *Cathet Cardiovasc Intervent* 2003; 59:244-250.
- [14] Fazan VPS, Caetano AG, Filho OAR. Anomalous origin and cervical course of the vertebral artery in the presence of a retroesophageal right subclavian artery. *Clin Anat* 2004; 17:354-357.
- [15] Yanik B, Conkbayir I, Keyik B, Hekimoglu B. A rare anomalous origin of right vertebral artery: findings on Doppler sonography. *J Clin Ultrasound* 2004; 32:211-214.
- [16] Palmar FJ. Origin of the right vertebral artery from the right common carotid artery: angiographic demonstration of three cases. *Br J Radiol* 1977; 50:185-187.
- [17] Yamazaki M *et al.* Anomalous vertebral artery at the craniovertebral junction in a patient with Down syndrome. *J Neurosurg Spine* 2004; 3:338-341.
- [18] Albayram S, Gailloud P, Wasserman BA. Bilateral Arch Origin of the Vertebral Arteries. *American Journal of Neuroradiology* 2002; 23:455-458.
- [19] Suresh R, Ovchinnikov N, McRae A. Variations in the branching pattern of the aortic arch in three Trinidadians. *West Indian Med J.* 2006; 55(5):351-352.
- [20] Panicker HK, Tarnekar A, Dhawane V, Ghosh SK. Anomalous Origin of Left Vertebral Artery – Embryological Basis and Applied Aspects- A Case Report. *J Anat. Soc. India* 2002; 51(2):234-235.
- [21] Don Kim Y, Tae Yeo H, Dae ChoY. Anomalous Variations of the Origin and Course of Vertebral Arteries in Patients with Retroesophageal Right Subclavian Artery. *J Korean Neurosurg Soc.* 2009; 45(5):297-299.
- [22] Bergman RA, Afifi AK, Miyauchi R. Illustrated Encyclopedia of Human Anatomic Variation: Opus II: Cardiovascular System: Arteries: Head, Neck, and Thorax. Available from: URL: <http://www.anatomyatlases.org/AnatomicVariations/Cardiovascular/TextArteries>
- [23] Manyama M, Rambau P, Gilyoma J, Mahalu W. A variant branching pattern of the Aortic Arch: a case report. *Journal of Cardiothoracic Surgery* 2011; 6:29.
- [24] Natsis K, Didagelous M, Noussios G, Adamopoulou A, Nikolaidou E, Paraskevas G. Combined anomalous origin of a left inferior thyroid artery and a left vertebral artery: a case report. *Cases J* 2009; 2:7400.
- [25] Loukas M, Louis RG Jr, Gaspard J, Fudalej M, Tubbs RS, Merbs W. A retrotracheal right subclavian artery in association with a vertebral artery and thyroideaemia. *Folia Morphol(Warsz)*. 2006; 65(3):236-41.
- [26] Newton TH, Mani RL. The vertebral artery. *Radiology of skull and brain* 1974; 1659-1672.
- [27] Cairney. The anomalous right subclavian artery considered in the light of recent findings in arterial development; a note on two cases of an unusual relation of the innominate artery to the trachea. *J Anat* 1925; 59:256-296.
- [28] Moore KL & Persaud TVN. The Developing Human Clinically Oriented Embryology. 8th ed. 2008. p. 319-325.