

Surgical management of Oral submucous fibrosis

CN Yogishwarappa and Abhishek Vijayakumar*

Department of Plastic Surgery, Bangalore Medical College and Research Institute, Bengaluru, Karnataka 560002 India

*Correspondence Info:

Dr. Abhishek Vijayakumar

#128 Vijay Doctors colony,

Konanakunte Bangalore 560062 India

E-mail: abhishekbmc@yahoo.co.in

Abstract

Background: Oral submucous fibrosis (OSF), globally accepted as an Indian disease, has one of the highest rates of malignant transformation amongst potentially malignant oral lesions and conditions. The hallmark of the disease is submucosal fibrosis that affects most parts of the oral cavity, pharynx and upper third of the esophagus leading to dysphagia and progressive trismus due to rigid lips and cheeks. Nonsurgical measures like local steroids, hyaluronidase injections, vitamin supplements and jaw opening exercises have poor results. There lack of guidelines for choosing the surgical procedures.

Methods: This prospective study was done on 13 cases of clinically diagnosed oral submucous fibrosis during 2012-2015. After diagnosis these patients are grouped according to the severity of the disease proposed by Chandramani More. The patients underwent either release and split skin grafting or Nasolabial flap or Superficial temporal artery fascial flap for intra oral cover. The results were analysed for postoperative mouth opening and complications.

Results: Of the total 13 patients studied 8 were male and 5 females. The age ranged from 22 years to 68 year (Mean= 43 years). Preoperative functional stage was ten patients 15-25mm mouth opening (M3) and three patient <15mm mouth opening (M4) Mean preoperative mouth opening was 16.7mm. The procedure performed was release with split skin graft in six patients, release with Nasolabial flap cover in two patients and release with superficial temporal artery flap cover with graft in five patients. Mean post operative mouth opening was 35.6mm at follow up of 6 months.

Conclusion: Surgical correction of oral submucous fibrosis offer better outcome than conservative management. The choice of surgical procedure depends on patient profile. Flap covers are better than split skin graft in term of recurrences. Nasolabial flap cover can be used in elderly with lax skin. The superficial temporal artery fascial flap cover has advantage of lesser morbidity and more suited in cases of severe restriction of mouth opening.

Keywords: Sub mucosal fibrosis; Nasolabial flap; Superficial temporal artery fascial flap; Trismus.

1. Introduction

Oral submucous fibrosis (OSF), globally accepted as an Indian disease, has one of the highest rates of malignant transformation amongst potentially malignant oral lesions and conditions. The condition has also been described as idiopathic scleroderma of mouth, idiopathic palatal fibrosis and sclerosing stomatitis. It was first described by Pindborg & Sirsat (1966). The hallmark of the disease is submucosal fibrosis that affects almost all parts of the oral cavity, pharynx and upper third of the esophagus leading to dysphagia and progressive trismus. The condition has a multi-factorial origin and it is commonly associated with chewing of areca nut (betel nut). The role of Arecoline and Tannis of areca nut causing juxtaepithelial hyalinisation and muscle fibrosis is well described in the literature.[1]

Oral Submucous fibrosis is diagnosed based on clinical criteria such as excessive salivation, absent gustatory sensation and limitation of mouth opening, difficulty in chewing, swallowing, articulation and poor oral hygiene oral

ulceration, paleness of the oral mucosa and burning sensation (particularly in the presence of spicy foods), hardening of the tissue and presence of characteristic fibrous bands. In advanced cases, nasal twang may be present due to fibrosis of nasopharynx and hearing impairment due stenosis of eustachian tube may also occur.[2] The fibrosis involves the lamina propria and the submucosa and may often extend into the underlying musculature resulting in the deposition of dense fibrous bands giving rise to the limited mouth opening which is a hallmark of this disorder.

Conservative measures like local steroids, hyaluronidase injections, vitamin supplements and jaw exercises have poor results.[3] Simple release of fibrosis and skin grafting showed recurrence due to scarring and graft contraction. [4-5] Use of bilateral tongue flaps is a very morbidity associated procedure and requires flap division at a second stage. Nasolabial flaps are small compared to the defect.[6] Island palatal mucoperiosteal flap based on the greater palatine artery is possible only in some cases.[7]

Bilateral radial artery forearm free flap is bulky and hair bearing. [8]

2.1 Patients and methods

This prospective study was done on 13 cases of clinically diagnosed oral submucous fibrosis during 2012-2015. Clinical diagnosis of OSMF was based on symptom of burning sensation in mouth upon consumption of spicy or hot foods, repeated vesiculation or ulceration in oral cavity and signs observed were vesicles/ulcers in oral cavity, areas of fibrosis in vestibule of mouth, oral cavity proper and oropharynx, partial or complete inability to protrude out the tongue (ankyloglossia) with or without reduced mouth opening (trismus). After diagnosis these patients are grouped according to the severity of the disease proposed by Chandramani More *et al* [9]:

Clinical staging:

Stage 1 (S1): Stomatitis and/or blanching of oral mucosa.

Stage 2 (S2): Presence of palpable fibrous bands in buccal mucosa and/or oropharynx, with /without stomatitis.

Stage 3 (S3): Presence of palpable fibrous bands in buccal mucosa and/or oropharynx, and in any other parts of oral cavity, with/without stomatitis.

Stage 4 (S4) as follows:

a. Any one of the above stage along with other potentially malignant disorders, e.g. oral leukoplakia, oral erythroplakia, etc.

b. Any one of the above stage along with oral carcinoma.

Functional staging:

M1: Interincisal mouth opening up to or greater than 35 mm.

M2: Interincisal mouth opening between 25 and 35 mm.

M3: Interincisal mouth opening between 15 and 25 mm.

M4: Interincisal mouth opening less than 15 mm.

2.2 Technique for nasolabial flap cover

The patients were operated under general anaesthesia given through a nasoendotracheal tube using a fibreoptic bronchoscope. Incisions were placed bilaterally on the buccal mucosa using an electrosurgical cautery; incision extended from the corner of mouth to the soft palate at the level of the linea alba, and avoided injury to Stenson's duct. After fibrous bands had been released the interincisal opening was recorded. Extended nasolabial flaps from the tip of nasolabial fold to the inferior border of mandible were bilaterally raised in the plane of the superficial musculoaponeurotic system from both terminal points to the region of the central pedicle. The pedicle was 1 cm lateral to the corner of mouth and the diameter of the pedicle was roughly 1 cm. The flap was transposed intraorally through a small transbuccal tunnel near the commissure of the mouth, with no tension. The transposed flaps were used to cover the intraoral defects. The inferior wing of the flap was sutured to the anterior edge of the defect, while the superior wing was sutured to the posterior edge of the defect. The extraoral defect was closed primarily in layers after liberal undermining of the skin in the subcutaneous plane to prevent

any tension across the suture line. A soft temporomandibular joint trainer was placed postoperatively in the oral cavity for 10 days to prevent dehiscence of the flap as a result of occlusal trauma. After a latent period of 10 days, physiotherapy was started with jaw exercises to prevent contractures and relapse. The patients were instructed and motivated to continue the physiotherapy themselves for up to 6 months and were followed up for 2 years.

2.3 Surgical technique for TPF flap

Infiltration of the incision from the pre-auricular region extending to the temporal region was done 10 min prior to the incision. Dissection was performed in the sub follicular plane to develop the superficial temporal fascia flap to its maximum limit. Sub periosteal dissection was performed over the zygomatic arch and the zygomatico maxillary area. The origin of the masseter muscle was released completely from the zygomatic arch and the zygomatic process of the maxillary bone. This allowed partial release of the fibrosis. The dissection was carried along the coronoid process. Insertion of the temporalis muscle was released from the coronoid process and the anterior border of the ramus of the mandible. An intraoral incision was made to release the mucosa, buccinator muscle, and pterygomandibular raphe. This procedure was repeated on the opposite side allowing complete release of submucous fibrosis with full mouth opening. A superficial temporal fascia flap was elevated from the pericranium and the deep temporal fascia. The flap was pedicled on the superficial temporal vessels and turned over the zygomatic arch and brought intraorally to fill in the defect. Split skin graft harvested from the thigh was sutured over the flap intraorally, covering the defect and was immobilised with a tie over dressing. The tie over dressing was removed on the fifth post-operative day.

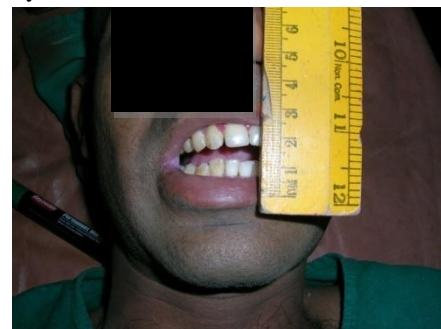

Figure 1: Preoperative mouth opening

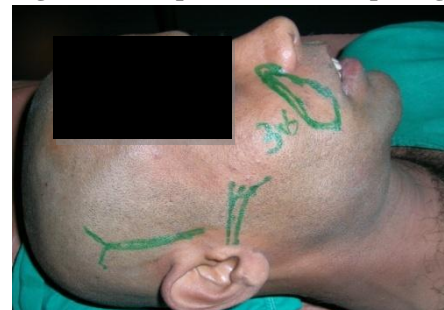

Figure 2: Marking of pedical and flap

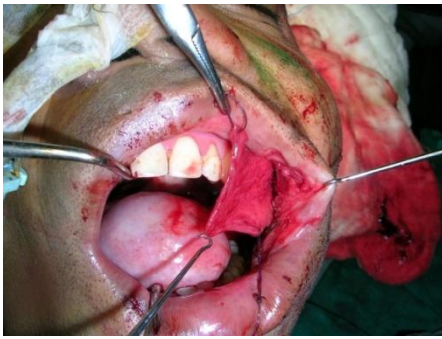


Figure 3: Release of fibrotic bands

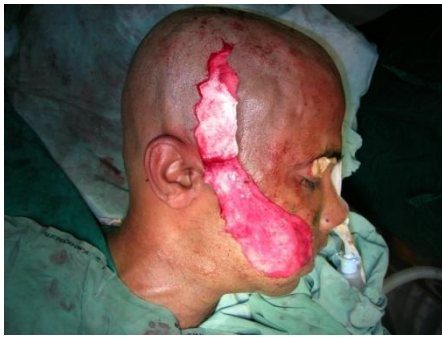

Figure 4: Superficial temporal flap harvest

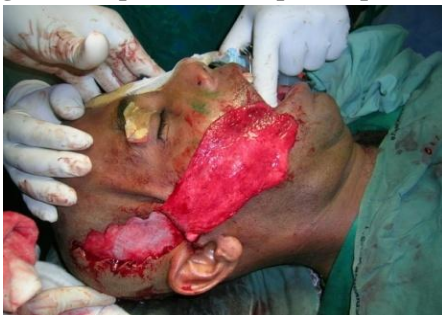

Figure 5: Tunneling of Flap intraorally

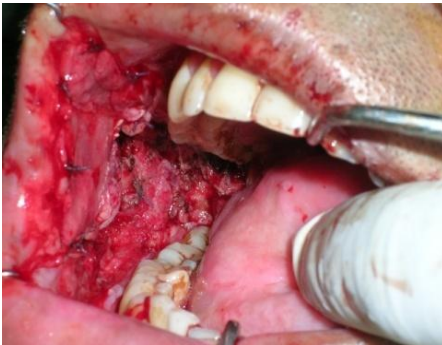

Figure 6: Flap inset and grafting

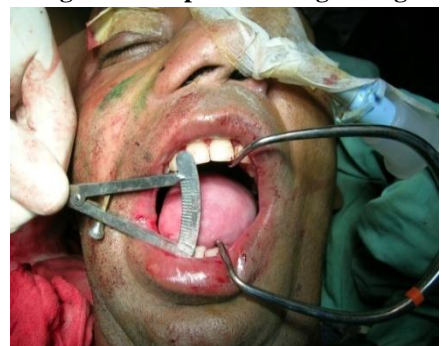

Figure 7: Intraoperative mouth opening achieved

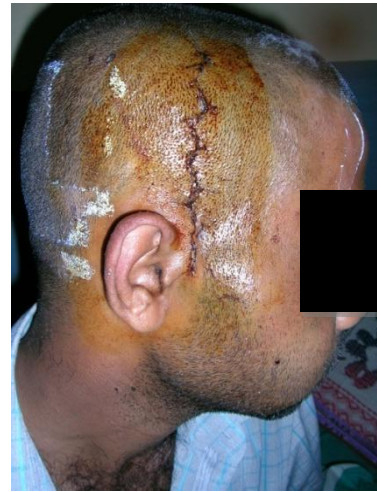

Figure 8: Donor site closure

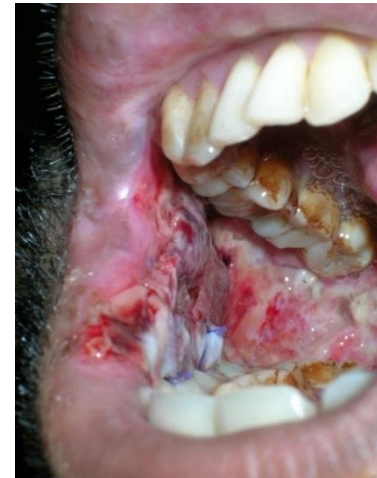

Figure 9: Partial graft loss

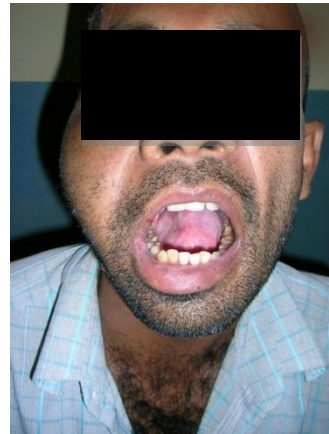

Figure 10: Post operative mouth opening at 6 months

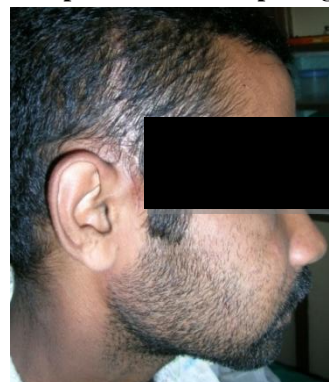

Figure 11: Donor site at 6 months

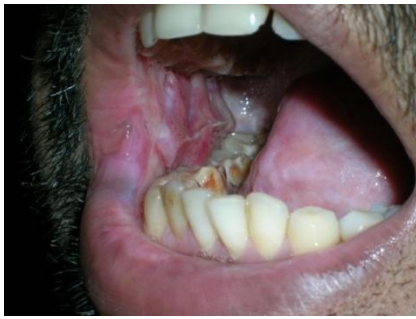

Figure 12: Mucosalization of graft

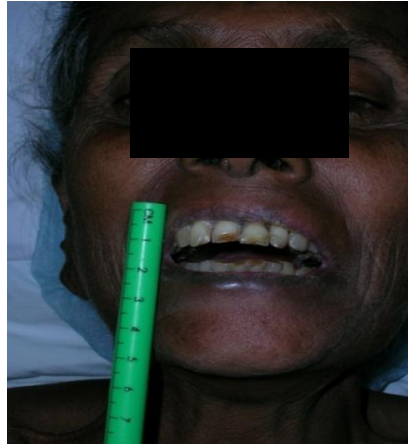

Figure 13: Preoperative mouth opening

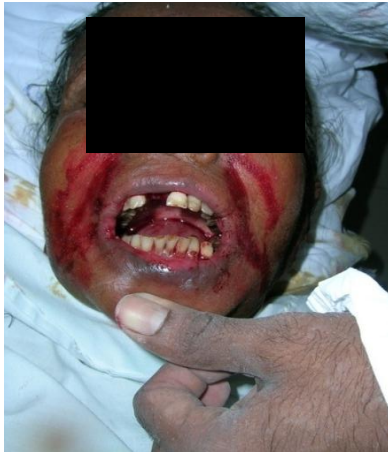

Figure 14 Nasolabial flap design

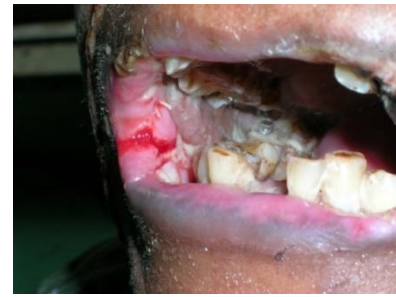

Figure 15: Post operative flap

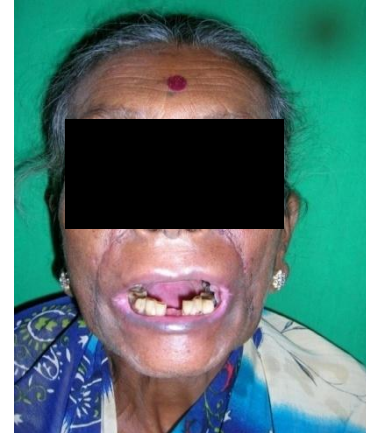

Figure 16: Post operative mouth opening

3. Results

Of the total 13 patients studied 8 were male and 5 females. The age ranged from 22 years to 68 year (Mean= 43 years). Clinically four Patients were having palable bands in buccal mucosa without stomatitis (S2). Seven patients had palpable bands in buccal mucosa and also oralpharynx of which three had features of stomatitis (S3). Two patients had fibrous bands with leukoplakia(S4). Preoperative functional stage was ten patients 15-25mm mouth opening (M3) and three patient <15mm mouth opening (M4) Mean preoperative mouth opening was 16.7mm. The procedure performed was release with split skin graft in six patients, release with Nasolabial flap cover in two patients and release with superficial temporal flap cover with graft in five patients. Mean post operative mouth opening was 35.6mm at followup of 6 months. There were two cases of partial graft loss which healed spontaneously. In one case operated with nasolabial flap she developed hypertrophic scar at donor area which was managed with intralesional steroid and scar massage.

Table 1: Patient demographics

S. no	Age	Sex	Clinical Stage	Procedure	Pre op mouth opening	Post op mouth opening	Complication
1	48	M	S2	NLF	22mm	38mm	Nil
2	37	F	S3	SSG	16mm	30mm	Partial graft loss
3	22	M	S2	TPF	20mm	36mm	Nil
4	36	M	S2	TPF	24mm	40mm	Nil
5	30	F	S3	TPF	15mm	39mm	Nil
6	28	M	S3	SSG	17mm	38mm	Nil
7	46	M	S2	SSG	15mm	36mm	Partial graft loss
8	68	F	S4	NLF	15mm	35mm	Hypertrophic scarring
9	50	M	S3	SSG	18mm	36mm	Nil
10	53	M	S3	TPF	20mm	40mm	Nil
11	48	F	S4	SSG	12mm	30mm	Nil
12	46	M	S3	TPF	10mm	32mm	Partial graft loss
13	56	F	S3	SSG	14mm	34mm	Nil

4. Discussion

Long standing oral sub mucous fibrosis is a debilitating disease. It presents with difficulty in mouth opening with poor oral hygiene and its complications. Treatment for oral submucous fibrosis is a challenge, as the pathogenesis of this disease is multivariate. It can be said that, once the disease has developed, there is neither regression nor any effective treatment. Consequently, improved oral opening and relief of symptoms form the objective of OSMF treatment. In general, the management modalities can be categorized into conservative and surgical depending on the stage of the disease. Various medical managements have been mentioned in literature. (Table 2)

Treatment	Treatment details
Micronutrients and minerals[10]	Vitamin A, B complex, C, D and E, iron, copper, calcium, zinc, magnesium, selenium and others
Milk from immunized cows[11]	45 g milk powder twice a day for 3 months
Lycopene[12]	8 mg twice a day for 2 months
Pentoxifylline[13]	400 mg 3 times a day for 7 months
Interferon gamma[14]	Intralesional injection of interferon gamma (0.01–10.0 U/mL) 3 times a day for 6 months
Steroids[15]	Submucosal injections twice a week in multiple sites for 3 months
Steroids[15]	Topical for 3 months
Hyalase + Dexamethasone[15]	—
Placental extracts[15]	—
Turmeric[16]	Alcoholic extracts of turmeric (3 g), turmeric oil (600 mg), turmeric oleoresin (600 mg) daily for 3 months
Chymotripsin, hyaluronidase and dexamethasone[17]	Chymotripsin (5000 IU), hyaluronidase (1500 IU) and dexamethasone (4 mg), twice weekly submucosal injections for 10 weeks

Conservative treatment with local steroids, hyaluronidase injections and physiotherapy are not beneficial in advanced cases.

Surgery is required in all advanced cases. Release of fibrosis and split skin grafting has a high recurrence rate due to graft shrinkage. Use of island palatal flap has limitations such as its involvement with fibrosis and second molar tooth extraction is required for flap cover without tension. The bilateral tongue flaps cause severe dysphasia, disarticulation, and carry the risk of postoperative aspiration. They also provide a limited amount of donor tissue as their reach is inadequate. The stability of a tongue flap and dehiscence are the common postoperative complications of uncontrolled tongue movements. Apart from this the reported involvement

of the tongue is 38%, which precludes its use for reconstruction.[18]

Bilateral palatal flaps leave a large raw area on palatal bone. Sometimes the defect created may be large and local flaps may not be able to cover the entire defect. Buccal fat pads may also be used to cover the defects after excision of the fibrous bands. The harvesting of the buccal fat pad is simple because access is easy. However, most of these cases have atrophy of buccal pad of fat as well. The anterior reach of buccal fat is limited and leaves a raw area which has to be left to heal secondarily leading to contracture.

Bilateral free radial artery forearm free flaps require microvascular expertise, the flaps are hairy and 40% of patients require secondary debulking procedures. Extraction of the third molar tooth is required to avoid flap inclination between teeth. Canniff and Harvey recommended temporal myotomy or coronoidectomy to release severe trismus caused by the atrophic changes in the tendon of temporalis muscle secondary to the disease.[19] We have seen that the long term recurrence with graft is more as partial graft breakdown and subsequent healing by secondary intention. Over years our method of selection procedure has been Nasolabial flap cover in older individuals with lax skin which can provide large flaps for intraoral closure and also the donor area may be closed primarily. The disadvantage being visible scar and higher chances of Hypertrophic scar if large donor defects are closed under tension.

Superficial temporal artery flap is preferred in younger individuals with severe restriction of mouth opening. Intra oral release of the mucosa, pterygomandibular raphe and buccinator muscle leaves a mucomuscular defect. Well vascularised superficial temporal fascia flap enhances the blood supply for the fibrosed muscles and mucosa and provides a healthy bed for the skin graft. This procedure has advantages of minimal donor site morbidity, hidden scars and has lesser recurrences in long run.

We advocate use of split skin grafts in cases of minimal to moderate amount of restriction of mouth opening, Superficial temporal artery fascial flap in younger individuals with severe contracture and nasolabial flap in older patients with lax facial skin.

5. Conclusion

Surgical correction of oral submucous fibrosis offer better outcome than conservative management. The choice of surgical procedure depends on patient profile. Flap cover is better than split skin graft in term of recurrences. Nasolabial flap cover can be used in elderly with lax skin. The superficial temporal artery fascial flap cover has advantage of lesser morbidity and more suited in cases of severe restriction of mouth opening.

Conflict of Interest: None

References

- [1] Pillai R, Balaram P, Reddiar KS. Pathogenesis of oral submucous fibrosis. Relationship to risk factors associated with oral cancer. *Cancer* 1992; 69(8): 2011–20.
- [2] Gnanam A, Kannadasan Kamal, Venkatachalapathy S, David Jasline. Multimodal treatment options for oral submucous fibrosis, SRM University. *Journal of Dental Sciences* 2010; 1(1): 26-29.
- [3] Gupta D, Sharma SC. Oral submucous fibrosis: a new treatment regimen. *J Oral Maxillofac Surg* 1988; 46(10): 830–3.
- [4] Borle RM, Borle SR. Management of oral submucous fibrosis: a conservative approach. *J Oral Maxillofac Surg* 1991; 49(8):788–91.
- [5] Morawetz G, Katsikeris N, Weinberg S, Listrom R. Oralsubmucous fibrosis. *Int J Oral Maxillofac Surg* 1987; 16(5):609–14.
- [6] Kavarana NM, Bhathena HM. Surgery for severe trismus in submucous fibrosis. *Br J Plast Surg* 1987; 40(4):407–9.
- [7] Khanna JN, Andrade NN. Oral submucous fibrosis: a new concept in surgical management: report of 100 cases. *Int J Oral Maxillofac Surg* 1995; 24(6):433–9.
- [8] Wei FC, Chang YM, Kildal M, Tsang WS, Chen HC. Bilateral small radial forearm flaps for the reconstruction of buccal mucosa after surgical release of submucosal fibrosis: a new reliable approach. *Plast Reconstr Surg* 2001; 107(7):1679–83.
- [9] More CB, Das S, Patel H, Adalja C, Kamatchi V, Venkatesh R. Proposed clinical classification for oral submucous fibrosis. *Oral oncology*. 2012 Mar 31; 48(3):200-2.
- [10] Maher R, Aga P, Johnson NW, Sankaranarayanan R, Warnakulasuriya S. Evaluation of multiple micronutrient supplementation in the management of oral submucous fibrosis in Karachi, Pakistan. *Nutr Cancer* 1997; 27(1):41–7.
- [11] Tai YS, Liu BY, Wang JT, Sun A, Kwan HW, Chiang CP. Oral administration of milk from cows immunized with human intestinal bacteria leads to significant improvements of symptoms and signs in patients with oral submucous fibrosis. *J Oral Pathol Med* 2001; 30(10):618–25.
- [12] Kumar A, Bagewadi A, Keluskar V, Singh M. Efficacy of lycopene in the management of oral submucous fibrosis. *Oral Surg Oral Med Oral Pathol Oral Radiol Endod* 2007; 103(2):207–13. Epub 2006 Oct 24.
- [13] Rajendran R, Rani V, Shaikh S. Pentoxifylline therapy: a new adjunct in the treatment of oral submucous fibrosis. *Indian J Dent Res* 2006; 17(4):190–8.
- [14] Haque MF, Meghji S, Nazir R, Harris M. Interferon gamma (IFN-gamma) may reverse oral submucous fibrosis. *J Oral Pathol Med* 2001; 30(1):12–21.
- [15] Borle RM, Borle SR. Management of oral submucous fibrosis: a conservative approach. *J Oral Maxillofac Surg* 1991; 49(8):788–91.
- [16] Hastak K, Lubri N, Jakhi SD, More C, John A, Ghaisas SD, and other. Effect of turmeric oil and turmeric oleoresin on cytogenetic damage in patients suffering from oral submucous fibrosis. *Cancer Lett* 1997; 116(2):265–9.
- [17] Gupta D, Sharma SC. Oral submucous fibrosis — a new treatment regimen. *J Oral Maxillofac Surg* 1988; 46(10):830–3.
- [18] Khanna JN, Andrade NN. Oral submucous fibrosis: a new concept in surgical management. Report of 100 cases. *Int J Oral Maxillofac Surg* 1995; 24:433–9.
- [19] Canniff JP, Harvey W, Harris M. Oral submucous fibrosis- its pathogenesis and management. *Br Dent J* 1986; 160:429–33.