

## Recurrent Angiomatoid Fibrous Histiocytoma of thigh in a middle aged female: A case report

Tarun Kumar<sup>1</sup>, Ashok Singh<sup>1</sup>, Seema Kaushal<sup>\*1</sup>, Vaishali Suri<sup>1</sup> and Anita Dhar<sup>2</sup>

<sup>1</sup>Department of Pathology, All India Institute of Medical Sciences (AIIMS), Ansari Nagar, New Delhi - 110029 India

<sup>2</sup>Department of Surgery, All India Institute of Medical Sciences (AIIMS), Ansari Nagar, New Delhi - 110029 India

### \*Correspondence Info:

Dr. Seema Kaushal

Department of Pathology,

All India Institute of Medical Sciences (AIIMS),

Ansari Nagar, New Delhi - 110029 India

E-mail: [seema.dr@gmail.com](mailto:seema.dr@gmail.com)

### Abstract

Angiomatoid fibrous histiocytoma (AFH) is a rare soft tissue tumor of intermediate malignant potential seen predominantly in children and young adults. We here report a case of recurrent AFH in right medial thigh of a 46 year old female which recurred locally within 13 months of wide local excision of the mass. The lesion may mimic hematoma, soft tissue hemangioma, nodular malignant melanoma or any cutaneous and skin adnexal tumor clinically as well as radiologically. Hence it is imperative to consider this lesion in the differential diagnosis of a soft tissue tumor in spite of elderly age.

**Keywords:** Angiomatoid fibrous histiocytoma (AFH), Recurrent, malignant.

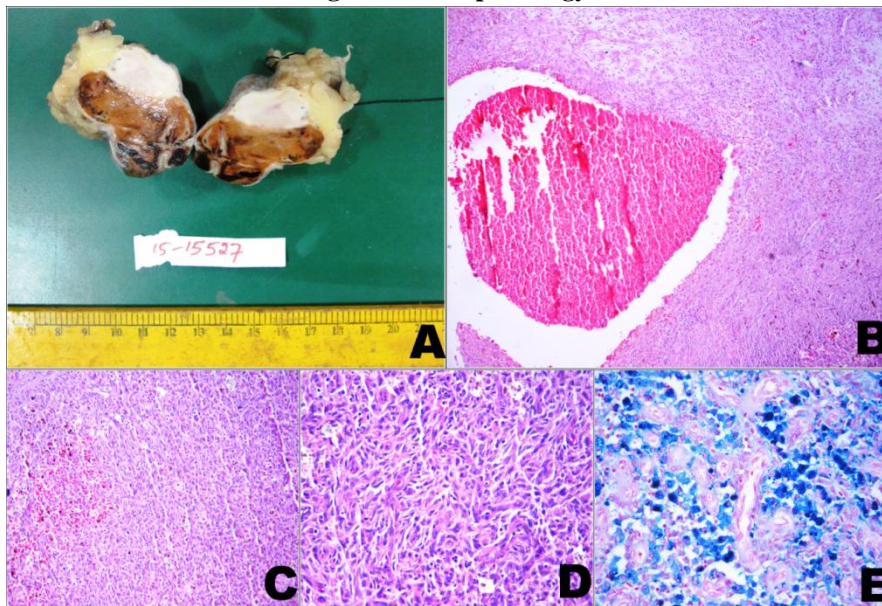
### 1. Introduction

Angiomatoid fibrous histiocytoma (AFH) is a rare soft tissue tumor of intermediate malignant potential, which accounts for approximately 0.3% of soft-tissue neoplasms[1,2]. It is predominantly seen in the deep dermis and subcutis of the extremities of children and young adults.[3,4]. Apart from extremity, it has been also reported to occur at various sites like hard palate, mediastinum, vulva, retroperitoneum, ovary, and lung [5]. Majority of AFH are slow growing and painless lesions [6] while systemic symptoms such as pallor, fever and weight loss are rarely encountered. . Herein, we present the case of a 46 year old female with a local recurrence of an AFH over the right medial thigh.

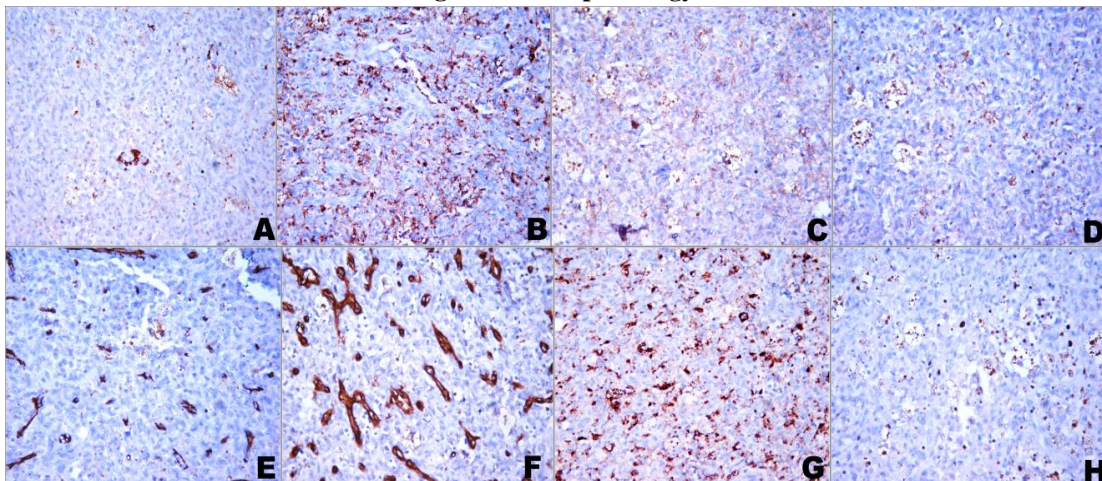
### 2. Case Report

A 46 year old female presented to the outpatient department in our institute with painless slow growing lump over the medial aspect of the right thigh for the past 5 years with increase in size since 6 months. Clinical examination revealed a mass measuring 3x2cm with overlying purple brown to dark skin surface. The mass was well circumscribed with uneven consistency varying soft to firm. General physical examination was within normal limit. An excision wedge biopsy was performed. On histomorphology, a diagnosis of Angiomatoid Fibrous Histiocytoma was given. Comment on surgical margin of the wedge biopsy was not

possible. However, the patient was lost to follow-up. After 13 months, she again presented to our institute with recurrence of similar lesion at same site along with ulceration and bleeding from the overlying skin. A wide local excision of the right thigh mass was performed. Grossly, it measured 6x6x3cm, overlying ulcerated skin measured 6.5x3cm. Cut section of the specimen showed a fairly circumscribed, soft to firm, brownish tumor nodule with area of hemorrhage measuring 4.5x4x3cm (Figure-1A). On microscopy section examined showed a spindle cell tumor composed of varying proportions of spindled to oval histiocytoid cells arranged in diffuse sheets with moderate nuclear pleomorphism and infrequent mitosis. Pseudoangiomatous spaces filled with blood which were surrounded by tumor cells were also identified (Figure-1B). Extensive hemosiderine deposition was also noted [Figure: 1E]. No necrosis was identified. All the peripheral resected margins of the specimen were free of the lesion. The tumor cells shows immunopositivity for desmin, epithelial membrane antigen [EMA], CD68 (Figure-2A, 2B, 2C) while negative for CD31 CD34 and HMB-45 (Figure-2D, 2E, 2F). Ki-67 labeling index is 1-2% in highest proliferative area (Figure-2G). Based on classical morphology and immunohistochemistry, a diagnosis of AFH was made. Postoperatively, she has done well and after thirteen months since her re-excision, the patient shows no evidence of recurrence to till date and is on regular follow up every 6 month.

**Figure 1: Histopathology**

[A] Cut surface of gross photomicrograph showing a fairly circumscribed brownish tumor nodule with areas of hemorrhage(measuring 4.5x4x3cm).[B] low power photomicrograph showing pseudoangiomatic space surrounded by tumor cells(x40,H&E).[C] The tumor is composed of spindled to oval histiocytoid cells arranged in diffuse pattern(x200,H&E) with moderate nuclear pleomorphism and infrequent mitosis[D](x400, H&E).extensive hemosiderine deposition is also noted[x400, pearl stain].

**Figure 2: Histopathology**

The tumor cells are immunopositive for desmin(x400, A), CD68(x400, B) epithelial membrane antigen(x400, C) and while negative for CD31(x400, D), CD34 (x400, E) and HMB45(x400, F). Ki-67 labeling index is 1-2% in highest proliferative area (x400, G).

### 3. Discussion

The term “Angiomatoid Malignant Fibrous Histiocytoma” first described by Enzinger in 1979[3]. Initially, A MFH was described as a variant of malignant fibrous histiocytoma; Because of its benign microscopic appearance , relatively rarity of metastasis [7] and overall excellent clinical course, in World Health Organization (WHO) 2002 classification, it was removed from the malignant fibrous histiocytoma subtype of sarcoma and was placed under the category of tumors of uncertain differentiation as angiomatoid fibrous histiocytoma [6]. AFH is mostly seen in the first 2 decades of life, although the age distribution is wide, ranging from infant [8] to eight decade [2]. No sex predilection is noted. Majority of case occur in

extremity followed by trunk and head and neck. However, occurrence of AFH in non somatic soft tissue sites such as the lung, mediastinum, vulva, retroperitoneum, ovary, pulmonary artery, kidney, and brain [9]. Omentum [10], ovary, vulva, and bone [11] have been documented in the literature. Our index case was seen in 40 years woman with a recurrent thigh mass measuring 6 cm in maximum dimension. Microscopically, it is characterized by varying proportions of spindled or histiocytoid cells, arranged in a nodular pattern, pseudovascular spaces and prominent lymphoplasmacytic rim [12,13].

However, various morphology of AFH has been documented in the literature. Chen *et al* reported clear cells, rhabdomyoblast-like cells, pulmonary edema like pattern and

myxoid stroma in some AFH cases [5]. Bohman *et al* have reported perineurioma-like pattern, moderate pleomorphism, significant areas of sclerosis, eosinophils in the stroma[12,13]. Kao *et al* have reported solid histology without pseudoangiomatoid spaces, moderate nuclear pleomorphism, perivascular hyalinisation osteoclasts, absence of peripheral lymphoid infiltrates and myxoid stroma[14] Recently, Schaefer and Fletcher *et al* have reported myxoid variant of AFH in a series of 21 cases.[15]. Our case did not reveal any unusual histomorphologic features. The tumor cells shows positivity for desmin, EMA, CD68 and CD99[12,16] while consistently negative for S100 protein, CD34, CD35, CD21 and Cytokeratin. Our case shows immunopositivity for desmin, EMA and CD68. Cytogenetically AFH is associated with 3 characteristic translocations: t(2:22)(q33;q12), most common, 90% of cases [2], t(12:22)-(q13;q12) and t(12:16)(q13:p11). In our index case cytogenetics studies were not performed as morphology was classical. As AFH have no any distinct clinical or radiological findings, with various morphological pattern and lacks specific immunophenotypic markers, making this diagnosis can be very challenging. . The differential diagnosis of AFH includes Granulomatous inflammation (lacks vascular space), Aneurysmal benign fibrous histiocytoma(heterogeneous cell population than AFH , lacks a surrounding lymphoplasmacytic infiltrate, and is desmin negative) Spindle cell hemangioma(occurs in the dermis and subcutis of extremities and has cavernous vascular spaces but is poorly circumscribed, with true vascular spaces lined by attenuated endothelial cells ) Inflammatory myofibroblastic tumor (myofibroblasts with distinct cell borders and eosinophilic cytoplasm, vesicular nuclei with distinct nucleoli, inflammatory cells intimately intermingled with the neoplastic cells without forming a peritumoral rim. Positive for actin, desmin, and ALK), Nodular Kaposi sarcoma (dermal and circumscribed with bland cytology and contains slitlike blood-filled spaces rather than the cystic ones seen in AFH, express CD34 and human herpesvirus 8). Other rare differentials are Follicular dendritic cell tumor, Ewing sarcoma, Rhabdomyosarcoma, Malignant extra renal rhabdoid and metastatic tumor deposits.

Chow *et al* reported that the majority of patients are disease free after wide local excision [17]. Fanburg *et al* reported a 1% frequency of metastasis in their series [1]. In other studies up to 23% of patients may develop recurrence and 8.7% develop metastasis within 24 months post excision [4, 18] Due to metastatic potential, AFH has been classified in intermediate malignant potential. Costa *et al* [19] reported that recurrent AFH can be successfully managed with local radiation, which is an important consideration for our patient.

In conclusion, AFH though rare tumor should be kept in mind in differentials of recurrent soft tissue lesions even in the middle age. It should be managed with appropriate surgical excision to obtain negative surgical

margins and patient should be kept on close follow up. Local radiation therapy may be helpful in managing the recurrence.

## References

- [1] Fanburg-Smith JC, Dal Cin P. Angiomatoid fibrous histiocytoma. In: Fletcher CDM, Unni KK, Mertens F, eds. World Health Organization Classification of Tumors: Pathology and Genetics of Tumors of Soft Tissue and Bone. Lyon, France: IARC Press; 2002:194-195.
- [2] Antonescu CR, Dal Cin P, Nafa K, *et al*. EWSR1-CREB1 is the predominant gene fusion in angiomatoid fibrous histiocytoma. *Genes Chromosomes Cancer*. 2007 Dec; 46(12):1051-1060.
- [3] Enzinger FM. Angiomatoid malignant fibrous histiocytoma: a distinct fibrohistiocytic tumor of children and young adults simulating a vascular neoplasm. *Cancer*. 1979; 44(6):2147-2157.
- [4] Costa MJ, Weiss SW. Angiomatoid malignant fibrous histiocytoma: a follow-up study of 108 cases with evaluation of possible histologic predictors of outcome. *Am J Surg Pathol*. 1990; 14(12):1126-1132.
- [5] Chen G, Folpe AL, Colby TV, Sittampalam K, Patey M, Chen MG, Chan JK. Angiomatoid fibrous histiocytoma: unusual sites and unusual morphology. *Mod Pathol* 2011; 24: 1560-70.
- [6] Fletcher CD. The evolving classification of soft tissue tumours: an update based on the new WHO classification. *Histopathology*. 2006 Jan; 48(1):3-12.
- [7] Matushansky I, Charytonowicz E, Mills J, *et al*. MFH classification: differentiating undifferentiated pleomorphic sarcoma in the 21<sup>st</sup> Century. *Expert Rev Anticancer Ther*. 2009 Aug; 9(8):1135-44.
- [8] Argenyi ZB, Van Rybroek JJ, Kemp JD, Soper RT. Congenital angiomatoid malignant fibrous histiocytoma: a light-microscopic, immunopathologic, and electron-microscopic study. *Am J Dermatopathol*. 1988;10(1):59-67.
- [9] Song JY, Lee SK, Kim SG, Rotaru H, Baciut M, Dinu C. Angiomatoid fibrous histiocytoma on the hard palate: case report. *Oral Maxillofac Surg* 2012; 16: 237-42.
- [10] Fletcher CD. Angiomatoid "malignant fibrous histiocytoma": An immunohistochemical study indicative of myoid differentiation. *Hum Pathol*. 1991; 22(6): 563-568
- [11] Mangham DC, Williams A, Lalam RK, Brundler MA, Leahy MG, Cool WP. Angiomatoid fibrous histiocytoma of bone: a calcifying sclerosing variant mimicking osteosarcoma. *Am J Surg Pathol*. 2010; 34(2):279-285.
- [12] Fanburg-Smith JC, Miettinen M. Angiomatoid "malignant" fibrous histiocytoma: a clinicopathologic study of 158 cases and further exploration of the myoid phenotype. *Hum Pathol*. 1999; 30:1336-1343.
- [13] Thway K. Angiomatoid Fibrous Histiocytoma. *Arch Pathol Lab Med* 2008; 132:273-277.

- [14] Kao YC, Lan J, Tai HC, Li CF, Liu KW, Tsai JW, Fang FM, Yu SC, Huang HY. Angiomatoid fibrous histiocytoma: clinicopathological and molecular characterisation with emphasis on variant histomorphology. *J Clin Pathol* 2014; 67: 210-15.
- [15] Schaefer IM, Fletcher CD. Myxoid variant of so-called angiomatoid “malignant fibrous histiocytoma”: clinicopathologic characterization in a series of 21 cases. *Am J Surg Pathol* 2014; 38: 816-23.
- [16] Hasegawa T, Seki K, Ono K, Hirohashi S. Angiomatoid (malignant) fibrous histiocytoma: a peculiar low-grade tumor showing immunophenotypic heterogeneity and ultrastructural variations. *Pathol Int.* 2000; 50(9):731–738.
- [17] Chow LT, Allen PW, Kumta SM, Griffith J, Li CK, Leung PC. Angiomatoid malignant fibrous histiocytoma: report of an unusual case with highly aggressive clinical course. *J Foot Ankle Surg.* 1998 May-Jun; 37(3): 235-238.
- [18] Fletcher CDM, ed. *Diagnostic Histopathology of Tumors.* 1<sup>st</sup> ed. New York, NY: Churchill Livingstone; 1995:24.
- [19] Costa MA, Silva I, Carvalhido L, et al. Angiomatoid fibrous histiocytoma of the arm treated by radiotherapy for local recurrence—case report. *Med Pediatr Oncol.* 1997 May; 28(5):373-376.