

A clinical study of Thalamic gliomas and its treatment modalities

Bhagwati Salgotra* and Kunal Kishore

Department of Neurosurgery, SBKS Medical College, Sumandeep Vidyapeeth, Vadodara, India

*Correspondence Info:

Dr. Bhagwati Salgotra
Assistant Professor,
Department of Neurosurgery,
SBKS Medical College, Sumandeep Vidyapeeth, Vadodara, India
E-mail: drsalgotra@gmail.com

Abstract

Background: Thalamic gliomas are one of the challenging tumors to manage. Retrospective study of 11 cases of thalamic glioma including adult and pediatric patient treated over the period of 2 years (from October 2013 to July 2015) was done at our institute.

Aims and Objective: To study clinical feature and treatment modality of thalamic glioma.

Materials and method: Retrospective analysis of 11 patients diagnosed with thalamic glioma by imaging and stereotactic biopsy was done. Patients presenting with hydrocephalus underwent ventriculo peritoneal shunting.

Results: 11 patients were diagnosed with thalamic glioma, Pilocytic Astrocytoma 6 (54.54%), Fibrillary astrocytoma 4 (36.36%), Glioblastoma multiformae 1 case (9.09%). 10 patients underwent stereotactic biopsy and in 3 patients v.p shunting was done.

Conclusion: Thalamic gliomas can be diagnosed accurately with MRI and MRS. Stereotactic biopsy of thalamic glioma involves lesser morbidity and gives tissue diagnosis. Combined approach of treatment including surgery, radiotherapy is used to improve survival.

Keywords: Thalamic glioma, stereotactic biopsy, low grade glioma of thalamus

1. Introduction

Thalamus is a large ovoid mass of gray matter that forms the major part of diencephalon. It is situated at the rostral end of brain stem on each side of third ventricle. Though it constitutes less than 2% of neuraxis, it is a region of great functional importance and serves as a cell station to all the main sensory system (except olfactory pathway). Thalamic and brain stem tumors constitute 10-15% of primary intracranial gliomas of childhood [1,2], with a dominant age being 4-14 years. Adult thalamic and brain stem tumors constitute 35%. [3] Due to their critical location, thalamic tumors often require treatment without biopsy confirmation. However, autopsy results and more recently stereotactic biopsy have revealed that the majority of the tumors are glial neoplasms.[4] The treatment of intrinsic brain stem and thalamic tumors often results in poor outcome.[5-7]

Aims and Objectives:

1. To study Clinical and radiological features of thalamic glioma.
2. To study the treatment modality in individual patients.

3. The aim of this study was to determine whether clinical and neuroimaging features could guide treatment.

2. Materials and Methods

2.1 Material

Study area: Dhiraj hospital, Sumandeep vidyapeeth.
Study population: Patients attending OPD and admitting in Dhiraj Hospital wards.

Study period: 2yrs (from October 2013 to July 2015)

Sample size: All diagnosed case of thalamic tumours and being admitted to Dhiraj Hospital.

Sample design: To study patients of thalamic tumours. Inclusion criteria: All histopathologically proven glial tumors of thalamus.

Exclusion criteria: Thalamic tumors not proven histopathologically as glial tumors (like metastasis, granuloma) & also bilateral thalamic tumors as they are distinct entities.

Study design: Non randomized study. (Prospective study)

2.2 Methods

Parameters to be studied

To study in detail the patient in terms of symptoms and signs. To study the radiological features.

- i. To study treatment modality.
- ii. To follow up the patients.

Study tools:

Clinical: History taking and clinical examination
 Investigation: Routine haematological, Biochemical
 Chest X-ray PA view, ECG, serology Coagulation profile (PT, APTT) , CT Scan brain (Plain + Contrast), MRI Scan brain (Plain + Contrast)

Study Techniques: This was a prospective study among the members of the study population. Analysis will be explained in the form of percentage and by extrapolating. We can compare it with the present scenario as depicted in various texts, journals etc. Patients will be investigated clinically, radiologically and will be operated at Dhiraj operation theatre by stereotactic approach under general anesthesia. Tumor tissue was excised and preserved in formol saline. Then paraffin embedding will be done and the prepared slides stained with Haematoxylin and Eosin. They will be analyzed microscopically for histopathology. Post-operatively, the patients will undergo outcome evaluation in terms of clinical& radiological parameters. Post-operatively patients were sent for radiotherapy and chemotherapy

3. Results

In our study 11 cases were treated of thalamic gliomas. In which 6 patients were of 0- 15 yrs, 2 patients were 15-25 yrs patients 3 patients were more than 25 years old.

Table 1: Patient Selection

Age range (years)	No of patients	Percentage
0-15	6	54.54%
15-25	2	18.18%
>25	3	27.27%

Clinical symptoms include headache, nausea, drowsiness rarely epilepsy, behavioural disturbances such as confusion, disorientation, aggressiveness, apathy. 1 patient had hemiparesis. 3 patients had hydrocephalus. All patients underwent MRI (Plain+contrast) + MR spectroscopy. According to radiological findings thalamic gliomas were diagnosed. MR Spectroscopy showed creatinine peak in all patient. 1 patient showed irregular ring enhancing lesion in contrast. Stereotactic biopsy was done in 10 patients along with V.P shunting in 3 patients. All patients were sent for radiotherapy and chemotherapy after confirmation of tissue diagnosis. 1 patient had clear findings of glioblastoma multiformae

(GBM) in radiology. These patients were sent directly for radiotherapy+ chemotherapy. Histology showed 6 patients of pilocytic astrocytoma, 4 patients had fibrillary astrocytoma and 1 patient was diagnosed as GBM.

Table 2: Number of Patients

Histology of thalamic gliomas	Number of patients	percentage
Pilocytic Astrocytoma	6	54.54%
Fibrillary astrocytoma	4	36.36%
Glioblastoma multiformae	1	9.09%

Figure 1: Right Thalamic glioma MRI T2 image

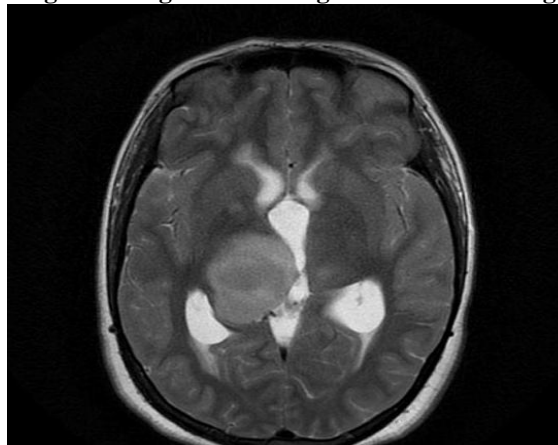


Figure 2: Right thalamic glioma MRI T1 image

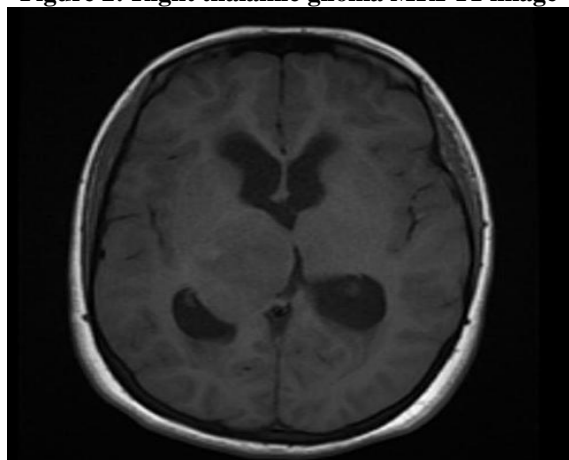


Figure 3: Right thalamic glioma MRI FLAIR image

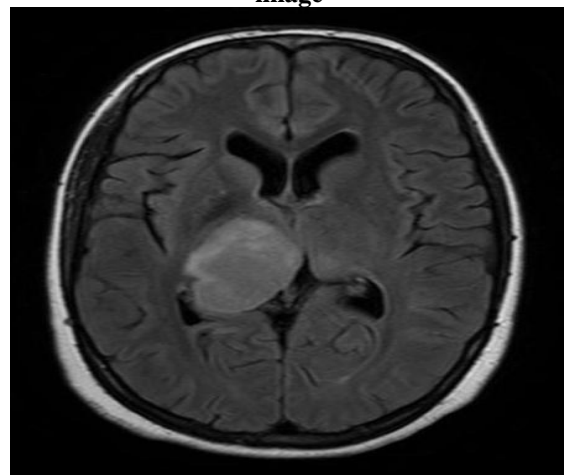
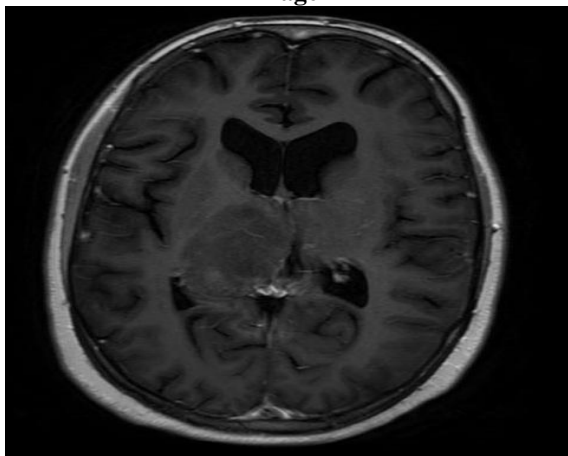
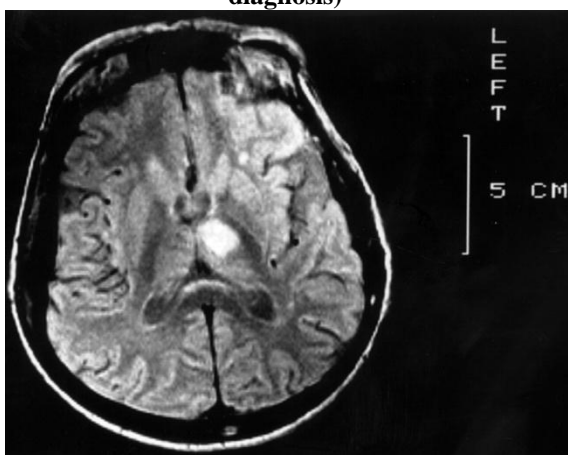
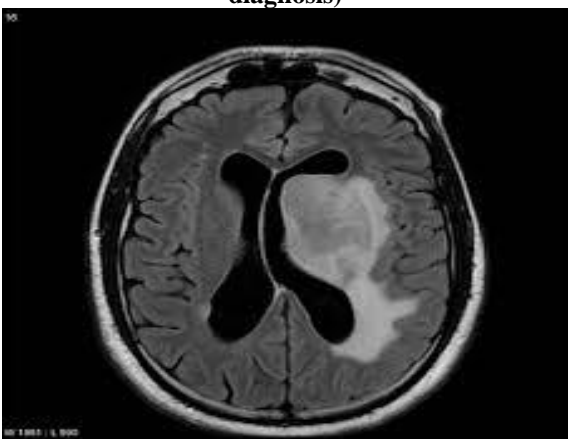

Figure 4: Right thalamic glioma MRI T1 contrast image**Figure 5: Left Thalamic infarct (Differential diagnosis)****Figure 6: Left Thalamic lymphoma (Differential diagnosis)**

which purely thalamic tumors in children are addressed, the cases are often confined to one histological group, usually astrocytic tumors.[4,8,18]

A clear anatomical picture of these deeply seated lesions is now possible because of the recent improvements in imaging modalities. Although these advances make more aggressive surgery technically feasible, it is uncertain which children might benefit from a more radical surgical procedure.[4] In most pediatric tumors the interpretation of the clinical and neuroimaging features observed at presentation predicts the likely pathological findings and outcome. Unfortunately, the histological features of tumors in this region are diverse; hence a wide variation in clinical behavior and outcome is experienced. Questions remain whether surgery is necessary, feasible, or even safe in these children.

Thalamic tumors in pediatric patients are generally astrocytic, and more than half are benign. In patients with unithalamic tumors, a short duration of symptoms, large tumors, incomplete resection, and high-grade histological type are all poor prognostic factors. There were no specific imaging features that were predictive of the histological type. Neuroimaging could be used to determine resectability, however, particularly in well-defined lesions with no extension into adjacent structures. Total or subtotal resection is the goal; this extent of resection is associated with improved overall survival and can be achieved with minimal occurrences of morbidity and mortality. Tumors that are not safe to resect should be investigated using biopsy sampling to exclude nonneoplastic pathological entities and to direct future adjuvant therapies based on histological tumor types. Radiotherapy and chemotherapy should be reserved for patients with malignant lesions or tumor progression. Adjuvant therapies should not be considered without a histological diagnosis.

There are two subgroups of thalamic tumors. The first includes the thalamopeduncular tumors, which are generally benign pilocytic astrocytomas. These can be macroscopically excised and potentially have a good prognosis. The second subgroup includes the bithalamic tumors, which are often low-grade astrocytomas. Following biopsy sampling to confirm the histological type, these lesions can be observed expectantly, with more than half of the patients with tumors in this subgroup attaining a long-term survival.

Resection of deep-seated tumors such as those arising from the thalamus remains a neurosurgical challenge.[4] With stereotactic techniques, some well-circumscribed lesions such as [21] juvenile pilocytic astrocytomas (JPAs) can be completely and safely removed from the thalamus in children.[11,13,19,21] Juvenile pilocytic astrocytomas

4. Discussion

Up to 5% of pediatric intracranial tumors occur in the thalamic region [8,9] The management regimen for children with tumors in this region is not clear-cut. The existing literature is sparse and difficult to interpret because many series combine both adult and pediatric populations [10,11], or they include tumors arising in the basal ganglia and other diencephalic structures.[12-17] In the few series in

in particular are well suited for stereotactic resection because the contrast-enhancing margins on MR images correspond to histologically and surgically identifiable normal brain–tumor interface. Although a variety of operative trajectories exist for resection of thalamic tumors, careful identification of the normal thalamus, internal capsule, and tumor extension into adjacent structures is paramount for planning the optimal surgical strategy. This is particularly challenging in very large tumors that distort normal anatomy and obscure the location of the PLIC and the motor fibers therein.

Complete resection of JPAs leads to long-term disease-free survival in the majority of patients and is currently unmatched by other treatments.[21-24] Chemotherapy[16,25-27], conventional radiation therapy[29-31], and stereotactic radiosurgery [32,33], may play a role for multiply recurrent tumors or residual disease; however, none of these options is superior to complete resection. Furthermore, the potential long-term adverse effects of such therapies raise important concerns in young children.

Patients with thalamic glioma which are associated with hydrocephalus may require CSF diversion in form of VP Shunt before definite surgery. The symptoms due to increase ICP gets improve following VP shunt. [34]

The management of thalamic gliomas is extremely variable, ranging from radical excision in some cases to more conservative therapy such as a biopsy and radiation. There is a high incidence of associated hydrocephalus. The principles of management are, therefore, histological diagnosis, CSF diversion and adjuvant therapy. Endoscopy appears to offer a new approach to achieve histology and CSF diversion. [35]

Tumor histology has been reported to affect survival in both pediatric and adult patients.

5. Conclusion

Thalamic gliomas can be diagnosed accurately with radiological modalities. Spectroscopy further helps in confirming the diagnosis. Common clinical symptoms are that of raised intracranial tension, behavioural changes, rare symptoms include hemiparesis and seizures. Stereotactic removal /biopsy of tumor can be done which involves lesser morbidity and gives tissue diagnosis. Combined approach of treatment including surgery, radiotherapy and chemotherapy is used to improve survival.

References

- [1] Cohen ME, Duffner PK. Brain tumors in children: Principles of diagnosis and treatment. Raven Press, New York. 1984; 156-172.
- [2] Littman P, Jarrett P, Bilaniuk LT *et al.* Pediatric brain stem gliomas. *Cancer*.1980; 45: 2787-2792.
- [3] Hirose G. Childhood Brain tumor consortiums of study of childhood brain tumors based on surgical biopsies from 10th North American Institution. *J Neuro Oncol*.1988; 6: 9-23.
- [4] Albright AL, Price RA, Guthkelch AN. Brain stem gliomas in children: A clinopathologic study. *Cancer*.1983; 82: 2313-2319.
- [5] Bergen MS, Edwards MSB, Lamasters D *et al.* Pediatric brain stem tumors: Radiographic pathologic and clinical correlation. *Neurosurgery*.1983; 12: 298-302.
- [6] Freeman CR, Swissa S. Brain stem tumors in children. *IJROBP*1986; 12: 1823-1828.
- [7] Panith HS, Berg BO. Brain stem tumors of childhood and adolescence. *Am J Dis Child* 1970; 119: 465-472.
- [8] Cuccia V, Monges J. Thalamic tumors in children. *Childs Nerv Syst*.1997; 13:514–521.
- [9] Reardon DA, Gajjar A, Sanford RA, Heideman RL, Walter AW, Thompson SJ, *et al.* Bithalamic involvement predicts poor outcome among children with thalamic glial tumors. *Pediatr Neurosurg*.1998; 29:29–35.
- [10] Arseni C: Tumors of the basal ganglia; their surgical treatment. *AMA Arch Neurol Psychiatry*.1958; 80:18–24.
- [11] Kelly PJ: Stereotactic biopsy and resection of thalamic astrocytomas. *Neurosurgery*. 1989; 25:185–195.
- [12] Krouwer HG, Prados MD. Infiltrative astrocytomas of the thalamus. *J Neurosurg*.1995; 82:548–557.
- [13] Lyons MK, Kelly PJ. Computer-assisted stereotactic biopsy and volumetric resection of thalamic pilocytic astrocytomas. Report of 23 cases. *Stereotact Funct Neurosurg*.1992; 59:100–104.
- [14] Martinez-Lage JF, Perez-Espejo MA, Esteban JA, Poza M. Thalamic tumors: clinical presentation. *Childs Nerv Syst*. 2002; 18: 405–411.
- [15] Matsumoto K, Higashi H, Tomita S, Furuta T, Ohmoto T. Resection of deep-seated gliomas using neuroimaging for stereotactic placement of guidance catheters. *Neurol Med Chir (Tokyo)*.1995; 35:148–155.
- [16] McGirr SJ, Kelly PJ, Scheithauer BW. Stereotactic resection of juvenile pilocytic astrocytomas of the thalamus and basal ganglia. *Neurosurgery*.1987; 20:447–452.
- [17] Mitchell AE, Elder JE, Mackey DA, Waters KD, Ashley DM. Visual improvement despite radiologically stable disease after treatment with

- carboplatin in children with progressive low-grade optic/thalamic gliomas. *J Pediatr Hematol Oncol.* 2001; 23: 572–577.
- [18] Drake JM, Joy M, Goldenberg A, Kreindler D. Computer and robot-assisted resection of thalamic astrocytomas in children. *Neurosurgery.* 1991; 29:27–33.
- [19] Kelly PJ. Resection of intraventricular tumors via a computer-assisted volumetric stereotactic approach. *Neurosurgery.* 1993; 33:771–772.
- [20] Moshel YA, Link MJ, Kelly PJ. Stereotactic volumetric resection of thalamic pilocytic astrocytomas. *Neurosurgery.* 2007; 61:66–75.
- [21] Berger MS, Deliganis AV, Dobbins J, Keles GE. The effect of extent of resection on recurrence in patients with low grade cerebral hemisphere gliomas. *Cancer.* 1994; 71:1784–1791.
- [22] Forsyth PA, Shaw EG, Scheithauer BW, O'Fallon JR, Layton DD Jr, Katzmann JA. Supratentorial pilocytic astrocytomas. A clinicopathologic, prognostic, and flow cytometric study of 51 patients. *Cancer.* 1993; 72:1335–1342.
- [23] Geissinger JD. Astrocytomas of the cerebellum in children. Long-term study. *Arch Neurol.* 1971; 24:125–135.
- [24] Gjerris F, Klinken L. Long-term prognosis in children with benign cerebellar astrocytoma. *J Neurosurg.* 1971; 49:179–184.
- [25] Mahoney DH Jr, Cohen ME, Friedman HS, Kepner JL, Gerner L, Langston JW, *et al.* Carboplatin is effective therapy for young children with progressive optic pathway tumors: a Pediatric Oncology Group phase II study. *Neuro Oncol.* 2000; 2:213–220.
- [26] Packer RJ, Sutton LN, Bilaniuk LT, Radcliffe J, Rosenstock JG, Siegel KR, *et al.* Treatment of chiasmatic/hypothalamic gliomas of childhood with chemotherapy: an update. *Ann Neurol.* 1988; 23:79–85.
- [27] Prados MD, Edwards MS, Rabbitt J, Lamborn K, Davis RL, Levin VA. Treatment of pediatric low-grade gliomas with a nitrosourea-based multiagent chemotherapy regimen. *J Neurooncol.* 1997; 32:235–241.
- [28] Fisher BJ, Bauman GS, Leighton CE, Stitt L, Cairncross JG, Macdonald DR. Low-grade gliomas in children: tumor volume response to radiation. *J Neurosurg.* 1998; 88: 969–974.
- [29] Friedman HS, Krischer JP, Burger P, Oakes WJ, Hockenberger B, Weiner MD, *et al.* Treatment of children with progressive or recurrent brain tumors with carboplatin or iproplatin: a Pediatric Oncology Group randomized phase II study. *J Clin Oncol.* 1992; 10:249–256.
- [30] Hadjipanayis CG, Kondziolka D, Flickinger JC, Lunsford LD. The role of stereotactic radiosurgery for low-grade astrocytomas. *Neurosurg Focus.* 2013; 14:5-15.
- [31] Somaza SC, Kondziolka D, Lunsford LD, Flickinger JC, Bissonette DJ, Albright AL. Early outcomes after stereotactic radiosurgery for growing pilocytic astrocytomas in children. *Pediatr Neurosurg.* 1996; 25:109–115.
- [32] Boethius J, Ulfarsson E, Rahn T, Lippitz B. Gamma knife radiosurgery for pilocytic astrocytomas. *J Neurosurg.* 2002; 97:677–680.
- [33] Goel A. Preoperative shunts in thalamic tumours. *Neurol India.* 2000; 48(4):347-50.
- [34] S. Selvapandian. Endoscopic Management of Thalamic Gliomas, *Thieme eJournals, Minim Invasive Neurosurg* 2006; 49(4): 194-196.